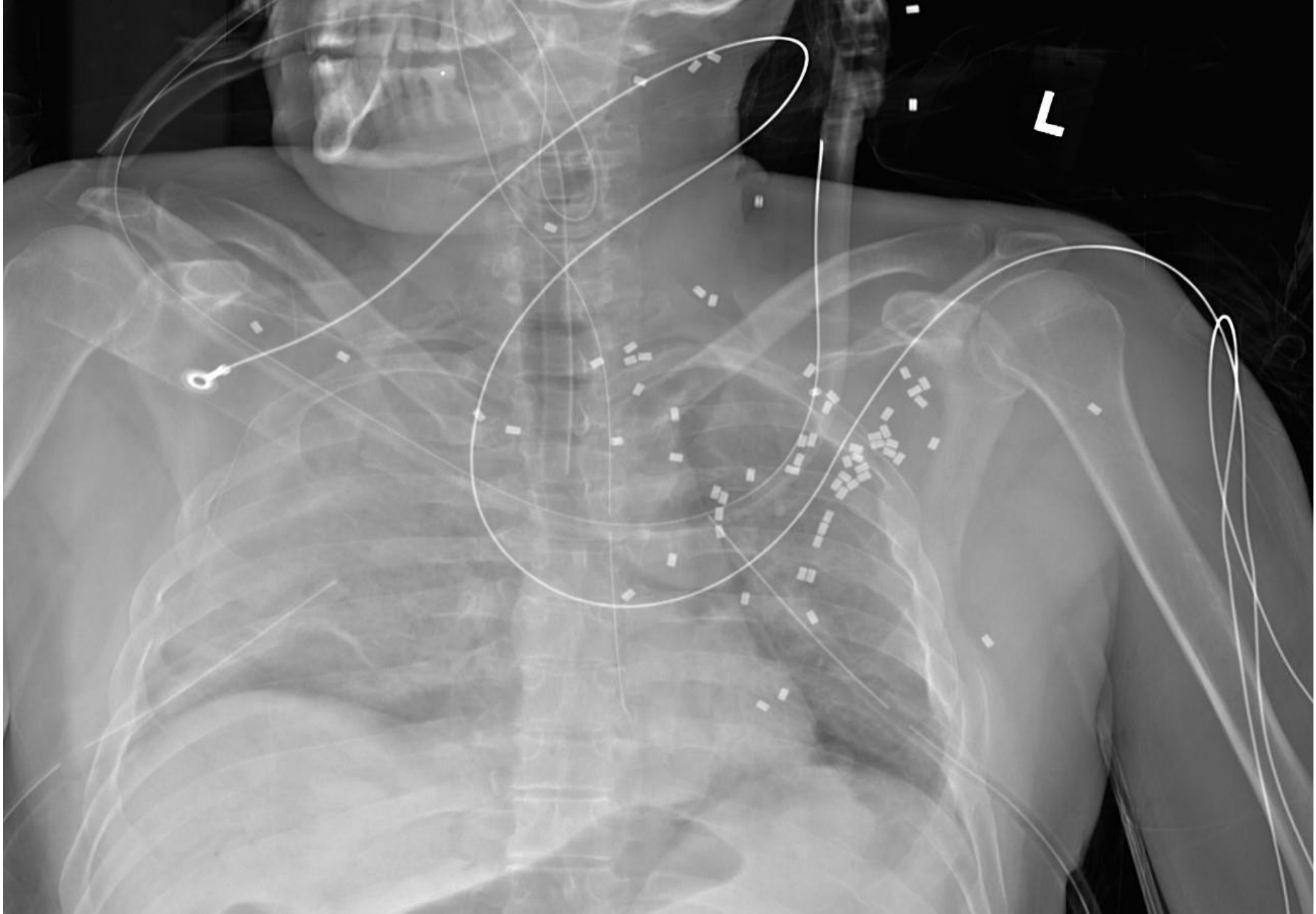


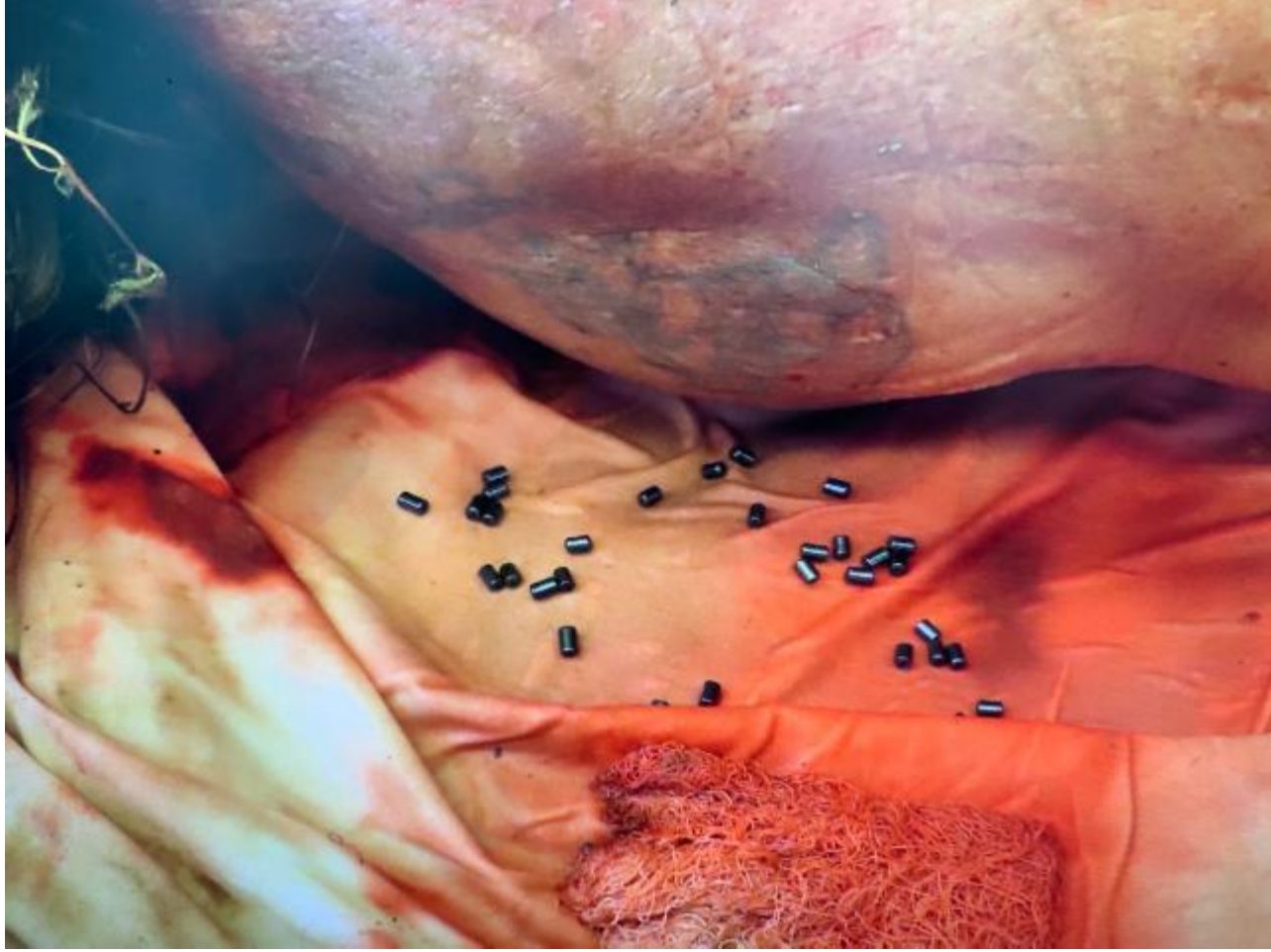# EAC Case #27

- The decedent is a 27-year-old shot during an altercation. What are the scattered small radiopaque objects in the postmortem image?

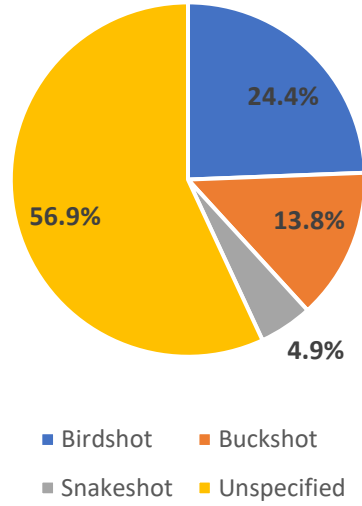


This question is not straight-forward, and in real life you would not be expected to know this simply based on the x-ray. The main point of this question is to remind everyone that bodies with firearm injuries (and sharp force injuries) should be imaged before all of the clothing is removed if possible. Projectiles can be trapped in clothing, hair, or chest tubes – or even loose in the body bag. But, there are other things that can be picked up in the bag and clothing as well.

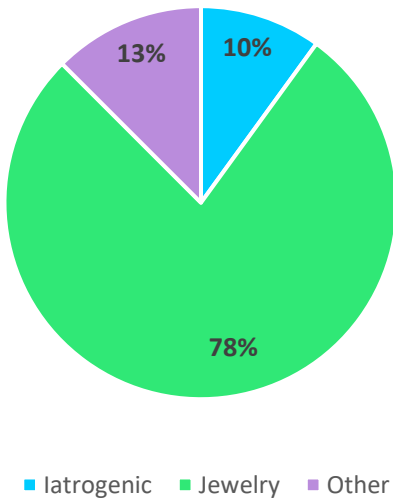
In this case, the objects on the x-ray were behind the body in the body bag (see next images) – and ended up being cylindrical beads from a broken necklace. Many people guessed shotgun ammunition. In particular, “Waterfowl Hex Steel Shot” was cited twice as a possible answer, and it is almost identical to the shape of the beads (see subsequent image).



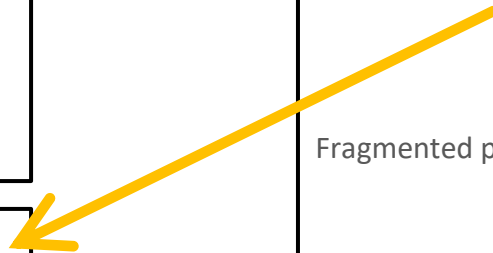
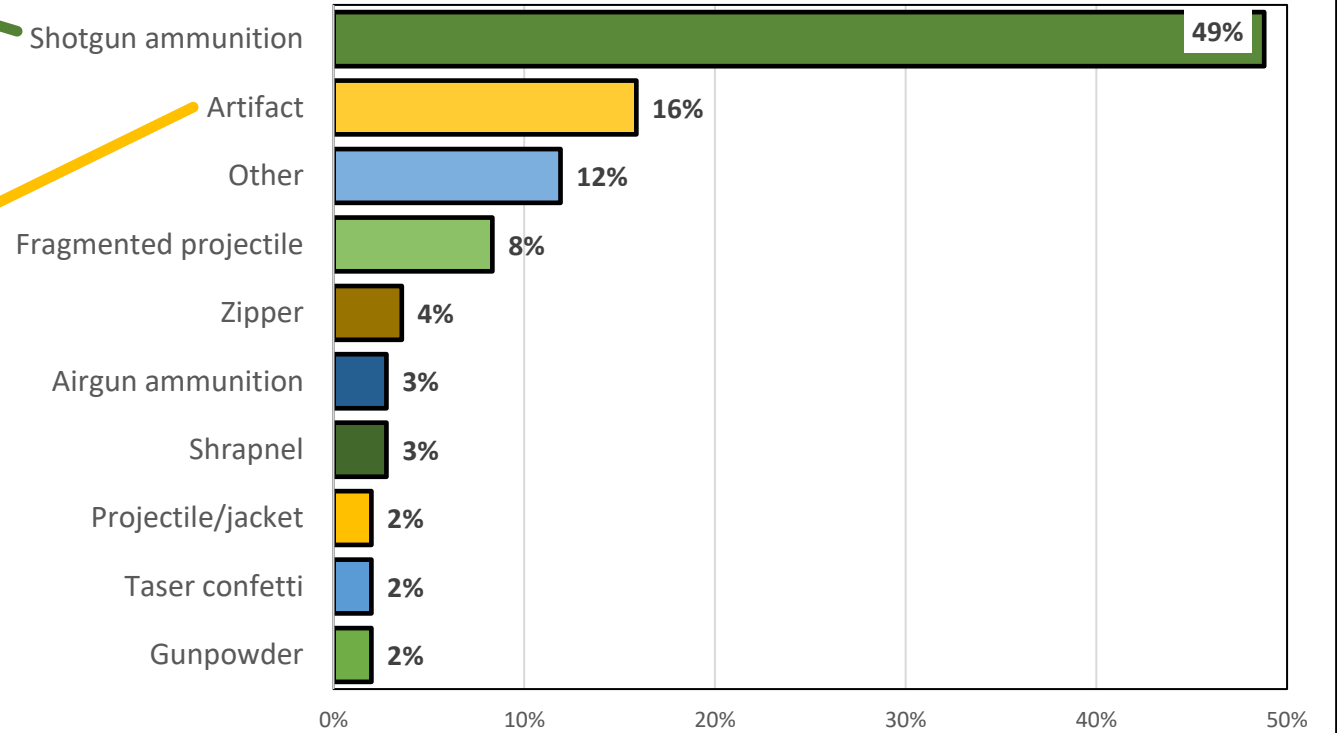
### Shotgun Subcatergeries



### Artifact Subcatergeries



### Answer Distribution by Category



# Word Cloud

Shrapnel jewelry shell broken jewelry fragments Buck shot Buckshot  
Shot gun pellets Birdshot zipper beads Metal  
Shotgun pellets projectile pellets Lead  
shotgun body shot Zipper teeth Bird shot Broken necklace  
necklace cylindrical bullet waterfowl Bullet fragments

# Waterfowl with Hex Steel Shot

