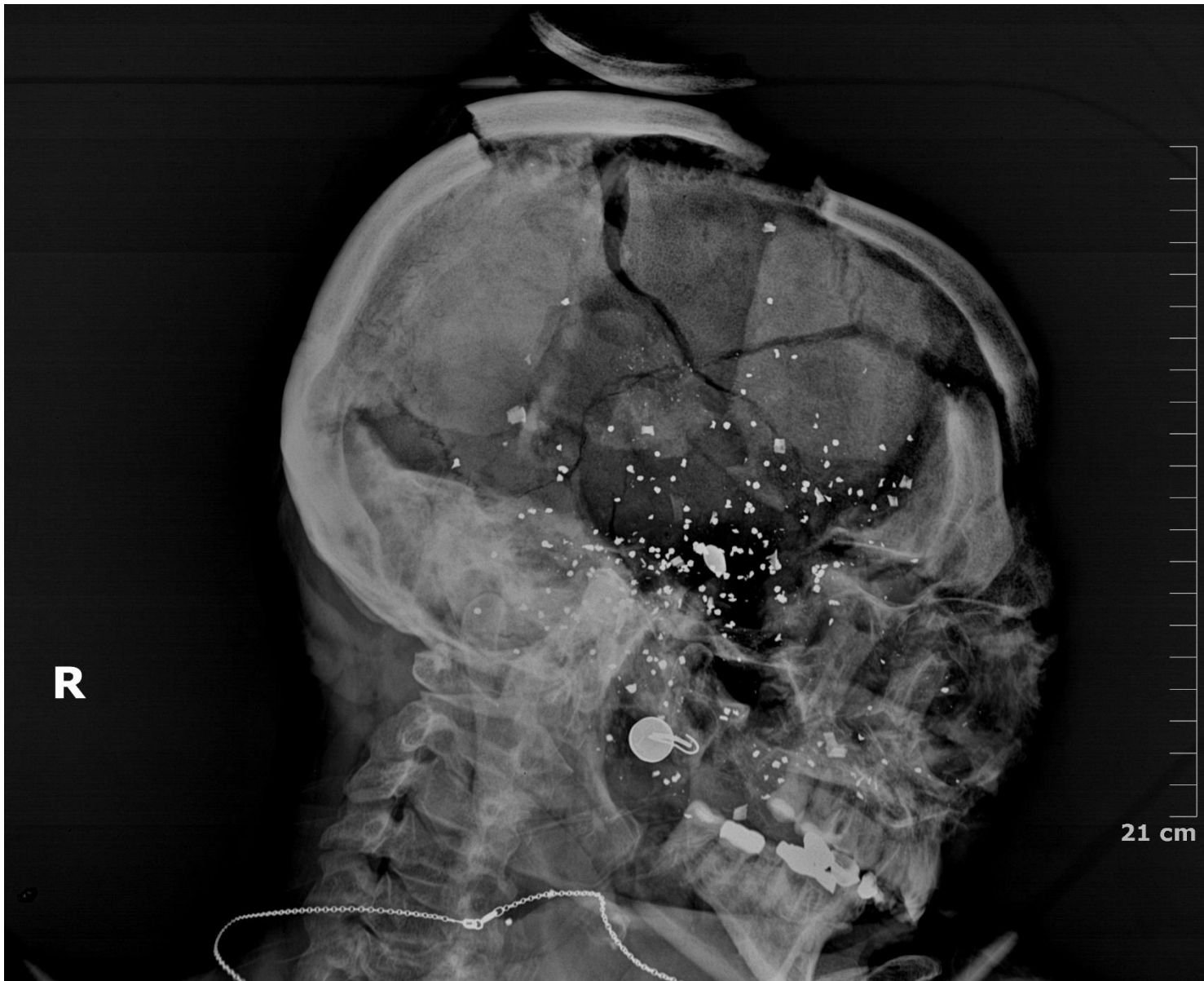



# Case #24

NAME Educational Activities Committee



Case courtesy of Dr. Vivian Snyder (EAC member, Alameda County)


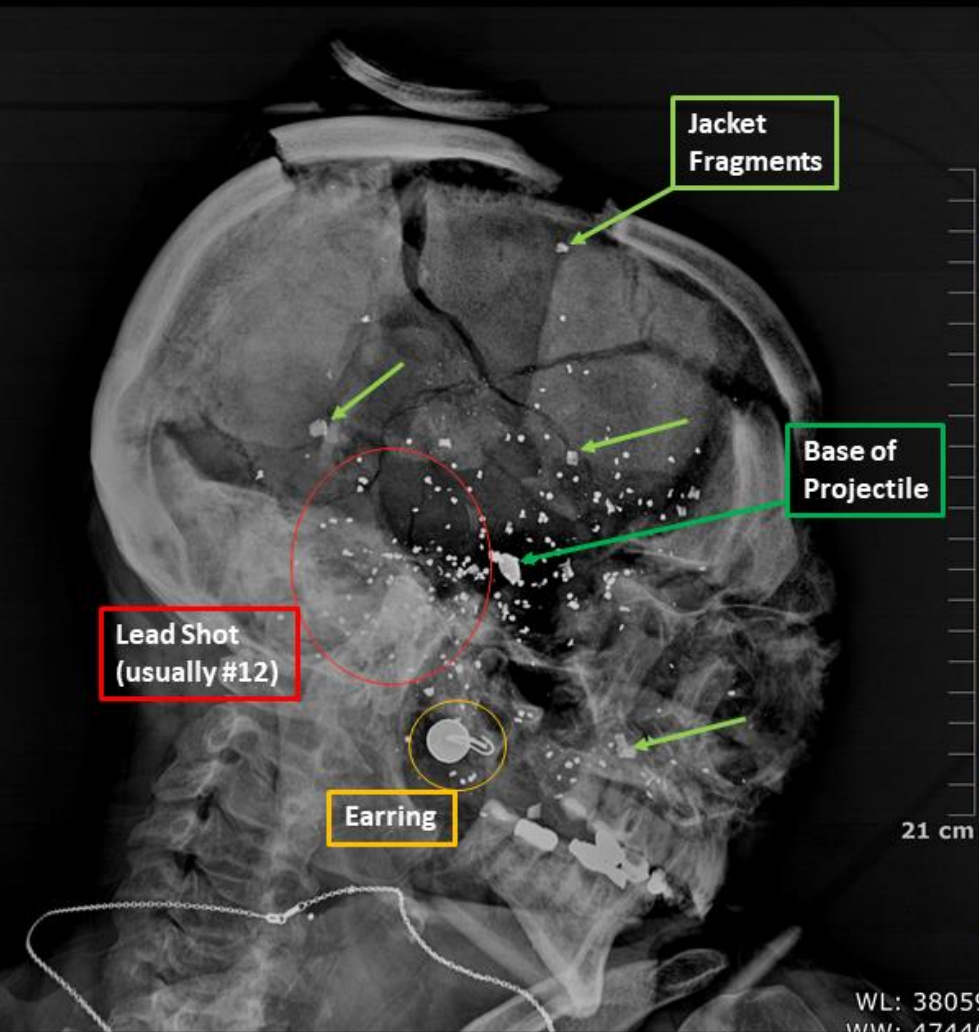
1. A 54-year-old female was found dead with a defect of the right temporal scalp and a handgun near her body.

The radiographic image is most consistent with which type of ammunition?

- .410 shotgun shell
- Snakeshot
- "Lead snowstorm" from high-velocity handgun ammunition
- Flechette round
- Glaser round



Bullets found at the scene



## Responses:

### A. .410 shot shell (14.08% responses)

.410 bore is one of the smallest caliber shotgun shells available, most significant for its capability of being fired from either a shotgun or select handguns, most popularly the Taurus Judge revolver. As with other shotgun ammunition, this ammunition consists of multiple lead pellets held within a plastic shot sleeve/cup and casing. Another unique feature of .410 gauge shot cups being that they peel back to produce 3 “petals” instead of the usual 4 seen with other shotgun shells. Depending on range of fire the plastic shot sleeve may follow the charge into the wound.

### B. Snake shot (20.66% responses)

Snake shot cartridges are smaller versions of shotgun cartridges designed to be fired using handguns. They contain multiple pellets within a brass casing, topped by a hollow plastic capsule. The plastic capsule shatters during firing, allowing shot to disperse after exiting the muzzle. This ammunition is generally used for shooting snakes, rodents and birds at very close range, and has very limited penetrating power. Despite generally having comparable size lead shot to Glaser rounds, injuries related to this ammunition have significantly less penetrating ability and would not contain jacket fragments.

### C. “Lead snowstorm” from high-velocity handgun ammunition (29.11% responses)

Rifle ammunition and some high-velocity handgun ammunition (e.g. .357 magnum rounds) are associated with one of the most characteristic X-ray findings in forensic pathology. The “lead snowstorm” is described as hundreds of small radiopaque bullet fragments scattered along a wound track. This results from fragmentation of the lead core of the bullet as it moves through the body. The majority of the fragments visualized on X-ray have a fine “dust-like” quality. Fragments/pellets seen on Glaser rounds are generally larger, coarser, and fewer in number than those seen in a “lead snowstorm”.

#### D. Flechette round (2.58% responses)

A flechette is a small arrow/dart-shaped projectile with a metal tail fin. Also known as “Satan’s Toothpicks,” these steel darts are notorious for their deep penetrating abilities. 12-Gauge shotgun shells loaded with flechettes have historically been used primarily in the military. In these shells, 20-25 flechettes are packed in a plastic cup with granulated white polyethylene to maintain alignment and improve flight trajectory.

#### E. Glaser Round ([CORRECT ANSWER, 33.57% of responses](#)):

The Glaser Safety Slug was designed in the 1970’s in an attempt to address concerns for overpenetration and ricochets when shooting in close quarters, especially for self-defense. It is a hollow point ammunition with a core of compressed #12 lead shot, capped with a polymer ball (a lot of times colored bright blue) and housed within a traditional copper jacket. Upon penetrating the target, the lead pellets within the Glaser bullet force the plug out and emerge from the jacket in a fan-like manner comparable to a shotgun effect. Because of its unique anatomy, Glaser rounds are readily recognizable on imaging by the presence of both fragmented jacketing and pellets, as is demonstrated in our case. See our attached images of the ammunition found at the scene and projectile fragments recovered during autopsy.

## References:

1. Vincent J. M. DiMaio M. D. Gunshot Wounds: Practical Aspects Of Firearms, Ballistics, And Forensic Techniques, second edition. CRC Press; 1998.
2. Dolinak D, Matshes E, Lew E. Forensic Pathology. Amsterdam: Elsevier/Academic Press; 2012.
3. Jones A, Reyna M, Sperry K, Hock D. Suicidal Contact Gunshot Wounds to the Head with .38 Special Glaser Safety Slug Ammunition. J Forensic Sci. 1987;32(6):11220J. doi:10.1520/jfs11220j.
4. The Taurus Judge: .45 Colt/.410 Shotshell Defender. Usconcealedcarrycom. 2021. Available at: <https://www.usconcealedcarry.com/blog/taurus-judge-45-colt-410-shotshell-defender/>.
5. Creighton K. How Effective is Snake Shot. AmmoMan. 2021. Available at: <https://www.ammoman.com/blog/how-effective-is-snake-shot/>.
6. 9mm Luger +P 80gr Glaser Blue. Shopcorboncom. 2021. Available at: [https://shopcorbon.com/index.php?route=product/product&product\\_id=111](https://shopcorbon.com/index.php?route=product/product&product_id=111).