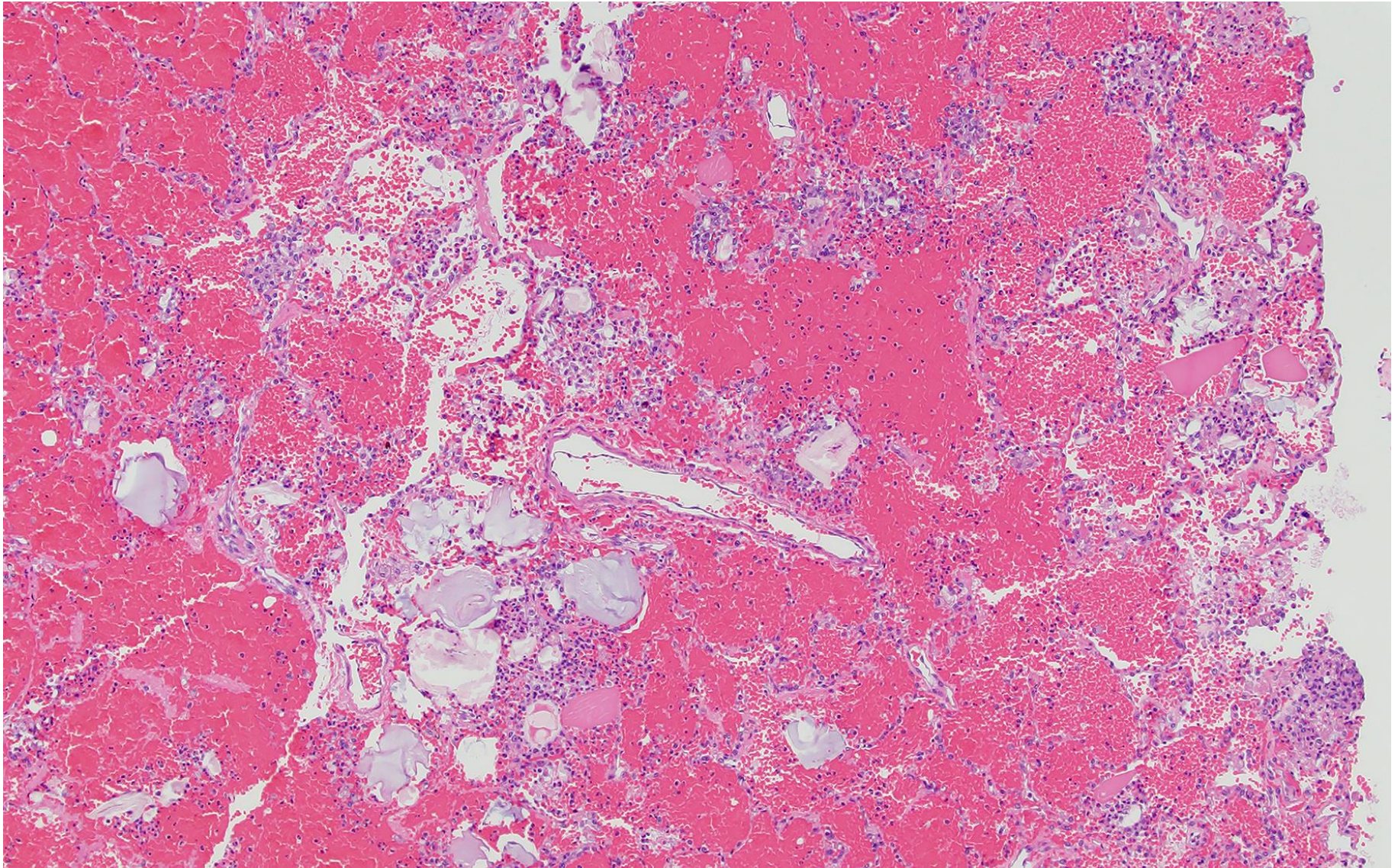


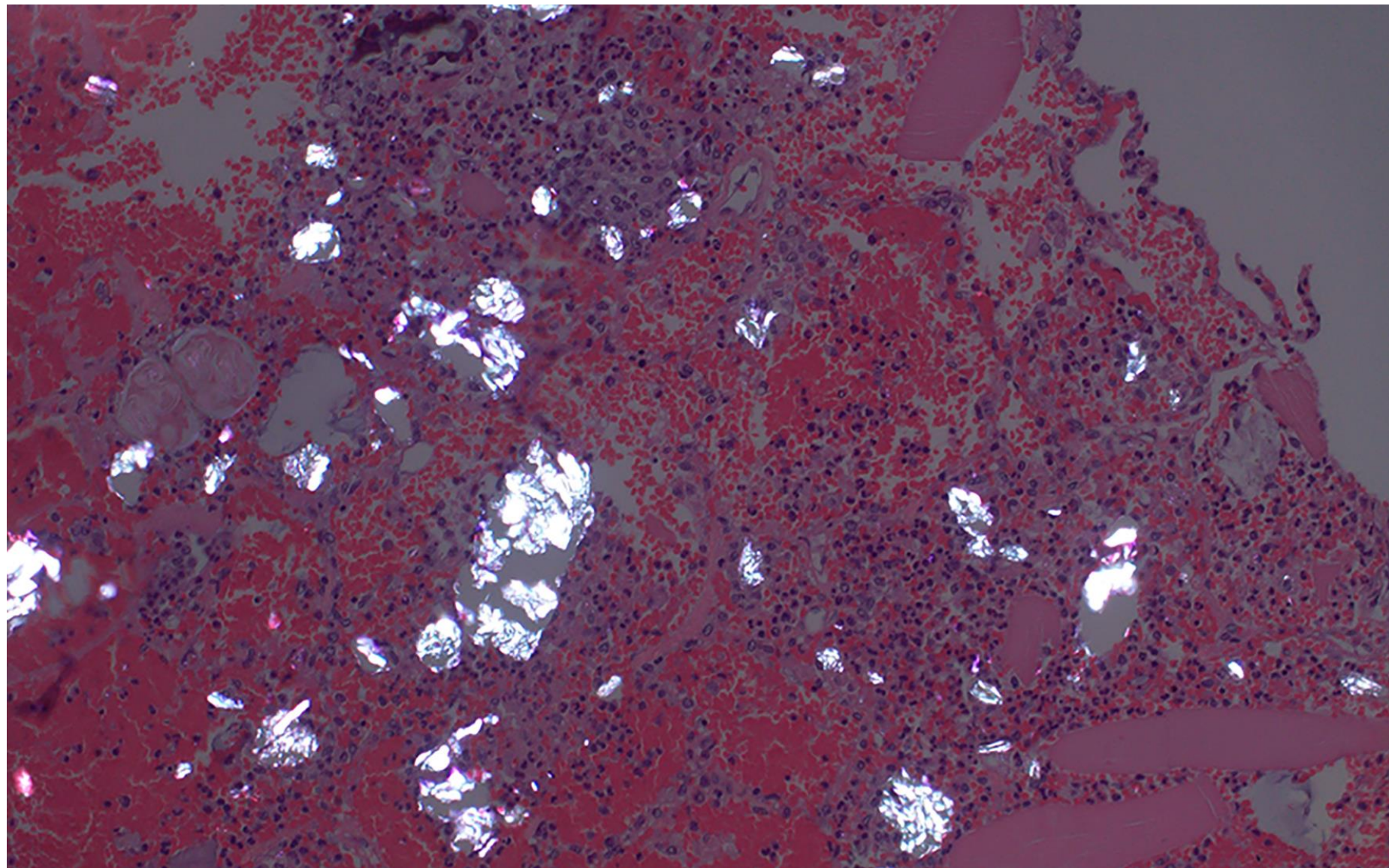


# Case #23

NAME Educational Activities Committee



Case courtesy of Dr. Fabiola Righi (Mayo Clinic, Rochester MN)



1. The decedent is a 15-year-old female with a history of depression and anxiety who presented to the Emergency Department after a suicide attempt. The images above show findings identified on histologic examination of the lungs.

What do these findings most likely indicate?

- Aspiration of crushed oral tablets
- Intravenous injection of crushed oral tablets
- Exposure to crystalline fragments of plexiglass (Methyl methacrylate)
- Parasitic infection and sequelae
- Vaping-related lung injury

Responses:

A. Aspiration of crushed oral tablets ([CORRECT ANSWER, 58.3% of responses](#))

The decedent in this case presented to the Emergency Department with nausea and vomiting, multiple hours after a polysubstance ingestion. During hospitalization her condition deteriorated, and she died after several days. Histology of the lungs shows polarizable pill material, vegetable material and muscle fragments within the airways. This is most consistent with aspiration of emesis containing crushed pill fragments. Upon chart review there is documentation of multiple instances of vomiting with emesis containing pill fragments during the decedent's hospitalization.

Oral tablets contain excipients, which are insoluble particulate filler materials that bind and protect the active drug during production, as well as shape and lubricate the tablet for easy swallowing. Excipients include talc (hydrated magnesium silicate), microcrystalline cellulose, crospovidone and starch. When crushed tablets are aspirated, particles of excipients can show up as birefringent foreign bodies within the lung airways.

B. Intravenous injection of crushed oral tablets (21.52% responses)

Following a similar process, when oral tablets are crushed, and injected intravenously, particles of excipients can show up as birefringent foreign bodies within pulmonary arteries and periarterial interstitium. This triggers pulmonary foreign body angiogranulomatosis, which over months and years of continued use, can lead to progressive pulmonary fibrosis. Some excipient crystals are fine enough to pass through capillaries to pulmonary veins, and lodge in the retina, spleen, liver, kidneys, lymph nodes, bone marrow, and spinal cord when intravenously injected.

C. Exposure to crystalline fragments of plexiglass (methyl methacrylate) (10.76% responses)

Methyl methacrylate (MMA) is a monomer widely used in medicine and industry. The most important exposure route of MMA is by inhalation. Prolonged exposure has been shown to result in marked pathologic changes in the lungs, including edema, hemorrhage, and necrosis. Furthermore, it may cause a wide range of widespread adverse health effects such as irritation of the skin, eyes, and mucous membranes, allergic dermatitis, stomatitis, asthma, neuropathy, and liver toxicity.

D. Parasitic infection and sequalae (0.45% responses)

Parasitic pulmonary infections may be caused by a variety of organisms, most commonly protozoa or helminths (worms). Parasitic infections can cause a variety of histopathologic patterns in the lung, including eosinophilic lung disease, granulomatous inflammation, vasculitis, pleuritis, empyema, and acute lung injury patterns. Some trematode egg walls (Ex. *Paragonimus* sp.) are strongly birefringent. In these cases distinct identifying anatomy such as spines and shouldered operculum would be seen, unlike our case, which shows amorphous birefringent deposits.

E. Vaping-related lung injury (8.97% responses)

Vaping-related histologic findings are generally nonspecific and require a clinical correlation. These findings include patterns of acute lung injury, including acute fibrinous pneumonitis, diffuse alveolar damage, or organizing pneumonia. Foamy macrophages and pneumocyte vacuolization are also common. In a few cases foreign body reaction to nonbirefringent material, presumed to be glycerin-based oils, found in droplets from e-cigarette vapor, have been described.

## References:

1. Aydin O, Attila G, Dogan A, Aydin M, Canacankatan N, Kanik A. The Effects of Methyl Methacrylate on Nasal Cavity, Lung, and Antioxidant System (An Experimental Inhalation Study). *Toxicol Pathol.* 2002;30(3):350-356. doi:10.1080/01926230252929927.
2. Boland JM, Pritt BS. Histopathology of Parasitic Infections of the Lung. *Seminars in Diagnostic Pathology.* 2017;34(6):550-559.
3. Butt Y, Smith M, Tazelaar H et al. Pathology of Vaping-Associated Lung Injury. *New England Journal of Medicine.* 2019;381(18):1780-1781. doi:10.1056/nejmc1913069.
4. Hoyt B, Aaron D, Yan S, Linos K. Cutaneous Crospovidone: A Newly Described Foreign Body Due to Illicit Drug Abuse. *Am J Dermatopathol.* 2019;41(8):e84-e86. doi:10.1097/dad.0000000000001374.
5. Mukhopadhyay S, Katzenstein A. Pulmonary Disease due to Aspiration of Food and Other Particulate Matter: A Clinicopathologic Study of 59 Cases Diagnosed on Biopsy or Resection Specimens. *American Journal of Surgical Pathology.* 2007;31(5):752-759. doi:10.1097/01.pas.0000213418.08009.f9.
6. Nguyen V, Chan E, Chou S et al. Pulmonary Effects of IV Injection of Crushed Oral Tablets: “Excipient Lung Disease”. *American Journal of Roentgenology.* 2014;203(5):W506-W515. doi:10.2214/ajr.14.12582.
7. Ring Madsen L, Vinther Krarup NH, Bergmann TK, et al. A Cancer That Went Up in Smoke: Pulmonary Reaction to e-Cigarettes Imitating Metastatic Cancer. *Chest.* 2016;149(3):e65