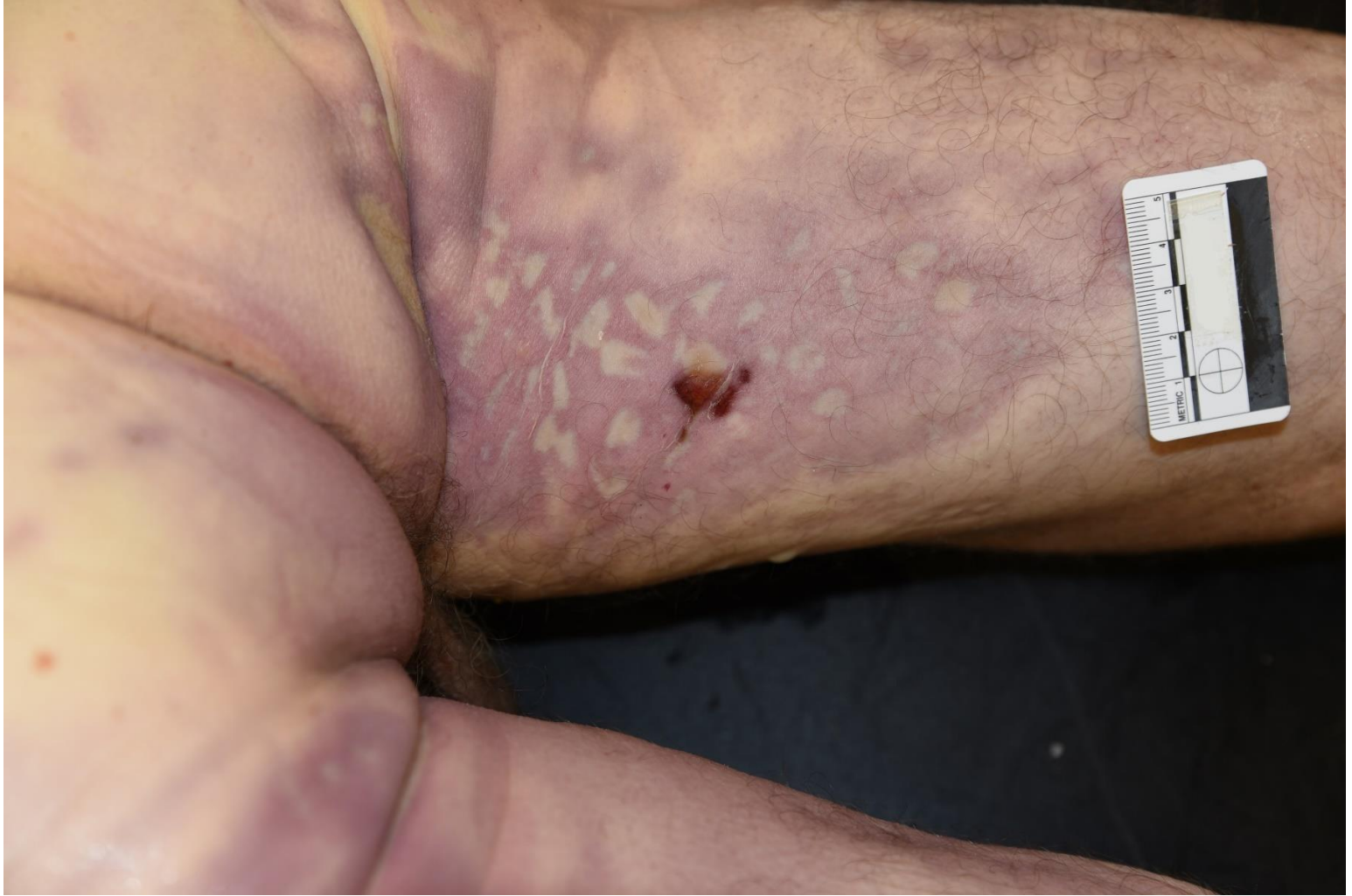



Case #14

NAME Educational Activities Committee



Free Text Question:

A 38-year-old man was found unresponsive on a farm.

What is the most likely cause of this lividity pattern on his posterior thigh?

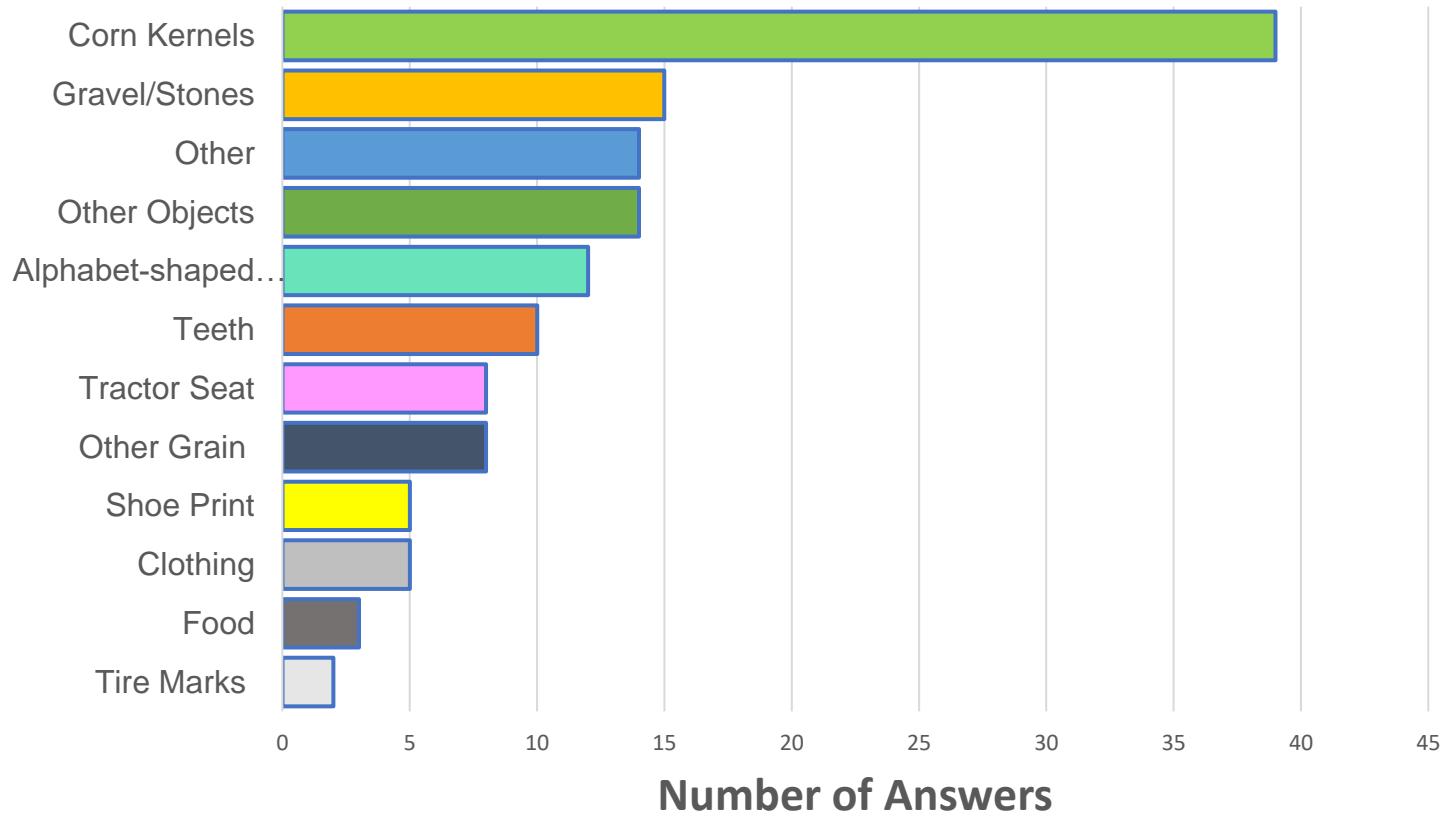
Answer...

The decedent was last known alive while at work at a feed and grain facility. His co-workers noticed him missing and found him inside a grain bin filled with 10 ft of corn. He was described to have been entrapped in the grain up to his neck, with only his head visible at the surface of the corn. The lividity observed at autopsy is due to pressure from the individual corn kernels surrounding him. Pressure imprints from the kernels were also seen on his torso at the scene. There was congestion seen at the base of neck and multiple areas of petechiae throughout the body.

The cause of death was determined to be mechanical asphyxia due to grain entrapment.

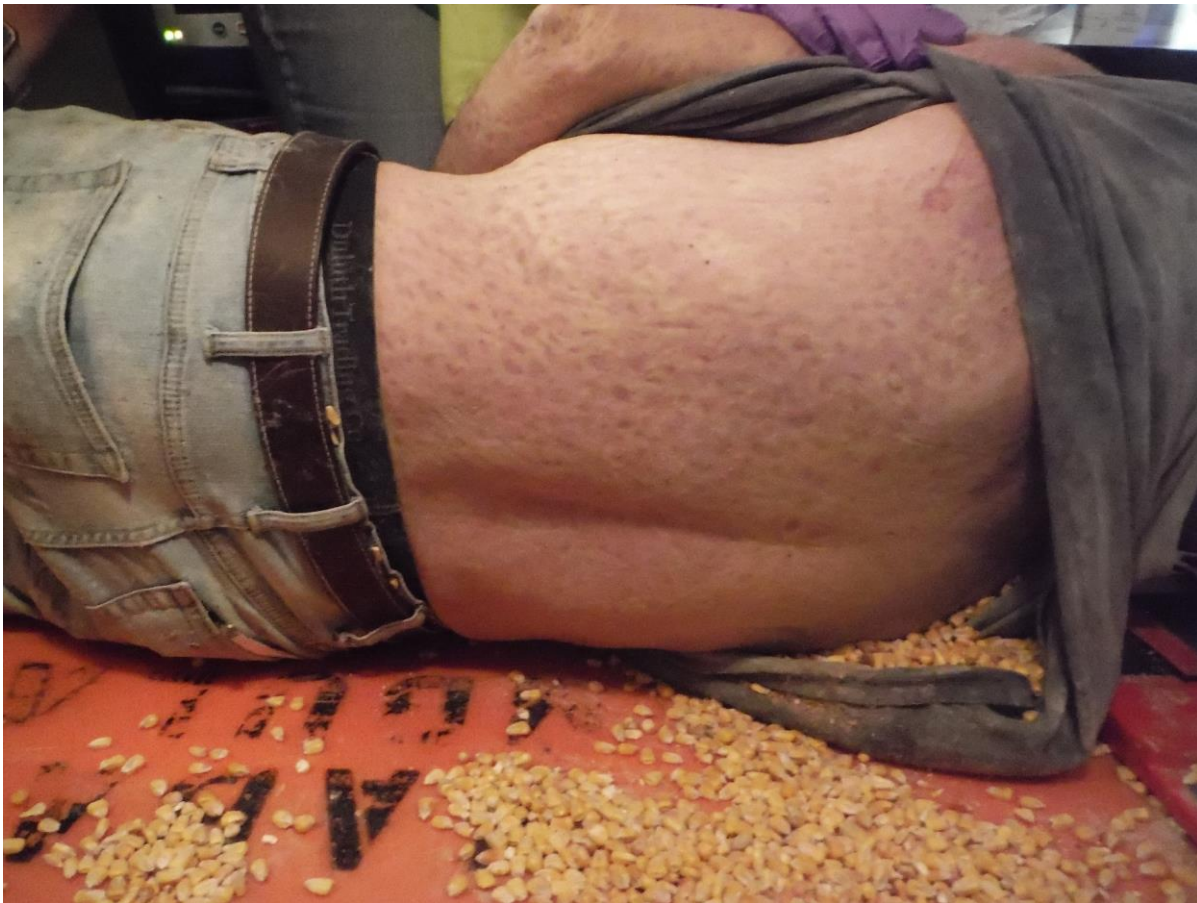grain something alphabet feed sitting small patterned material
teeth pebbles corn kernels Dried corn Corn
animal feed gravel looks Tractor seat surface laying
objects bag shoe lying magnets letters

Answer Choices by Category



Entrance of grain bin where decedent was located (after extrication).





Corn kernel imprints on the decedent's back at the scene