



Case #4

NAME Educational Activities Committee

Photo courtesy of Patrick Hansma, DO

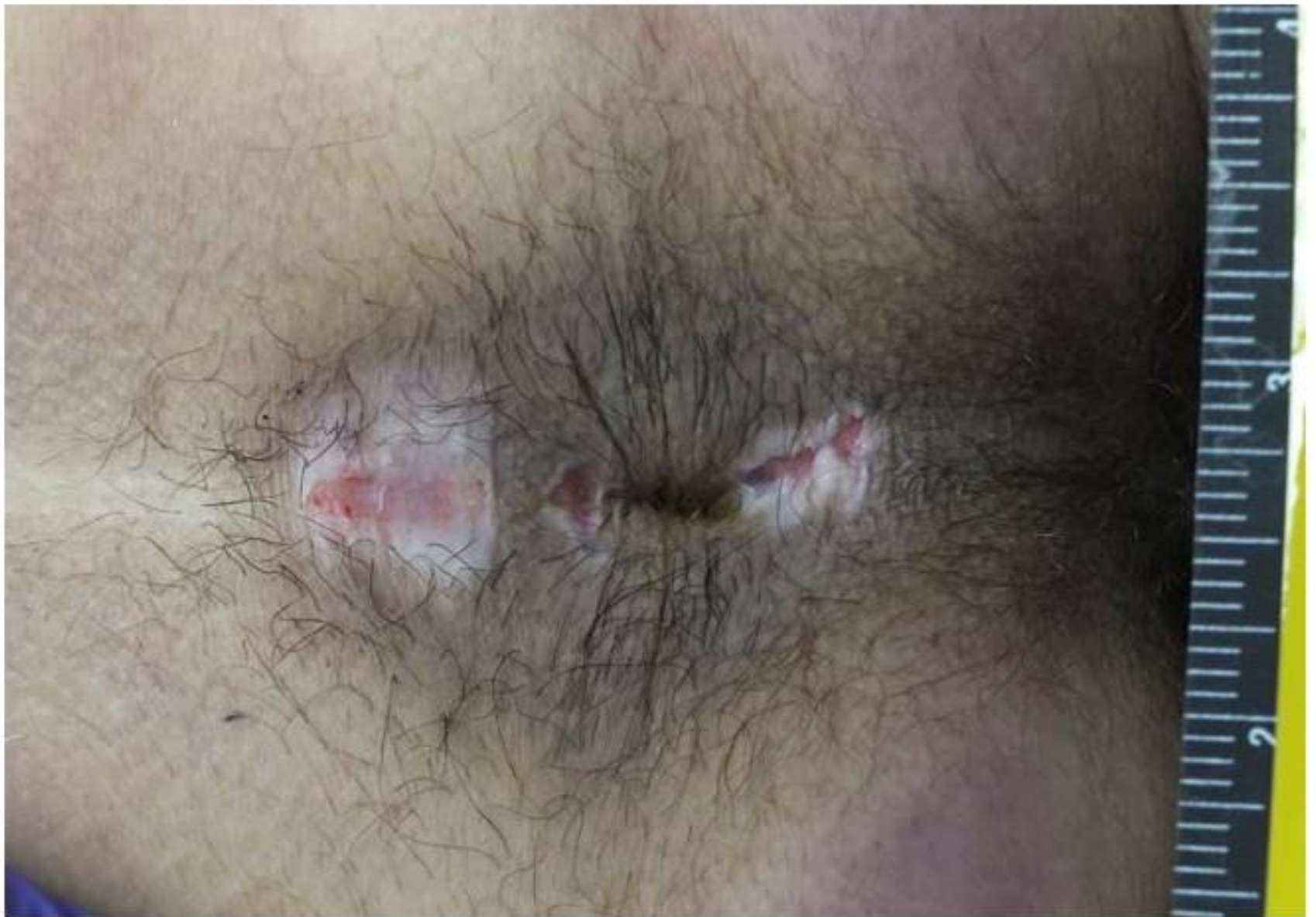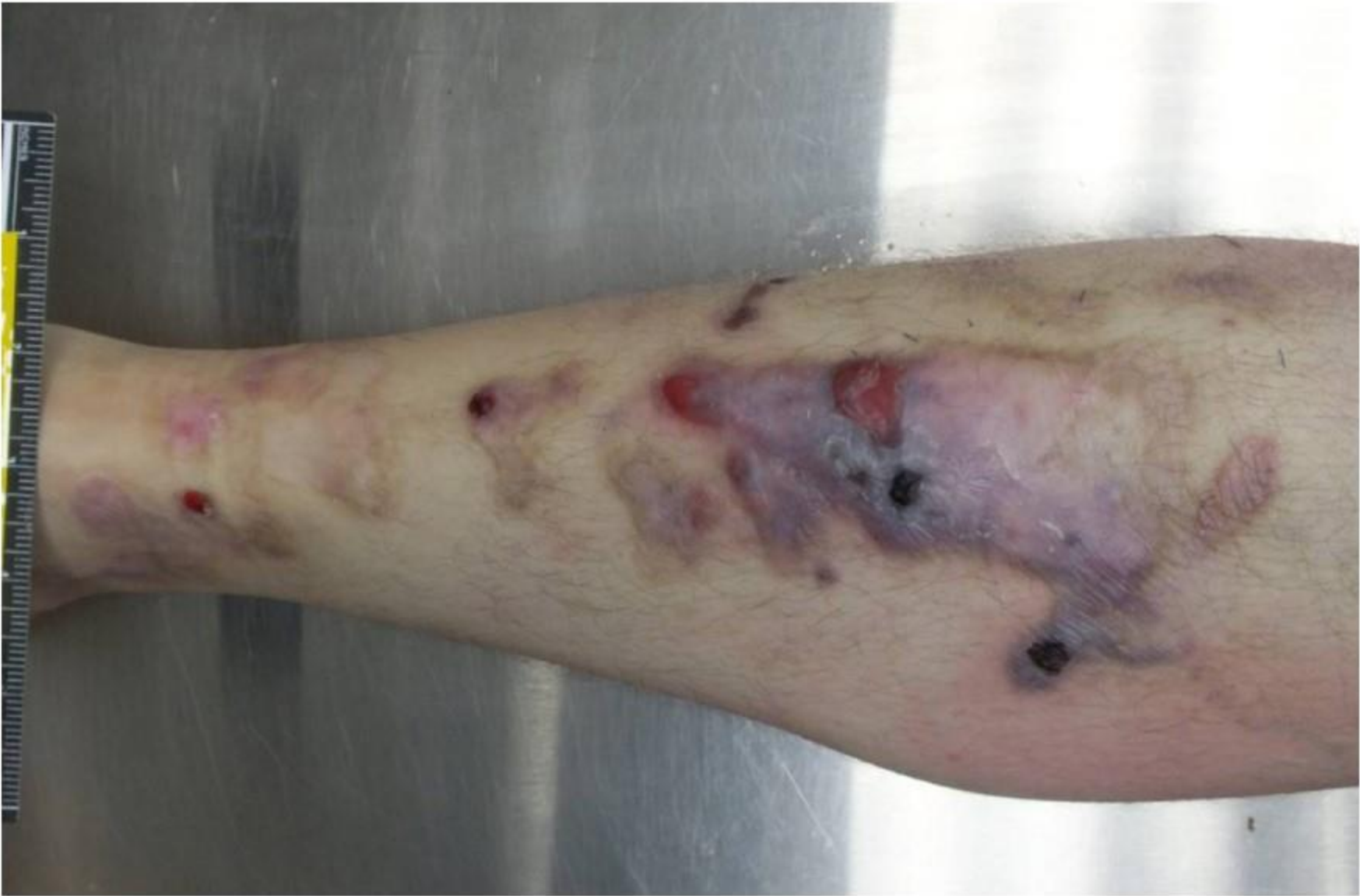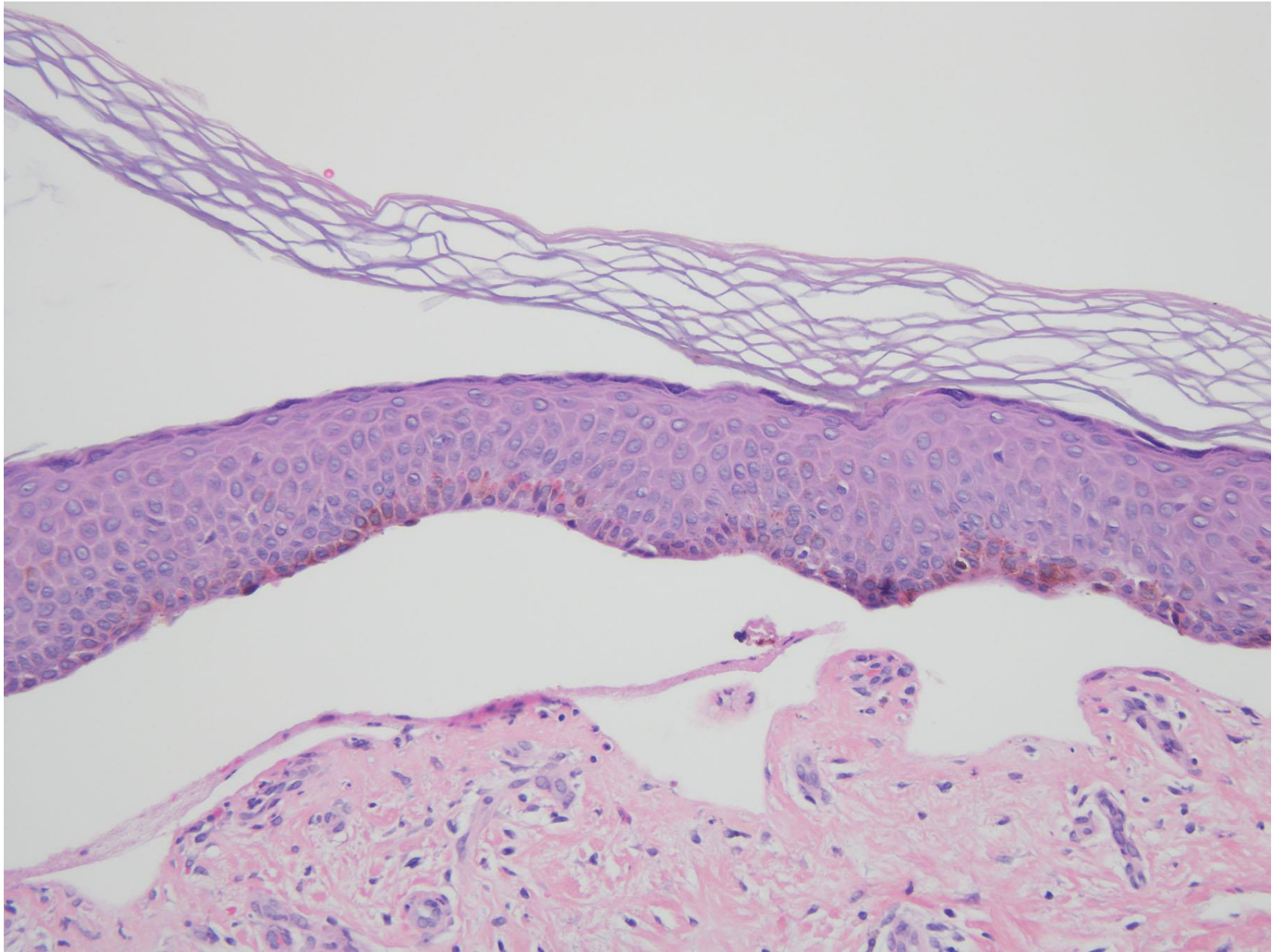


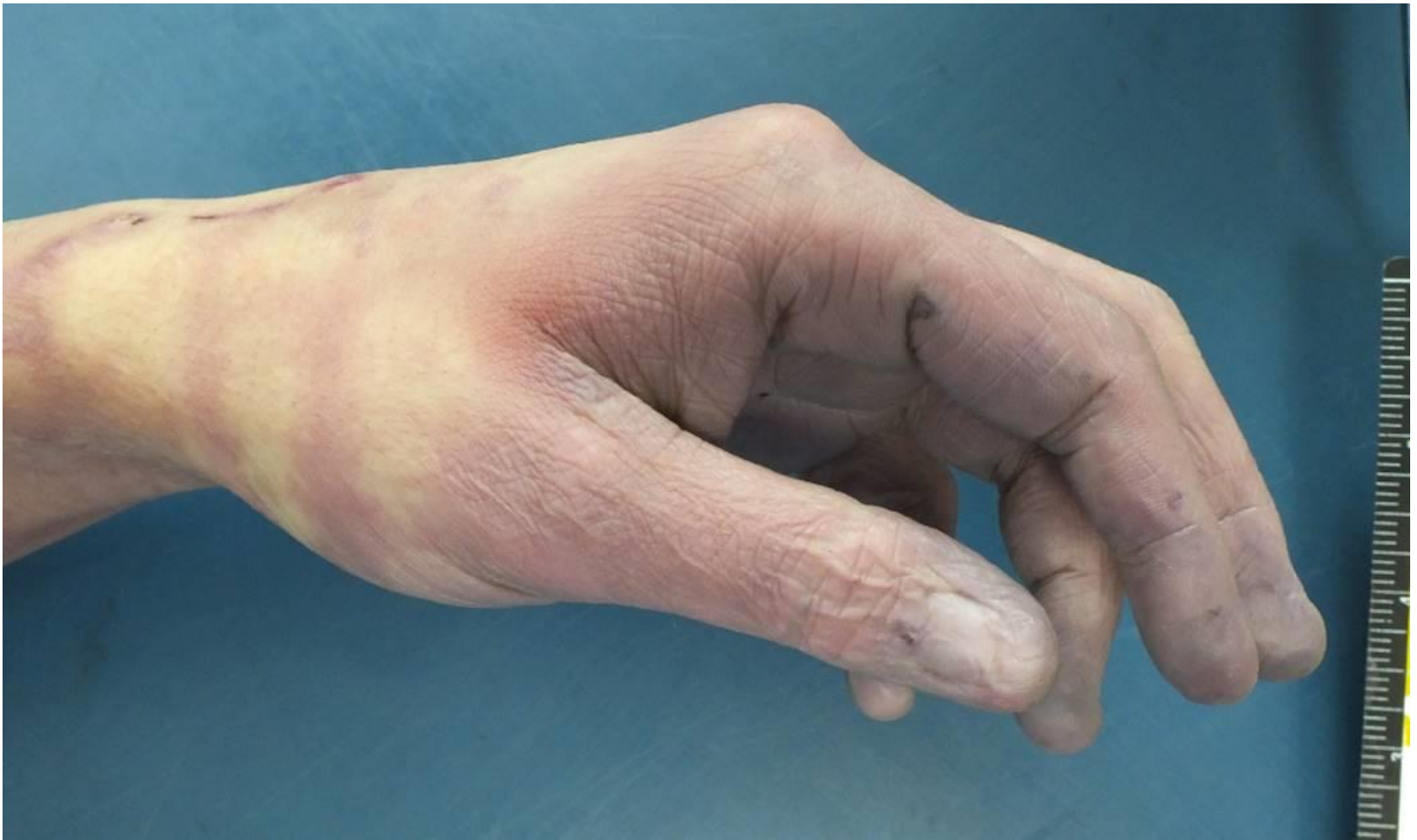Photo courtesy of Patrick Hansma, DO



1. These images are from a 30 year-old male who was found unresponsive in his jail cell. The perianal lesions are most consistent with:

- Remote trauma
- Recent trauma
- Infectious disease
- Postmortem artifact
- Inheritable disease





E. Inheritable disease (Correct answer, 33.19% of responses)

Dermatological examination revealed slightly elevated white plaques admixed with erosions on his shins. In addition, he had nail dystrophy accompanied by loss of some finger and toenails, and erosions in the perianal region. When medical records were later made available it was discovered that the decedent carried a diagnosis of epidermolysis bullosa (EB), although further clinical information regarding the specific subtype was not available.

There are two broad cutaneous disease categories bearing the name “epidermolysis bullosa”, which are hereditary EB and EB acquisita (EBA). The former is characterized by increased skin fragility and mechanically inducible mucocutaneous blisters. It encompasses a group of clinically and genetically heterogeneous entities with significant morbidity and mortality. EBA, on the other hand, is an autoimmune blistering disease mediated by autoantibodies to collagen VII. It can manifest as a non-inflammatory mechanobullous disease or have inflammatory subtypes, which mimic other blistering conditions. EBA has been reported to occur at any age. As for this case, the decedent may have had one of the subtypes of hereditary EB since birth, or acquired EBA, probably the mechanobullous type, later during his life, neither of which can be entirely ruled out with the clinical information available.

The diagnosis of hereditary EB relies on genetic analysis guided by results of ancillary studies such as transmission electron microscopy. Traditional light microscopy has relatively limited utility in the diagnosis of hereditary EB. As for EBA, the main histologic finding is subepidermal blister formation with variable degrees of inflammation depending on the specific subtype. Light microscopic findings in EBA may be indistinguishable from those seen in other autoimmune blistering diseases (see attached image). Additional studies such as direct / indirect immunofluorescence microscopy, and enzyme-linked immunosorbent assay are necessary for a definitive diagnosis of EBA.

A. Remote trauma (28.45% responses)

Okay – technically this one is correct too, but for the reasons noted above. Although the lesions are technically chronic trauma, they developed in the background of the decedent's underlying disorder and associated skin fragility. Given this association, the most appropriate answer choice would be the decedent's underlying diagnosis of EB.

B. Recent trauma (9.05% responses)

Recent trauma injuries would be expected to show tissue reaction, such as swelling, surrounding erythema, bleeding and possibly clots. The cutaneous findings are devoid of visible acute tissue reaction, and as such, more consistent with a chronic process.

C. Infectious disease (24.57% responses)

Infections with a number of different agents can be considered for the perianal lesions, such as fungal or viral. Sexually transmitted infections are also diagnostic considerations. However, in the context of his underlying diagnosis of EB and the other lesions on the extremities, perianal lesions would more likely be attributable to his underlying cutaneous disorder and associated skin fragility.

D. Postmortem artifact (4.74% responses)

Wounds/abrasions consistent with postmortem artifact are generally yellow-orange in color, due to lacking the "vital reaction" that happens following an antemortem injury. Antemortem injuries generally turn dark red when they dry.

References

Kridin K, Kneiber D, Kowalski EH, et al. Epidermolysis bullosa acquisita: A comprehensive review. *Autoimmun Rev.* 2019;18:786-795.

Laimer M, Proding C, Bauer JW. Hereditary epidermolysis bullosa. *J Dtsch Dermatol Ges.* 2015;13:1125-1133.