



# Case #11

NAME Educational Activities Committee

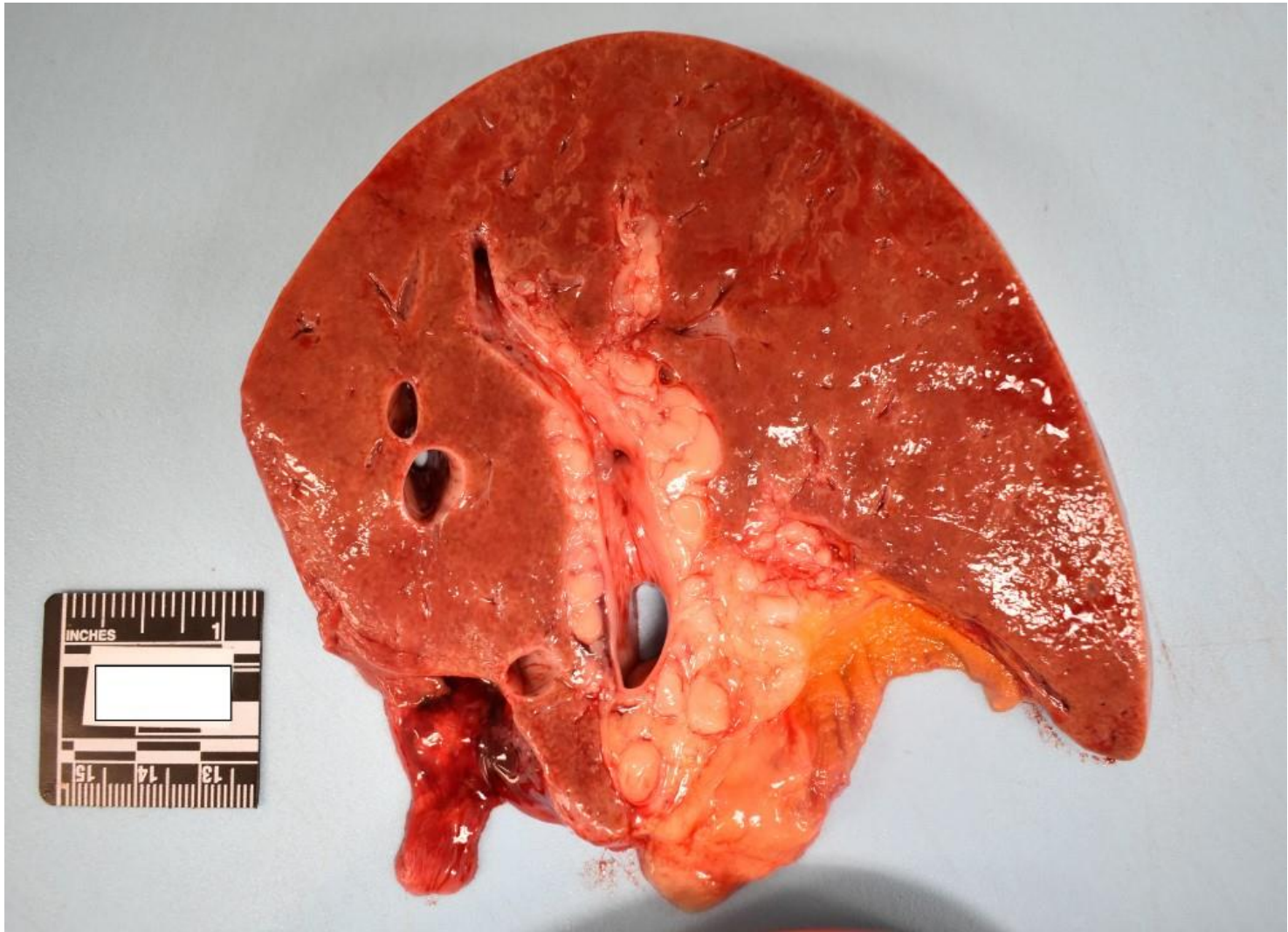


Photo courtesy of Theodore Brown, MD

Free Text Question:

A woman was shot and killed during an altercation. Her past medical history included a learning disability, pigmented macules of the skin, and benign skin nodules. At autopsy, sections of the liver revealed the finding depicted in the photograph.

Q1: What is the most likely diagnosis of the liver lesions?

Q2: What is her underlying genetic disorder?

Answer...

Q1: What is the most likely diagnosis of the liver lesions?

**Neurofibromatosis**

Q2: What is her underlying genetic disorder?

**Neurofibromatosis Type 1**

