

NAME 2017

Annual Meeting Program



October 13-17 2017
Scottsdale, AZ

thename.org

Thank you to our 2017 Annual Meeting Supporters & Exhibitors



Science Driven. Patient Focused.



A Donate Life Organization

Table of Contents

Welcome to Annual Meeting	4
DoubleTree Resort by Hilton Paradise Valley-Scottsdale Hotel Map	5
NAME Officers and Board of Directors	6
NAME Committees	8
Meeting Program	12
Exhibits:	
Exhibit Schedule	28
Exhibit Hall Map	29
Participating Exhibitor Descriptions	30
Optional/Special Programs:	
George E. Gantner, Jr., M.D. Annual Lecturer Award	35
NAME Foundation Outreach Fundraiser, High Profile Cases – Medicolegal Investigation of the Death of Michael Jackson	37
Rigor Run/Walk	37
Cadaver Open Golf Tournament	37
Learn To Lead, Rise, and Shine from the Chiefs Breakfast	38
Femme Fatale Luncheon	38
NAME Foundation Yoga by Donation	38
Abstracts	40
Author Index	90



NOTES

Welcome to the NAME 2017 Meeting!

Dear Colleagues and Friends,

Welcome to the National Association of Medical Examiners 2017 Annual Meeting. The NAME Annual Meeting provides an international forum for discussion of a broad range of issues pertaining to death investigation. This year we have much to discuss and a wonderful host city to enjoy.

Meeting Highlights

The 2017 Annual Meeting will be held from Friday, October 13 through Tuesday, October 17, 2017 at the DoubleTree Resort by Hilton Hotel Paradise Valley-Scottsdale.

Our meeting will feature presentations and posters that cover a broad range of topics.

On Sunday afternoon we will have a workshop which will explore the topic of Suspicious Deaths in Water.

The NAME Business Meeting will be held at the DoubleTree on Monday morning before the scientific sessions begin for the day. The business meeting will include discussion of matters of interest to all NAME members; we urge you to attend so that you may contribute your voice and vote to the decisions made by NAME.

The advance program and other information are available on NAME's website at <http://www.name2017.org/>.

Social Events

Friday evening will begin the social activities. Please help us welcome all the international attendees during the international attendees' reception. Following this will be our annual Friday evening welcome reception and dinner at the DoubleTree.

On Saturday early evening there will be a resident and fellow reception after the scientific sessions. This will precede a NAME Foundation Fundraiser on High Profile Deaths, centered around the death of Michael Jackson presented by forensic pathologists Drs. Lakshmanan Sathyavagiswaran and Christopher Rogers and anesthesiologist Dr. Steven Shafer.

The Rigor Run/Dead Man's Walk will take place early Sunday morning. The Cadaver Open Golf Tournament will be held Sunday afternoon following the morning scientific sessions.

Monday will begin with the Ask the Chiefs Breakfast. The Femme Fatale Luncheon will also take place on Monday.

The NAME Luncheon and Awards Ceremony will take place at the hotel on Tuesday. During the luncheon there will be a special presentation by Ross Zumwalt.

Special Acknowledgements

We gratefully acknowledge all who have provided input and effort into the planning and implementation of the meeting, especially the Members and Chair of the Education, Program and Publications Subcommittee. Thank you to our speakers for their contributions to the program and to our colleagues who have been appointed to moderate sessions. We would not be here without the expertise of the American Society for Investigative Pathology (ASIP), which serves as meeting manager, and of course our Executive Director, Denise McNally. In particular, please thank Tara Snethen of the ASIP team and Denise McNally when you see them.

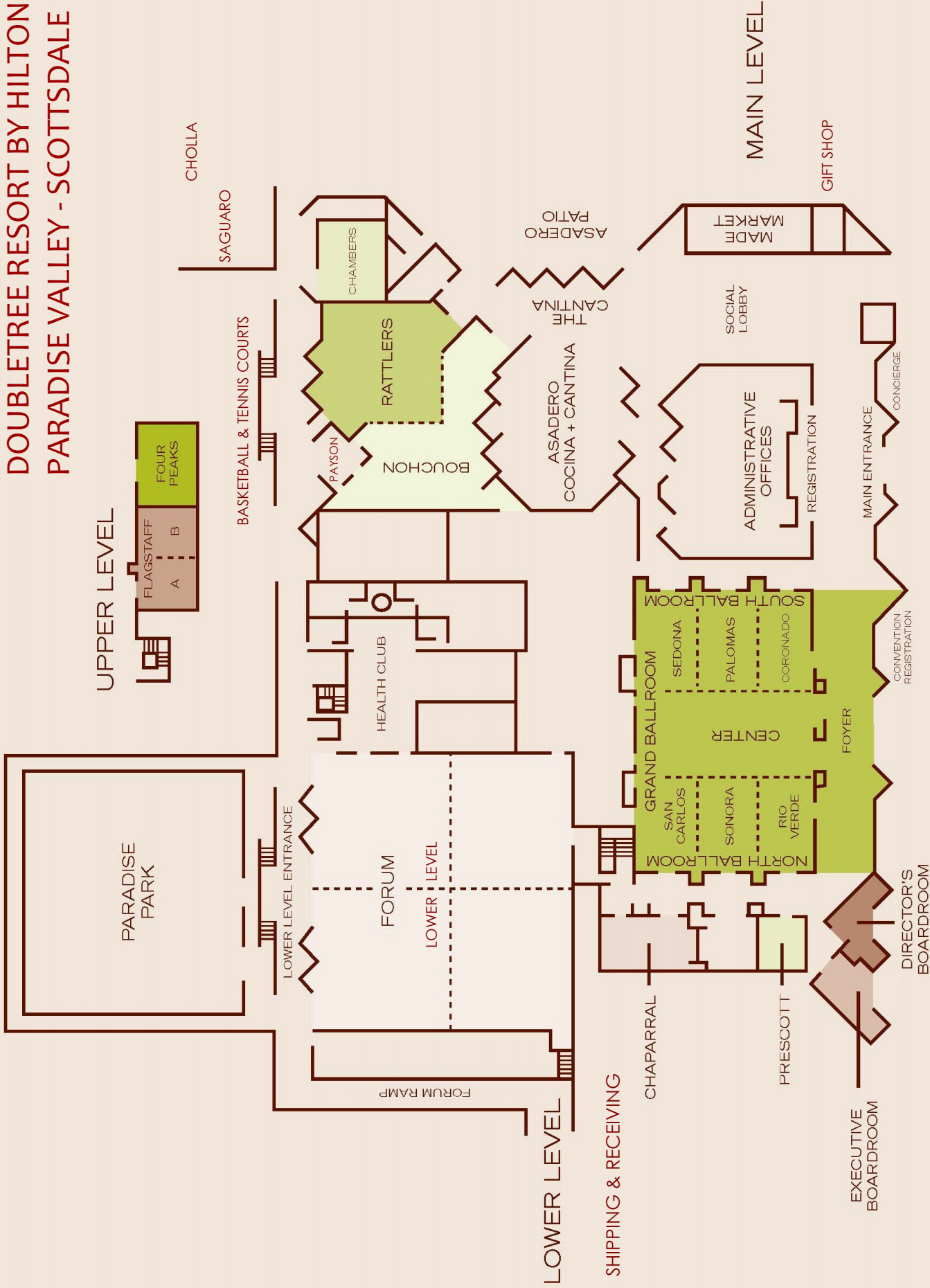
Finally, the leadership and members of NAME acknowledge the gracious support of vendors and sponsors, without whom the meeting would be impossible.

We hope that the scientific program organized by the Program Committee will meet your highest expectations. The leadership of NAME asks all members to guarantee future successful meetings and the overall success of NAME by actively participating in the organization by joining one of our many committees and by completing the online meeting survey that will be sent to all participants at the end of the meeting.

We welcome both our established and new colleagues and look forward to your active participation, which is essential to the success of this meeting. We hope that our new colleagues will consider joining NAME to take advantage of the year-round interactions that our current members enjoy.

Kathryn Pinneri, MD, 2017 Program Chair
Brian Peterson, MD, 2017 President

DOUBLETREE RESORT BY HILTON PARADISE VALLEY - SCOTTSDALE



NAME 2017 Officers and Board of Directors

***President**

BRIAN L. PETERSON, M.D.
Chief Medical Examiner
Milwaukee Co Medical Examiner
Office
933 West Highland Ave
Milwaukee, WI 53233
414-223-1200
brian.peterson@milwaukeecountywi.gov

***Vice-President**

KIM A. COLLINS, M.D.
Newberry Pathology Associates
Forensic Pathologist/Medical Director
Share Hope SC, Organ and Tissue
Services
1333 Martins Point Road
Wadmalaw Island, SC 29487
843-214-0378
843-557-1935
kimcollinsmd@gmail.com

***Secretary-Treasurer**

J. SCOTT DENTON, M.D.
McLean County Coroner's Office
2708 Piney Run
Bloomington, IL 61705
309-888-5210
yincision@comcast.net

BOARD OF DIRECTORS

***Chairman of the Board**

DAVID R. FOWLER, M.D.
Chief Medical Examiner
Maryland Off of Chief Medical
Examiner
900 West Baltimore Street
Baltimore, MD 21223
410-333-6292
fowlerd@ocmemd.org

***SALLY S. AIKEN, M.D. (2018)**

Chief Medical Examiner
Spokane Co Medical Examiner's
Office
5901 N. Lidgerwood
Spokane, WA 99208
509-477-4366
saiken@spokanecounty.org

CHRISTOPHER BODEN, B.S. (2018)

Chief Operating Officer
Broward Co Medical Examiner's Office
5301 SW 31st Avenue
Fort Lauderdale, FL 33312
954-357-5255
chrisbodenfl@gmail.com

TRACEY S. COREY, M.D. (2017)

166 Totem Rd
Louisville, KY 40207
502-376-5109
traceyscorey@aol.com

JOYCE L. DEJONG, D.O. (2019)

Western Michigan University Homer
Stryker M.D. School of Medicine
1000 Oakland Drive
Kalamazoo, MI 49008
517-896-8787
Joyce.dejong@med.wmich.edu

JOSEPH FELO, D.O. (2017)

Deputy Medical Examiner
Cuyahoga Co Medical Examiner's
Office
11001 Cedar Avenue
Cleveland, OH 44106
216-698-5491
jfelo@cuyahogacounty.us

LOUIS N. FINELLI, D.O. (2018)

Office of the Armed Forces Medical
Examiner
115 Purple Heart Drive
Dover AFB, DE 19902
302-346-8648
lfinelli13@verizon.net

**KENT E. HARSHBARGER, M.D.
(2019)**

Montgomery County Coroner Office
361 West Third Street
Dayton, OH 45402
937-225-4156
harshbargerkm@mcOhio.org

TOM HENSLEY, F-ABMDI (2019)

Chief of Forensic Operations and
Investigations
Jackson Co Medical Examiner's Office
950 E 21st Street
Kansas City, MO 64108
816-881-6600
mo_reb@yahoo.com

DIANNE LITTLE, MBBS (2017)

Forensic Pathology QHFSS, Ground
Floor
Block E, PED Building
Gold Coast University Hospital
Southport, Queensland 4215
Australia
+61756876537
dianne.little@sydney.edu.au

JUDY MELINEK, M.D. (2019)

PathologyExpert Inc.
3739 Balboa Street #102
San Francisco, CA 94121
415-850-7056
drjudymelinek@pathologyexpert.com

OWEN L. MIDDLETON, M.D. (2019)

Hennepin Co Medical Examiner Office
530 Chicago Avenue
Minneapolis, MN 55415-1518
612-215-6300
Owen.middleton@hennepin.us

***CHRISTOPHER M. MILROY, M.D.
(2018)**

The Ottawa Hospital-Univ of Ottawa
Division of Anatomic Pathology
501 Smyth Road, Box 117 4th Fl
Ottawa, ON K1H 8L6
Canada
613-737-8899
c.milroy@btinternet.com

WILLIAM R. OLIVER, M.D. (2019)

Regional Forensic Center
2761 Sullins Street
Knoxville, TN 37865
865-215-8000
name@billoblog.com

***KATHRYN PINNERI, M.D. (2017)**

205 Hilbig Road
Conroe, TX 77031
936-522-4502
Kpinneri@hotmail.com

**JOSEPH PRAHLOW, M.D. (Ex-
Officio)**

Forensic Pathologist and Professor of
Pathology
Western Michigan University Homer
Stryker M.D. School of Medicine
Department of Pathology
300 Portage Street
Kalamazoo, MI 49008
269-337-6174
Joseph.prahlw@med.wmich.edu

READE A. QUINTON, M.D. (2019)

Southwestern Inst of Forensic Science
2355 North Stemmons Freeway
Dallas, TX 75235
972-394-0495
Reade.quinton@dallascounty.org

**CHRISTOPHER B. ROGERS, M.D.
(2017)**

Chief of Forensic Medicine
Los Angeles Co Medical Examiner-
Coroner Office
1104 North Mission road
Los Angeles, CA 90033
323-343-0715
crogers@coroner.lacounty.gov

NAME 2017 Annual Meeting
Double Tree Resort by Hilton Hotel Paradise Valley – Scottsdale, Arizona

MICHELE T STAUFFENBERG, M.D. (2017)

363 Swanson Dr A
Lawrenceville, GA 30043
770-995-5558
icdeadpeople@earthlink.net

ROBERT STOPPACHER, M.D. (2019)

Onondaga County Medical Examiner Office
100 Elizabeth Blackwell Street
Syracuse, NY 13210
315-435-3163
hlrstop@ongov.net

LINDSEY C. THOMAS, M.D. (2018)

Forensic Pathologist
5109 Emerson Ave So
Minneapolis, MN 55419
612-730-3616
lindseycthasmd@gmail.com

SUZANNE R. UTLEY, M.D. (2017)

Medical Examiner
District 12 Medical Examiner
2001 Siesta Drive Suite 302
Sarasota, FL 34239
941-330-5605
utleysuzanne@hotmail.com

MICHAEL WARD, M.D. (2017)

Chief Medical Examiner
Greenville Co Coroner/ME Office
1190 West Faris Road
Greenville, SC 29609
864-522-1880
mward@ghs.org

SAMANTHA L. WETZLER, M.D. (2018)

Medical Examiner/Assistant Medical Director
Lifenet Health
1412 Linlier Drive
Virginia Beach, VA 23451
757-636-9650
sbwetzler@gmail.com

BARBARA C. WOLF, M.D. (2019)

District 5 Medical Examiner Office
809 Pine Street
Leesburg, FL 34748
352-326-5961
barbaracwolf@aol.com

*Indicates Member of Executive Committee

MARY ANN SENS, M.D., PH.D

NAME EXECUTIVE VICE PRESIDENT

Professor & Chair Pathology
University of North Dakota
School of Medicine and Health Sciences
UNDSMHS Pathology Room W424
1301 N. Columbia Rd, Stop 9037
Grand Forks, ND 58202-9037
701-777-2561
mary.sens@med.und.edu

DENISE MCNALLY
NAME EXECUTIVE DIRECTOR

362 Bristol Rd
Walnut Shade, MO 65771
660-734-1891
name@thename.org

NAME 2017 Committees

Ad hoc-AFP Journal Task Force

Daniel Atherton, MD
Evan Matshes, MD, *Chair*
Owen Middleton, MD
J. Keith Pinckard, MD, PhD
Kathryn Pinneri, MD
Jay Stahl-Herz, MD
Robert Stoppacher, MD
Odey Ukpo, MD
Margaret Warner, PhD

Ad hoc-Bioterrorism and Infectious Disease

Erin Brooks, MD, *Chair*
Paul Chui, DMJ
Karen Kelly, MD
Megan Quinn, MD
Lakshmanan Sathyavagiswaran, MD
Suzanne Utley, MD

Ad hoc-Data

Christopher Boden, BS
Kristine Cavicchi, MS, MPH
Steven Clark, PhD, *Consultant*
Stacy Drake, PhD
Randy Hanzlick, MD
Marcus Nashelsky, MD
Kathryn Pinneri, MD, *Chair*
Gregory Schmunk, MD
Carl Stacy, MD
Shawn Wilson, BS

Ad hoc-Forensic Toxicology

Clare Bryce, MD
Gregory J. Davis, MD, *Chair*
Andrew Falzon, MD
Karen Kelly, MD
Laura Labay
Nikolas Lemos, PhD
Jacqueline Martin, MD
Frank Miller, MD
D. Kimberley Molina, MD
Abraham Philip MD
Robert Stoppacher, MD

Ad hoc-Government Affairs

Jonathan Arden, MD
Andrew Baker, MD
Kristine Cavicchi, MS, MPH
Stephen Cina, MD
Kim Collins, MD
Gregory G. Davis, MD
Francisco Diaz, MD
Jamie Downs, MD
Daniel Dye, MD
Marianna Eserman, MD
Marcella Fierro, MD
Beth Frost, DO
Humphrey Germaniuk, MD
John Gerns, MFS
Kent Harshbarger, MD, JD
Tanisha Henson, MFS
Heather Jarrell, MD
F. John Krolikowski, MD

James Luke, MD
Marcus Nashelsky, MD
Kurt Nolte, MD
William Oliver, MD
Karen Ross, MD
Louis Smit, BA
Michael Steckbauer, MD
Lindsey Thomas, MD, *Chair*

Ad hoc-International Relations

Bamidele Adeagbo, MD
B.L. Bhootra, MD
Ryan Blumenthal, MD, PhD
Clare Bryce, MD
Paul Chui, DMJ
Kim Collins, MD, *Chair*
Giancarlo Di Vella, MD, PHD
Ljubisa Dragovic, MD
Norma Farley, MD
John Fernandes, MD, CM
Marcella Fierro, MD
John Gerns, MFS
Jeffrey Jentzen, MD
Mitra Kalelkar, MD
Martina Kennedy, DO
Feng Li, MD, JD
Dianne Little, MBBS
Judy Melinek, MD
Paul Morrow, MD
Thomas Noguchi, MD, *Emeritus Chair*
George Paul, MD
Eric Pfeifer, MD
Joseph Prahlow, MD
Valerie Rao, MD
Mario Rascon, MD
Gregory Schmunk, MD
Carl Stacy, MD
Shaku Teas, MD
Wieslawa Tlomak, MD
Lee Marie Tormos, MD
Alfredo Walker, MBBS
Barbara Wolf, MD
Ronald Wright, MD, JD

Ad hoc-ISO 17020 Transition

Sally Aiken, MD, *Chair*
Sam Andrews, M.D.
Carlo Campobasso, MD, PHD
Stacy Drake, PhD
Jonathan Eisenstat, MD
John Fernandes, MD, CM
Beth Frost, DO
Lee Ann Grossberg, MD
Amy Gruszecki, DO
Scott Luzi, MD
Amy McMaster Hawes, MD
D. Kimberley Molina, MD
Ken Obenson, MBBS
Robert Ross Reichard, MD
Carolyn Revercomb, MD
Krista Timm, MD
Alfredo Walker, MBBS
Shawn Wilson, BS
Barbara Wolf, MD

Dawn Zulauf, F-ABMDI

Ad hoc-Legal Affairs

Philip Berran, JD, MD
Jonathan Briskin, JD, MD
Robert Buchsbaum, JD, MD
John Hunsaker, JD, MD
Feng Li, JD, MD
Craig Mallak, JD, MD
Ronald Wright, JD, MD, *Chair*

Ad hoc-Organ and Tissue Procurement

Rebecca Asch-Kendrick, MD
Casey Bitting, DO
Kim Collins, MD
Sharon Derrick, PhD
Jonathan Eisenstat, MD
William Ashton Ennis, MD
John Fernandes, MD, CM
Amy Gruszecki, DO
Gregory Hess, MD
Louis Jares, BS
Michelle Jordan, MD
Roland Kohr, MD
Shaun Martin
Owen Middleton, MD
Frank Miller, MD
Catherine Miller, MD
Maneesha Pandey, MD
J. Keith Pinckard, MD, PHD
Gregory Schmunk, MD
Daniel Schultz, MD
Michael Steckbauer, MD
Jonathan Thompson, MD
Suzanne Utley, MD
Samantha Wetzler, MD, *Chair*

Ad hoc-Protocols for Interagency Interactions in Mass Fatality Incidents

Casey Bitting, DO
Emily Craig, PHD
Jonathan Eisenstat, MD
Peter Ellis, MBBChir
Samantha Evans, MD
Louis Finelli, DO
Beth Frost, DO
Jan Gorniak, DO
Tom Hensley, F-ABMDI
Karen Kelly, MD
Katherine Maloney, MD
Roger Mitchell, MD
Donna Price
Megan Quinn, MD
Suzanne Utley, MD, *Chair*
Shawn Wilson, BS

Ad hoc-Research

Russell Alexander, MD, *Chair*
Rebecca Asch-Kendrick, MD
Carri Cottengim, MA
Giancarlo Di Vella, MD, PhD
Stacy Drake, PhD

NAME 2017 Annual Meeting
Double Tree Resort by Hilton Hotel Paradise Valley – Scottsdale, Arizona

Jerri McLemore, MD
D. Kimberley Molina, MD
Keith Pinckard, MD

**Ad hoc-SIDS vs Child Abuse
Fatalities**

Thomas Andrew, MD
Tracey Corey, MD, *Chair*
Laura Crandall
Randy Hanzlick, MD
Wieslawa Tlomak, MD

Awards

Mary Case, MD, *Chair*
Edmund Donoghue, MD
James Gill, MD
M.G.F. Gilliland, MD
D. Kimberley Molina, MD
Gregory Schmunk, MD
Lindsey Thomas, MD

Bylaws

Jonathan Arden, MD, *Chair*
Christopher Boden, BS
Edmund Donoghue, MD
Marcus Nashelsky, MD
Gregory Schmunk, MD

**Education, Program and
Publications**

Sally Aiken, MD, Ex-Officio
Laura Knight, MD, Ex-Officio
Wendy Lavezzi, MD, Ex-Officio
Owen Middleton, MD, *Chair*
D. Kimberley Molina, MD, Ex-Officio
Robert Stoppacher, MD, Ex-Officio

**EPP-Maintenance of Certification
(MOC) and Self-Assessment
Modules (SAMs)**

Michelle Aurelius, MD
Nicholas Batalis, MD
Cassie Boggs, MD
Clare Bryce, MD
Steven Clark, PHD, *Advisor*
Amanda Fisher-Hubbard, MD
M.G.F. Gilliland, MD
Jan Gorniak, DO
Gregory Hess, MD
Martina Kennedy, DO
Laura Knight, MD, *Chair*
Amy Martin, MD
Maneesha Pandey, MD
Diane Peterson, MD
Susan Presnell, MD
Candace Schoppe, MD
Jonathan Thompson, MD
Andrea Wiens, DO
Timothy Williams, MD

EPP-Education / Program

Sally Aiken, MD, *Chair*
Rebecca Asch-Kendrick, MD
Michelle Aurelius, MD
Nicholas Batalis, MD
Louis Finelli, DO

James Gill, MD
Jennifer Hammers, DO
Gregory Hess, MD
Martina Kennedy, DO
Laura Knight, MD
Kelly Lear-Kaul, MD
Dianne Little, MBBS
Denise McNally
Roger Mitchell, MD
D. Kimberley Molina, MD
J. Keith Pinckard, MD
Kathryn Pinneri, MD
Christopher Poulos, MD
Carolyn Revercomb, MD
Barbara Sampson, MD
Gregory Schmunk, MD
Candace Schoppe, MD
Robert Stoppacher, MD
Tara Snethen, *Consultant*

**EPP-Forensic Fellow In-Service
Exam**

Eric Eason, MD
Amanda Fisher-Hubbard, MD
Jennifer Forsyth, MD
Jan Gorniak, DO
Dawn Holmes, MD
Tera Jones, MD
Michelle Jordan, MD
Karen Kelly, MD
Wendy Lavezzi, MD, *Chair*
Scott Luzi, MD
Jerri McLemore, MD
Ken Obenson, MBBS
Kathryn Pinneri, MD
Lori Proe, DO
Candace Schoppe, MD
Timothy Williams, MD

**EPP-Forensic Pathology Fellowship
Training**

Eric Eason, MD
Susan Ely, MD
Joseph Felo, DO
Meredith Frank, MD
Jeffrey Jentzen, MD
Karen Kelly, MD
Jessica Lelinski, MD
Scott Luzi, MD
Katherine Maloney, MD
D. Kimberley Molina, MD, *Chair*
Ken Obenson, MBBS
Ian Paul, MD
Eric Peters, MD
Mary Pietrangelo, MD
J. Keith Pinckard, MD
Reade Quinton, MD
Christopher Rogers, MD
Jeffrey Springer, MD
Michele Stauffenberg, MD
Wieslawa Tlomak, MD
Rebecca Wilcoxon, MD

EPP-Journal

Rebeca Asch-Kendrick, MD
Susan Ely, MD
John Lott, MS
Owen Middleton, MD, *Chair*
J. Keith Pinckard, MD, PhD, *Ex-Officio*
Robert Reichard, MD

EPP-Position Papers

Charles Harvey, MD
Owen Middleton, MD, *Chair*
Agnieszka Rogalska, MD
Steven White, MD, PHD

**EPP-Scientific Presentations
Awards**

Russell Alexander, MD
John Fernandes, MD
Jan Gorniak, DO
D. Kimberley Molina, MD
Diane Peterson, MD
J. Keith Pinckard, MD, PHD
Robert Stoppacher, MD, *Chair*
Mark Super, MD

Ethics Committee

Anthony Clark, MD
Gregory J. Davis, MD
Beth Frost, DO
Gary Goldfogel, MD
Kent Harshbarger, MD, JD, *Chair*
Charles Harvey, MD
Karen Kelly, MD
Scott Luzi, MD
Amy McMaster Hawes, MD
Frank Miller, MD
Reade Quinton, MD
Valerie Rao, MD
Mark Super, MD
Samantha Wetzler, MD

Finance Committee

Chris Boden, BS, *Chair*
J. Scott Denton, MD, *Ex-Officio*
Tom Hensley, F-ABMDI
Melissa Lallak, MBA
Christopher Poulos, MD

Inspection and Accreditation

Sally Aiken, MD
Ponni Arunkumar, MD
Lindsey Bayer, F-ABMDI
Pat Bencivenga, *Consultant*
Paul Chui, MBBS
Steven Clark, PHD, *Consultant*
Kim Collins, MD
Tracey Corey, MD
Joyce deJong, DO
Edmund Donoghue, MD
Ljubisa Dragovic, MD
Stacy Drake, PhD
Mark Fajardo, MD
David Fowler, MD
Randall Frost, MD
Jan Gorniak, DO
Amy Gruszecki, DO

NAME 2017 Annual Meeting
Double Tree Resort by Hilton Hotel Paradise Valley – Scottsdale, Arizona

Brett Harding, F-ABMDI
Amy Hart, MD
Charles Harvey, MD
Jeffrey Jentzen, MD
Karen Kelly, MD
Martina Kennedy, DO
F. John Krolikowski, MD
Melissa Lallak, MBA
Adele Lewis, MD
Marcus Nashelsky, MD
Maneesha Pandey, MD
George Paul, MD
William Pellan
Brian Peterson, MD
Diane Peterson, M.D.
Robert Ross Reichard, MD
Lakshmanan Sathyavagiswaran, MD
Gregory Schmunk, MD
Mary Ann Sens, MD
Kyle Shaw, MBBS
Rameen Starling-Roney, MD
Michele Stauffenberg, MD
Shaku Teas, MD
Krista Timm, MD
Wieslawa Tlomak, MD
Andrea Wiens, DO
Barbara Wolf, MD, *Chair*
Dawn Zulauf, RN, F-ABMDI

Membership and Credentials

Jonathan Arden, MD
J. Scott Denton, MD, *Ex-Officio*
Francisco Diaz, MD
Marie Herrmann, MD
Lakshmanan Sathyavagiswaran, MD
Gary Simmons, MD, *Chair*
A. Quinn Strobl, MD

Membership and Credentials – Affiliates

Christopher Boden, BS
Kristine Cavicchi, MS-MPA
Carri Cottengim, MA
Kathleen Diebold Hargrave, MA
Tom Hensley, F-ABMDI, *Chair*
Ernest Hernandez
Melissa Lallak, MBA
Nikolas Lemos, PhD
Lakshmanan Sathyavagiswaran, MD

NAME Foundation Board of Trustees

John Butts, MD
Mary Case, MD
Stephen Cina, MD, *Ex-Officio*
Joseph Felo, DO
Marcella Fierro, MD
David Fowler, MD, *Ex-Officio*
Jan Garavaglia, MD
Mary Goolsby, MD
Michael Graham, MD, *Treasurer*
Margaret Greenwald, MD, *Vice-Chair*
James Luke, MD
Amy Martin, MD
Yvonne Milewski, MD
Christopher Milroy, MD

Marcus Nashelsky, *Ex-Officio*
Thomas Noguchi, MD, *Founding Director*
Joseph Prahlow, MD, *Chair*
Michael Rieders, PHD
Gregory Schmunk, MD, *Secretary*
Joel Sexton, MD

Past Presidents

Andrew Baker, MD
Michael Bell, MD
John Butt, MD
Sandra Conradi, MD
Gregory G. Davis, MD
Edmund Donoghue, MD
Marcella Fierro, MD
Dave Fowler, MD
Jerry Francisco, D
Michael Graham, MD
Elliot Gross, MD
Ali Hameli, MD
Randy Hanzlick, MD
Lawrence Harris, MD
John Howard, MD
John Hunsaker, MD, JD
Jeffrey Jentzen, MD
Fred Jordan, MD
Joni McClain, MD
Marcus Nashelsky, MD
Thomas Noguchi, MD, *Chair*
Garry Peterson, MD, JD
Joseph Prahlow, MD
Donald Reay, MD
Lakshmanan Sathyavagiswaran, MD
Gregory Schmunk, MD
Mary Ann Sens, MD
William Sturner, MD
Ross Zumwalt, MD

Standards

Sally Aiken, MD
Sam Andrews, MD
Jonathan Arden, MD
Ponni Arunkumar, MD
Andrew Baker, MD, *Chair*
Paul Chui, DMJ
Steven Clark, PHD, *Consultant*
Stacy Drake, PHD
Marcella Fierro, MD
James Gill, MD
Julia Goodin, MD
Jan Gorniak, DO
Marie Herrmann, MD
Jeffrey Jentzen, MD
Karen Kelly, MD
John Lott, MS
Owen Middleton, MD
Valerie Rao, MD
Lakshmanan Sathyavagiswaran, MD
Gregory Schmunk, MD
Carl Stacy, MD
Strategic Planning
Sally Aiken, MD
Jonathan Arden, MD, *Chair*
Andrew Baker, MD
Christopher Boden, BS

Deiter Duff, MD
Julia Goodin, MD
Amy Gruszecki, DO
Owen Middleton, MD
Darinka Mileusnic-Polchan, MD, PhD
Frank Miller, MD
Roger Mitchell, MD
Thomas Noguchi, MD
Maneesha Pandey, MD
J. Keith Pinckard, MD, PhD
Donna Price, PhD
Mark Super, MD
Lindsey Thomas, MD
Alfredo Walker, MBBS
Barbara Wolf, MD

Liaisons

American Medical Association CPT Advisory Committee

J. Scott Denton, MD, *Delegate*
Paul Raslavicus, MD, *Alternate Delegate*

American Medical Association

J. Scott Denton, MD, *Alternate Delegate*
Aldo Fusaro, DO, *Delegate*

Association of Pathology Chairs (APC) Liaison

Mary Ann Sens, MD

College of American Pathologists (CAP) Liaison

Stephen Cina, MD

Consortium of Forensic Sciences Organizations (CFSO) Liaison

Kim Collins, MD

Intersociety Pathology Council Liaison

Mary Ann Sens, MD

NCRPCD

Gregory Schmunk, MD

Pathology Roundtable

Kim Collins, MD
Brian Peterson, MD
Mary Ann Sens, MD

World Association for Medical Law (WAML)

Thomas Noguchi, MD

NOTES

NAME 2017 MEETING PROGRAM

THURSDAY, OCTOBER 12, 2017

COMMITTEE MEETING [NOT CME]:

8:00 AM – 5:00 PM Executive Committee Meeting (Invitation Only)
Executive Boardroom, Main Level

FRIDAY, OCTOBER 13, 2017

GENERAL INFORMATION [NOT CME]:

10:00 AM – 4:00 PM Pre-Registration (Exhibitors & Attendees)
Northwest Wall, Main Level

10:00 AM – 4:00 PM Installation of Exhibits
Forum, Lower Level

5:30 PM – 6:30 PM International Attendee Reception
Palm Patio, Main Level
Sponsored by MTF Biologics

5:30 PM – 9:00 PM Grand Opening of Exhibits; Welcome Reception and Dinner (Registrants and Ticket Holders Only)
Forum, Lower Level

COMMITTEE MEETINGS [NOT CME]:

6:45 AM – 8:00 AM Foundation and Board of Directors Meeting & Continental Breakfast
Palm Patio, Main Level

7:00 AM – 8:00 AM Foundation Meeting
Bouchon, Main Level

8:00 AM – 4:00 PM Board of Directors Meeting
Bouchon, Main Level

12:00 PM – 1:00 PM Board of Directors Lunch
Palm Patio, Main Level

3:00 PM – 5:00 PM Ad Hoc Meeting on Protocols for Interagency Interactions in Mass Fatality Incidents
Prescott, Main Level

4:00 PM – 5:00 PM NAME Foundation Business Meeting
Chaparral, Main Level

4:00 PM – 6:00 PM Ad Hoc Meeting on Organ and Tissue Procurement
Four Peaks, Upper Level

SATURDAY, OCTOBER 14, 2017

****Indicates the following:***

*John Smialek Best Resident Paper/Poster Competition
**Mary Fran Ernst Best Affiliate Paper/Poster Competition
***Susan P. Baker Public Health Impact Award
****Best Student Paper/Poster Competition

GENERAL INFORMATION:

6:45 AM – 8:00 AM Buffet Breakfast (Registrants and Ticket Holders Only) [NOT CME]
Forum, Lower Level

6:45 AM – 4:00 PM Exhibits [NOT CME]
Forum, Lower Level

7:00 AM – 5:00 PM Registration [NOT CME]
Northwest Wall, Main Level

8:00 AM – 5:20 PM Posters
North Ballroom, Main Level

5:20 PM – 6:20 PM Resident/Fellow Reception [NOT CME]
Chaparral, Main Level

8:00 PM – 10:00 PM NAME FOUNDATION OUTREACH FUNDRAISER, High Profile Cases – Medicolegal Investigation of the Death of Michael Jackson [NOT CME]
South Center Ballroom, Main Level

COMMITTEE MEETINGS [NOT CME]:

7:00AM – 8:00AM	International Relations Committee Meeting <i>Chaparral, Main Level</i>
12:30PM – 2:00PM	Past President's Committee Meeting and Lunch <i>Executive Boardroom, Main Level</i>
12:30PM – 2:00PM	Journal Editorial Board Meeting <i>Chaparral, Main Level</i>
12:30PM – 2:00PM	Ethics Committee Meeting and Lunch <i>Prescott, Main Level</i>
6:00PM – 8:00PM	Forensic Pathology Training Subcommittee Meeting <i>Prescott, Main Level</i>

PROGRAM INFORMATION:

8:00 AM – 10:00 AM	SESSION 1: IT'S NOT A MIRAGE: COLLABORATION WORKS! Moderators: Lindsey C. Thomas, Minneapolis, MN, United States of America and Steven Clark, NAME R&D Director, Big Rapids, MI, United States of America <i>South Center Ballroom, Main Level</i>
8:15 AM — 8:30 AM	1.1 The National Institute of Justice's Medical Examiner – Coroner Program <i>Luther Schaeffer, National Institute of Justice/United States Department of Justice, Washington, District of Columbia, United States of America</i>
8:30 AM — 8:50 AM	1.2 The Forensic Pathologist and the Trauma Surgeon <i>Christopher Rogers, MD, Los Angeles County Medical Examiner-Coroner, Los Angeles, California, United States of America</i>
8:50 AM — 9:20 AM	1.3 NamUs: The National Missing & Unidentified Persons System <i>Michael L. Nance, National Missing & Unidentified Persons System (NamUs), Fort Worth, Texas, United States of America</i>
9:20 AM — 9:50 AM	1.4 Updates on the National Violent Death Reporting System (NVDRS) <i>Katherine A. Fowler, PhD, Centers for Disease Control and Prevention, Atlanta, Georgia, United States of America</i>
9:50 AM – 10:00 AM	Questions
10:00 AM – 10:30 AM	VISIT EXHIBITS [NOT CME] <i>Forum, Lower Level</i>
10:00 AM – 10:30 AM	BREAK [NOT CME] <i>Forum, Lower Level</i> <i>Sponsored by MTF Biologics</i>
10:00 AM – 10:30 AM	VISIT POSTERS <i>North Ballroom, Main Level</i>
10:30 AM – 12:45 PM	SESSION 2: THE HEAT OF THE MOMENT: ADMINISTRATIVE TOPICS Moderators: Sandra E. Conradi, Retired Chief Medical Examiner, Charleston, SC, United States of America and Beth Frost, Maricopa County Office of the Medical Examiner, Phoenix, AZ, United States of America <i>South Center Ballroom, Main Level</i>
10:30 AM — 10:45 AM	2.1 Clarifying ISO/IEC 17020 Accreditation, Don't Kill the Messenger <i>Sally S. Aiken, MD, Spokane County Medical Examiner's Office, Spokane, Washington, United States of America</i>
10:45 AM — 11:00 AM	2.2 Developing Competence By Design Training in Forensic Pathology - The Canadian Experience <i>Jacqueline L. Parai, MD, MSc, University of Ottawa, Ottawa, Ontario, Canada</i>

11:00 AM — 11:30 AM	2.3 "I Didn't Choose This Field Because I Enjoy Talking to Families": Best Practices for Communicating with Next of Kin <i>Joanne Gould Kuntz, MD, Emory University School of Medicine, Atlanta, Georgia, United States of America</i>
11:30 AM — 11:50 AM	2.4 Facility Simulation Process Modeling <i>Adam Michael Denmark, BA, SmithGroupJJR, Phoenix, Arizona, United States of America</i>
11:50 AM — 12:00 PM	2.5 Critical Value Reporting and Forensic Pathology: Is it that Critical? <i>Ken Obenson, MD, Saint John Regional Hospital - Dalhousie University, Saint John, , Canada</i>
12:00 PM — 12:30 PM	2.6 Improving Photomicrographs By Postprocessing Using Open Source Software <i>William R Oliver, Regional Forensic Center, Knoxville, Tennessee, United States of America</i>
12:30 PM – 12:45 PM	Questions
12:45 PM – 2:00 PM	LUNCH (ON YOUR OWN) [NOT CME]
2:00 PM – 3:30 PM	SESSION 3 (Part 1): THIRSTING FOR KNOWLEDGE: BEST RESIDENT/STUDENT PAPERS Moderators: Marianne E. Beynon, Baylor College of Medicine, Houston, TX, United States of America and Judy Melinek, Alameda County Sheriff-Coroner & PathologyExpert, Alameda County, CA, United States of America <i>South Center Ballroom, Main Level</i>
2:00 PM — 2:10 PM	3.1 Parachute Deaths in Southern Arizona <i>***Rose Marie Cronin, University of Arizona Honors College, Tucson, Arizona, United States of America</i>
2:10 PM — 2:20 PM	3.2 Carfentanil and Current Opioid Trends in Summit County, Ohio <i>*Kristy Waite, DO, Summa Health System, Akron, Ohio, United States of America</i>
2:20 PM — 2:30 PM	3.3 Validation of an HCV Rapid Antibody Test in Postmortem Specimens <i>*Claire E. Rose, MD, University of TN Graduate School of Medicine, Knoxville, Tennessee, United States of America</i>
2:30 PM — 2:40 PM	3.4 Hyperoxalosis Secondary to Intravenous Vitamin C Administration as a Non-Allopathic Treatment for Cancer <i>*Mark A Giffen, DO, Wake Forest University Baptist Medical Center, Winston Salem, North Carolina, United States of America</i>
2:40 PM — 2:50 PM	3.5 What's the Huff? A Review of Seven 1,1-Difluoroethane Fatalities <i>*Lauren A. Havrilla, DO, Duke University Medical Center, Durham, North Carolina, United States of America</i>
2:50 PM — 3:00 PM	3.6 Investigation into the Potential for Post-mortem Formation of Carboxyhaemoglobin in Bodies Retrieved from Fires <i>****Claire Janece Sully, BS, Forensic Science South Australia, Adelaide, , Australia</i>
3:00 PM — 3:10 PM	3.7 Death Following Liposuction: A Case Series <i>*Kirstin E. Howell, MD, Cook County Medical Examiner's Office, Chicago, Illinois, United States of America</i>
3:10 PM — 3:20 PM	3.9 What Is The Manner of Death? Forensic Aspects of Sudden Cardiac Death Events After Significant Emotional Stress. A Case Series. <i>*Iana Lesnikova, MD, PhD, Brody School of Medicine, East Carolina University, Greenville, North Carolina, United States of America</i>

3:20 PM — 3:30 PM	Questions
3:30 PM – 4:00 PM	VISIT EXHIBITS [NOT CME] <i>Forum, Lower Level</i>
3:30 PM – 4:00 PM	BREAK [NOT CME] <i>Forum, Lower Level</i> <i>Sponsored by MTF Biologics</i>
3:30 PM – 4:00 PM	VISIT POSTERS <i>North Ballroom, Main Level</i>
4:00 PM – 5:30 PM	SESSION 3 (Part 2): THIRSTING FOR KNOWLEDGE: BEST RESIDENT/STUDENT PAPERS Moderators: Dan Schultz, LifeLink Tissue Bank & Final Diagnosis, Inc, Tampa, FL, United States of America and Giancarlo Di Vella, University of Turin, Italy <i>South Center Ballroom, Main Level</i>
4:00 PM — 4:15 PM	3.10 Fatal Hypoxic Ischemic Brain Injury, Cervical Spinal Nerve Root/Ganglia Hemorrhages and Retinal Hemorrhages Associated With Oropharyngeal Pedunculated Polyp in an Infant <i>*Emilie V. Cook, DO, James H. Quillen School of Medicine/East Tennessee State University, Johnson City, Tennessee, United States of America</i>
4:15 PM — 4:30 PM	3.11 Characteristics of Fire and Carbon Monoxide Inhalation-Related Homicides in Wayne County, Michigan <i>*Kyle S. Conway, MD, JD, University of Michigan, Ann Arbor, Michigan, United States of America</i>
4:30 PM — 4:45 PM	3.12 Unusual Suicides: A Florida Case Series <i>*Ashley Renee Perkins, DO, MS, University of South Florida, Tampa, Florida, United States of America</i>
4:45 PM — 5:00 PM	3.13 Common Cause and Manner of Early Death in Autism with Respect to Scene Investigation <i>*Jensyn K. Cone, MD, Beth Israel Deaconess Medical Center, Boston, Massachusetts, United States of America</i>
5:00 PM — 5:15 PM	3.14 Silicone Pulmonary Emboli Resulting from Illegal Buttock Injections: A Tale of Two Cities <i>*Stacey Murthy, MD, Southwestern Institute of Forensic Sciences, Dallas, Texas, United States of America</i>
5:15 PM – 5:30 PM	Questions

SUNDAY, OCTOBER 15, 2017

GENERAL INFORMATION:

6:30 AM – 8:20 AM	Rigor Run/Walk (Optional) [NOT CME]
6:45 AM – 8:20 AM	Buffet Breakfast (Registrants and Ticket Holders Only) [NOT CME] <i>Forum, Lower Level</i>
8:00 AM – 1:15 PM	Exhibits [NOT CME] <i>Forum, Lower Level</i>
7:00 AM – 12:30 PM	Registration [NOT CME] <i>Northwest Wall, Main Level</i>
8:00 AM – 6:30 PM	Posters <i>North Ballroom, Main Level</i>
1:00 PM – 5:00 PM	23 rd Annual Cadaver Open Golf Tournament (Optional) [NOT CME] <i>*Additional Payment Required*</i> <i>Sponsored by CryoLife, Inc.</i>

4:30 PM – 5:30 PM NAME Foundation Yoga by Donation [NOT CME]
Health Club

COMMITTEE MEETING [NOT CME]:

12:45 PM – 5:45 PM Strategic Planning Committee Meeting
Executive Boardroom, Main Level

5:30 PM – 6:30 PM Inspection and Accreditation Committee Meeting
Chaparral, Main Level

6:30 PM – 10:30 PM Inspection and Accreditation Training
Chaparral, Main Level

PROGRAM INFORMATION:

8:30 AM – 10:00 AM **SESSION 4: HOT TOPICS IN PUBLIC HEALTH**
Moderators: Heather Jarrell, Office of the Medical Investigator, Albuquerque, NM, United States of America and Catherine R. Miller, The University of Texas Medical Branch, Galveston, TX, United States of America
South Center Ballroom, Main Level

8:30 AM — 8:45 AM 4.1 Medical Assistance in Dying - Early Experiences in Alberta, Canada
****Mitchell L. Weinberg, MD, Alberta Office of the Chief Medical Examiner, Edmonton, Alberta, Canada*

8:45 AM — 9:00 AM 4.2 The Elephant in the Room: Outbreak of Carfentanil Deaths in Minnesota and the Importance of Multiagency Collaboration
****Rebecca M. Wilcoxon, MD, Hennepin County Medical Examiner's Office, Minneapolis, Minnesota, United States of America*

9:00 AM — 9:15 AM 4.3 The Shock of Strep: Rapid Deaths Due to Group A Streptococcus
****Katrina Thompson, MD, University of Wisconsin Hospital and Clinics, Madison, Wisconsin, United States of America*

9:15 AM — 9:30 AM 4.4 Exercise-Associated Hyponatremia
****Paul S. Uribe, MD, USAMEDDAC, Fort Benning GA, Fort Benning, Georgia, United States of America*

9:30 AM — 9:45 AM 4.5 The Importance of Infectious Disease Reporting
****Kathryn Pinneri, MD, Montgomery County Forensic Services, Conroe, Texas, United States of America*

9:45 AM — 10:00 AM 4.6 Death Certification in Northern Alberta: Error Occurrence Rate and Educational intervention
**Kimberly A. Wood, MD, MS, University of Alberta, Edmonton, , Canada*

10:00 AM — 10:15 AM 4.7 Drug Overdose Deaths Involving Fentanyl: The National Picture
***Margaret Warner, PhD, National Center for Health Statistics, Hyattsville, Maryland, United States of America*

10:15 AM – 10:45 AM VISIT EXHIBITS [NOT CME]
Forum, Lower Level

10:15 AM – 10:45 AM BREAK [NOT CME]
Forum, Lower Level

10:15 AM – 10:45 AM VISIT POSTERS
North Ballroom, Main Level

- 10:45 AM – 12:00 PM** **SESSION 5: SUSPICIOUS DEATHS IN WATER WORKSHOP**
Moderators: Laura Knight, MD, Washoe County Regional Medical Examiner's Office, Reno, NV, United States of America
South Center Ballroom, Main Level
- 10:45 AM — 12:00 PM 5.1 Suspicious Deaths in Water Workshop
Laura D. Knight, MD, Washoe County Regional Medical Examiner's Office, Reno, Nevada, United States of America
- 12:00 PM – 1:30 PM LUNCH (ON YOUR OWN) [NOT CME]
- 12:00 PM – 1:00 PM VIEW POSTERS P1 – P40
North Ballroom, Main Level
- 1:30 PM – 3:00 PM** **SESSION 6: FEELING THE HEAT: NEUROPATHOLOGY**
Moderators: Elizabeth Bundock, Office of the Chief Medical Examiner, Burlington, VT, United States of America and Katherine Maloney, Erie County Medical Examiner's Office, Buffalo, NY, United States of America
South Center Ballroom, Main Level
- 1:30 PM — 1:45 PM 6.1 Leptomeningeal Melanocytic Brain Tumor Associated with Nevus of Ota: Case Report and Review of Literature
Francesco Pontoriero, DO, Rutgers-Robert Wood Johnson Medical School, New Brunswick, New Jersey, United States of America
- 1:45 PM — 2:00 PM 6.2 Cerebral Vasculitis in a Young Adult: A Diagnostic Algorithm for The Medical Examiner.
Avneesh Gupta, MD, University of Michigan, Ann Arbor, Michigan, United States of America
- 2:00 PM — 2:15 PM 6.3 Cerebral Infarcts Caused by Topical Hemostatic Agent Embolism: Two Case Reports and Literature Review
Wiesława Tłomak, MD, Milwaukee County Medical Examiner's Office, Milwaukee, Wisconsin, United States of America
- 2:15 PM — 2:30 PM 6.4 Maximizing use of Human Brain Donations for Research on Autism Spectrum Disorders
Cynthia M. Schumann, PhD, University of California at Davis, Sacramento, California, United States of America
- 2:30 PM — 2:50 PM 6.5 Occupational Exposure to Radioactive Isotopes After Brain Death Study: Knowing a "Hot" Body When You See One
Virginia L Richards, MD, MS, Westchester County Medical Examiner, Valhalla, New York, United States of America
- 2:50 PM – 3:00 PM Questions

MONDAY, OCTOBER 16, 2017

GENERAL INFORMATION:

- 6:45 AM – 8:00 AM Buffet Breakfast (Registrants and Ticket Holders Only) [NOT CME]
Forum, Lower Level
- 6:45 AM – 4:00 PM Exhibits [NOT CME]
Forum, Lower Level
- 7:00 AM – 5:00 PM Registration [NOT CME]
Northwest Wall, Main Level
- 7:00 AM – 8:00 AM Learn To Lead, Rise, and Shine from the Chiefs Breakfast (Optional) [NOT CME]
Rattlers, Main Level
- 8:00 AM – 4:00 PM Posters
North Ballroom, Main Level

12:00 PM – 1:30 PM Feme Fatale Luncheon (Optional) [NOT CME]
Additional Payment Required
Bouchon, Main Level

6:30 PM – 8:30 PM Board of Directors Reception (Invitation Only) [NOT CME]
East Park

PROGRAM INFORMATION:

8:00 AM – 9:50 AM NAME Business Meeting [NOT CME]
South Center Ballroom, Main Level

9:50 AM – 10:20 AM VISIT EXHIBITS [NOT CME]
Forum, Lower Level

9:50 AM – 10:20 AM BREAK [NOT CME]
Forum, Lower Level

10:20 AM – 12:00 PM NAME Business Meeting [NOT CME]
South Center Ballroom, Main Level

12:00 PM – 1:30 PM LUNCH (ON YOUR OWN) [NOT CME]

12:00 PM – 1:00 PM VIEW POSTERS P41 – P76
North Ballroom, Main Level

1:30 PM – 3:30 PM **SESSION 7: NO DROUGHT HERE: TOXICOLOGY DEATHS**
Moderators: Laura Labay, NMS Labs, Willow Grove, Pennsylvania, United States of America and William R. Oliver, Regional Forensic Center, Knoxville, TN, United States of America
South Center Ballroom, Main Level

1:30 PM — 1:45 PM 7.1 Value of Postmortem Oral Fluid Analysis for Detection of Illicit and Prescription Drugs in Forensic Pathology,
Maneesha Pandey, MBBS, Lucas County Coroner's Office, Toledo, Ohio, United States of America

1:45 PM — 2:00 PM 7.2 How Many Pills Were Ingested? Danger Ahead, Proceed with Caution!
Laura Labay, PhD, NMS Labs, Willow Grove, Pennsylvania, United States of America

2:00 PM — 2:15 PM 7.3 Intrauterine Fetal Demise and Methamphetamine Exposure
Andrea L. Wiens, DO, Oklahoma Office of the Chief Medical Examiner, Tulsa, Oklahoma, United States of America

2:15 PM — 2:30 PM 7.4 Isn't Loperamide a Safe Over-The-Counter Anti-Diarrhea Medication?
Ayako Chan-Hosokawa, MS, NMS Labs, Willow Grove, Pennsylvania, United States of America

2:30 PM — 2:45 PM 7.5 Toxicology Results from an Immunoassay-only Panel Compared to Expanded LCQTOF Testing in a Series of 57 Death Investigation Cases.
Barry K. Logan, PhD, F-ABFT, NMS Labs, Willow Grove, Pennsylvania, United States of America

2:45 PM — 3:00 PM 7.6 The Family and Friends Discount: Fatal Drug Overdoses Involving Multiple Family Members or Friends
Sara E. Ohanessian, MD, Virginia Office of Chief Medical Examiner, Roanoke, Virginia, United States of America

- 3:00 PM — 3:15 PM 7.7 Unusual Fentanyl Overdoses: 2 Case Reviews (Neither one is Prince)
Leah L.E. Bush, MS, MD, Virginia Commonwealth University, Richmond, Virginia, United States of America
- 3:15 PM — 3:30 PM 7.8 Illicit Drug Abuse in the Elderly
Ellen Moffatt, MD, San Francisco Office of the Chief Medical Examiner, San Francisco, California, United States of America
- 3:30 PM – 4:00 PM VISIT EXHIBITS [NOT CME]
Forum, Lower Level
- 3:30 PM – 4:00 PM BREAK [NOT CME]
Forum, Lower Level
- 3:30 PM – 4:00 PM VISIT POSTERS
North Ballroom, Main Level
- 4:00 PM – 5:45 PM** **SESSION 8 : IT'S A HOT MESS OF TOPICS: POTPOURRI**
Moderators: Ellen Moffatt, Office of the Chief Medical Examiner, San Francisco, CA, United States of America and L.J. Dragovic, Oakland County Medical Examiner's Office, Pontiac, MI, United States of America
South Center Ballroom, Main Level
- 4:00 PM — 4:15 PM 8.1 Determination of Manner of Death in Snake Bite Related Fatalities: A Comparison of Accident vs. Suicide
Kendall Von Crowns, MD, Travis County Medical Examiner's Office, Austin, Texas, United States of America
- 4:15 PM — 4:30 PM 8.2 Anterior Cervical Spine Fractures with Accompanying Prevertebral Fascial Hemorrhage but Without Cervical Spinal Cord Injury: A Casual Observation at a Forensic Autopsy or a Finding of Potential Clinical Relevance?
Michael Jeffrey/J Caplan, Suffolk County Office of the Medical Examiner, Hauppauge, New York, United States of America
- 4:30 PM — 4:45 PM 8.3 Whole Body Digital Scanning (WBDS) vs Computed Axial Tomography (CT): Experience of the Armed Forces Medical Examiner System (AFMES)
Howard T. Harcke, MD, Armed Forces Medical Examiner System, Dover AFB, Delaware, United States of America
- 4:45 PM — 5:00 PM 8.4 Streptococcal Wound Infection in a Pathologist Following a Scalpel Injury During an Autopsy of a Man with Fatal Group A Streptococcal Bacteremia
Michael Bell, MD, Palm Beach Medical Examiner Office, West Palm Beach, Florida, United States of America
- 5:00 PM — 5:15 PM 8.5 Organ/Tissue Procurement Organization Costs Associated with Tissue Recovery from ME/C Cases
Kim A Collins, MD, Newberry Pathology Associates, Wadmalaw Island, South Carolina, United States of America
- 5:15 PM — 5:30 PM 8.6 Beyond Bone Chips and Corneas
Kim A Collins, MD, Newberry Pathology Associates, Wadmalaw Island, South Carolina, United States of America
- 5:30 PM — 5:45 PM 8.7 Increasing Tissue Donations From A Non-Hospital Death Referral System Via ME/Coroner EMR
Ron Gegg, Mid-America Transplant, St. Louis, Missouri, United States of America

TUESDAY, OCTOBER 17, 2017

GENERAL INFORMATION:

- 6:30 AM – 8:00 AM Buffet Breakfast (Registrants and Ticket Holders Only) [NOT CME]
South Forum, Lower Level
- 7:00 AM – 5:00 PM Registration [NOT CME]
Northwest Wall, Main Level

PROGRAM INFORMATION:

- 8:00 AM – 10:00 AM** **SESSION 9: HOT 'LITTLE' TOPICS: PEDIATRICS**
Moderators: Gregory A. Schmunck, Polk County Medical Examiner, Des Moines, IA, United States of America and Adele Lewis, Medical Examiner Office, Nashville, TN, United States of America
South Center Ballroom, Main Level
- 8:00 AM — 8:15 AM 9.1 The Determination of Causes of Death in a Global Surveillance Network: The DeCoDe Process in the Child Health and Mortality Prevention Surveillance (CHAMPS) Program
Dianna M. Blau, DVM, PhD, Centers for Disease Control and Prevention, Atlanta, Georgia, United States of America
- 8:15 AM — 8:30 AM 9.2 Two Accidental Infant Hyperthermia Deaths in Closets
Erik D. Christensen, MD, Office of the Medical Examiner, Taylorsville, Utah, United States of America
- 8:30 AM — 8:45 AM 9.4 Explained Infant Suffocation Deaths Attributed To Soft Bedding, Overlay, and Wedging
Alexa Baron Erck Lambert, MPH, DB Consulting Group, Contractor for Center for Disease Control and Prevention, New Orleans, Louisiana, United States of America
- 8:45 AM — 9:00 AM 9.5 Sudden Unexplained Death in Childhood: Systematic Analysis of the Hippocampal Landscape
Declan McGuone, MB BCh, Office of Chief Medical Examiner New York City, New York, New York, United States of America
- 9:00 AM — 9:15 AM 9.6 Febrile Seizures and Asphyxial Deaths in Infants and Toddlers with Hippocampal Developmental Abnormalities
Darinka Mileusnic-Polchan, MD, PhD, Knox County Regional Forensic Center, Knoxville, Tennessee, United States of America
- 9:15 AM — 9:30 AM 9.7 CDC's Sudden Unexplained Infant Death Investigation Reporting Form (SUIDIRF)
Carri Cottengim, MA, Centers for Disease Control, Atlanta, Georgia, United States of America
- 9:30 AM — 9:45 AM 9.8 Surveillance of SUID in 16 States and Two Jurisdictions: CDC's SUID Case Registry & Classification System Update
Sharyn Parks Brown, PhD, MPH, Centers for Disease Control and Prevention, Atlanta, Georgia, United States of America
- 9:45 AM — 10:00 AM Questions
- 10:00 AM – 10:30 AM BREAK [NOT CME]
Ballroom Foyer, Main Level
- 10:00 AM – 10:30 AM VISIT POSTERS
North Ballroom, Main Level

- 10:30 AM – 12:00 PM** **SESSION 10: HOT-BLOODED: GENETICS, IDENTIFICATION AND CERTIFICATION**
Moderators: Mario Rascon, El Paso County Office of the Medical Examiner, El Paso, TX, United States of America and Michele T. Stauffenberg, Gwinnett County Medical Examiner, Lawrenceville, GA, United States of America
South Center Ballroom, Main Level
- 10:30 AM — 10:45 AM 10.1 Sudden Unexpected Infant Death Certification in New York City: Intra-agency Guideline Compliance and Variability
Melissa A. Pasquale-Styles, MD, New York City Office Of Chief Medical Examiner, New York, New York, United States of America
- 10:45 AM — 11:00 AM 10.2 Saving DNA Samples and Utilizing Genetics to Investigate Sudden Death in the Young: Lessons Learned From The Sudden Death in the Young (SDY) Case Registry
Heather MacLeod, MS, SDY Case Registry, Elmhurst, Illinois, United States of America
- 11:00 AM — 11:30 AM 10.3 Modernizing the National Vital Statistics System
Katharine K. Lewis, PhD, MSN, MPH, RN, CMS Alliance to Modernize Healthcare, MITRE Corporation, Bedford, Massachusetts, United States of America
- 11:30 AM — 11:45 AM 10.4 The Use of Skeletal Healing and Entomological Observations to Corroborate Lengthy Post Mortem Interval in an Unusual Case Involving Suicidal Evidence in a Mummified body
William C. Rodriguez, PhD, Office of the Chief Medical Examiner, Baltimore, Maryland, United States of America
- 11:45 AM — 12:00 PM 10.5 Warming Up Cold Cases: Recent Fingerprint Initiatives at the FBI Laboratory
Bryan T. Johnson, MSFS, Federal Bureau of Investigation, Quantico, Virginia, United States of America
- 12:00 PM – 2:00 PM** **NAME Luncheon & Award (Registrants and Ticket Holders Only) [NOT CME]**
George E. Gantner, Jr., MD Award Lecture: Forensic Pathology: Current Trends and Future Predictions
Ross E. Zumwalt, MD, will receive the George E. Gantner, Jr., MD Annual Lecturer Award (See Page 36 for Details)
South Forum, Lower Level
- 2:00 PM – 5:00 PM** **SESSION 11: STAYING COOL ON THE SCENE: DEATH INVESTIGATION**
Moderators: Edward A. Reedy, Alabama Department of Forensic Sciences, Montgomery, AL, United States of America and Christopher Milroy, The Ottawa Hospital, Division of Anatomic Pathology, Ottawa, Ontario, Canada
South Center Ballroom, Main Level
- 2:00 PM — 3:00 PM 11.1 Sudden Death During Resistance to Law Enforcement Restraint
Steven B. Karch, MD, Retired, Berkeley, California, United States of America
- 3:00 PM — 3:30 PM 11.2 Disputed Suicides: Investigation and Response by the Medical Examiner's Office
Wendy M. Gunther, MD, Office of the Chief Medical Examiner, Commonwealth of Virginia, Norfolk, Virginia, United States of America
- 3:30 PM — 3:45 PM 11.3 Strengthening Medicolegal Death Investigation Data Systems Through Consistent Data Elements and Interfaces
Paula A. Braun, MS, Centers for Disease Control and Prevention, Hyattsville, Maryland, United States of America
- 3:45 PM — 4:00 PM 11.4 Medicolegal Death Investigator Curriculum Standards Update
Steven C. Clark, PhD, Occupational Research and Assessment, Big Rapids, Michigan, United States of America

- 4:00 PM — 4:15 PM 11.6 Death Scene Investigations after Natural Disasters and Other Weather-Related Events: A Newly Developed Toolkit
Sarah Hodge, MPH, NORC at the University of Chicago, Bethesda, Maryland, United States of America
- 4:15 PM — 4:30 PM 11.7 Modern Faces of Death: Considerations of Death Investigation in Today's Social Media Landscape
Daniel S. Atherton, MD, University of Alabama at Birmingham, Birmingham, Alabama, United States of America
- 4:30 PM – 4:45 PM Questions
- 4:45 PM Meeting Adjourns

POSTER PRESENTATIONS:

Please note posters P1-P40 must be on the assigned board by Saturday, October 14 at 12:00 PM and remain posted until Sunday, October 15 at 3:00 PM. Posters P41-P76 must be on the assigned board by Monday, October 15 at 12:00 PM and remain posted until 2:00 PM Tuesday, October 16.

It is required that presenters are to stand by their posters during the presentation time for discussion of their posters with meeting attendees that will occur:

- P1 – P40: Sunday, October 15, 12:00 PM – 1:00 PM
P41 – P76: Monday, October 16, 12:00 PM – 1:00 PM

P1 Detection of Methanol in a Subdural Hematoma after Embalming

**Benjamin E. Criss, DO, University of Cincinnati, Cincinnati, Ohio, United States of America*

P2 Public Transportation Deaths in Chicago from 2014 to 2016

**Michael D. Eckhardt, MD, Cook County Medical Examiner, Chicago, Illinois, United States of America*

P3 Fatal Bioprosthetic Root Fungal Endocarditis in a 14-Year-Old Girl

**Jeremy D. Berg, MD, USD Sanford School of Medicine, Sioux Falls, South Dakota, United States of America*

P4 Peculiar Patterns of High-Voltage Electrocutions

**Ashley Renee Perkins, DO, MS, University of South Florida, Tampa, Florida, United States of America*

P5 Death Due to Chikungunya - Forensic Case Report

**Wenxue Xing, MD, Department of Medical Examiner-Coroner Los Angeles, Los Angeles, California, United States of America*

P6 Sudden Cardiac Death While Scuba Diving: Hypertrophic Cardiomyopathy and the Importance of Histologic Evaluation in Cases with Subtle or Absent Cardiac Hypertrophy

**Leah M. Schuppener, DO, University of Wisconsin-Madison Hospital and Clinics, Madison, Wisconsin, United States of America*

P7 Farm Machine Related Deaths in Alberta from 2000 - 2015

**Joseph Anthony Andrews, MD, University of Alberta, Edmonton, Alberta, Canada*

P8 Death Related to Fistulas Involving the Gastrointestinal and Cardiovascular Systems

****Allan Joseph Medwick, EdD, MGA, MSED, BA, Western Michigan University Homer Stryker MD School of Medicine, Kalamazoo, Michigan, United States of America*

P9 Sarcoidosis Deaths in Wayne County, Michigan: A 20-year Retrospective Study

**Milad Webb, MD, PhD, University of Michigan, Ann Arbor, Michigan, United States of America*

P10 Spontaneous Hepatic Rupture in a Pregnant Woman with Preeclampsia: An Autopsy Case

***Ji Hye Park, MD, National Forensic Service Gwangju Institute, Jangseong, , Korea, Republic of*

P11 Unknown Cause of Recurrent Metabolic Acidosis Diagnosed by Autopsy

**Michael H. Schild, DO, Duke University Medical Center, Durham, North Carolina, United States of America*

P12 The Fungus Among Us: A Fatal Case of Invasive Aspergillosis in a Non-Transplant Patient

**Stacey Reed, DO, Allegheny General Hospital, Pittsburgh, Pennsylvania, United States of America*

P13 Sudden Cardiac Death in the Young: A Case-Based Discussion

**Sarah C. Thomas, MD, MS, University of South Florida, Tampa, Florida, United States of America*

P14 Healed Fracture of Superior Horn of Thyroid Cartilage in Autoerotic Asphyxia: An Indication of Prior Activity? A Case Report Utilizing 3D Scanning and Printing of the Larynx

**Michael Eckhardt, MD, Northshore University Health System, Evanston, Illinois, United States of America*

P15 Fat Embolism Syndrome in a Patient with Duchenne Muscular Dystrophy Following Minor Trauma: A Case Report

**Travis J. Danielsen, MD, MS, Southwestern Institute of Forensic Sciences (University of Texas-Southwestern), Dallas, Texas, United States of America*

P16 Fatal Achalasia: A Case of Sudden Death and a Review of the Literature

**Annie M. Laib, MD, University of Cincinnati Medical Center, Cincinnati, Ohio, United States of America*

P17 Opioid Associated Deaths in South Carolina: A Retrospective Review

**Daniel C. Butler, MD, Medical University of South Carolina, Charleston, South Carolina, United States of America*

P18 Migraine, Methamphetamine and Myocardial Infarction Highlight Potential Bias in a Case of Thrombotic Microangiopathy

**Megan R. Lawless, MD, University of Nebraska Medical Center, Omaha, Nebraska, United States of America*

P19 Case Report: Postmortem Hypopyon Associated with *Neisseria meningitidis* Meningitis

***W. Ashton Ennis, MD, Allegheny County Medical Examiner's Office, Pittsburgh, Pennsylvania, United States of America*

P20 Homicide Due to Positional Asphyxia

**Carolina Dominguez, MD, University of South Florida, Tampa, Florida, United States of America*

P21 Abduction, Interrogation, and Violence: A Series of Torture Cases from Medellín, Colombia

**Carolina Dominguez, MD, University of South Florida, Tampa, Florida, United States of America*

P22 Intentional and Forced Lethal Ingestion: A Comparison of Two Acute Cyanide Poisoning Cases in Colombia

**Carolina Dominguez, MD, University of South Florida, Tampa, Florida, United States of America*

P23 Vascular Projectile Embolization

****Jennifer Chao, BS, Western Michigan University Homer Stryker MD School of Medicine, Kalamazoo, Michigan, United States of America*

P24 The Autopsy: An Assessment of Utility at One Institution

***Catherine R. Miller, MD, The University of Texas Medical Branch, Galveston, Texas, United States of America*

P25 Death Following Bilateral Spontaneous Renal Artery Dissection Associated With Fibromuscular Dysplasia: Case Report and Review of the Literature

**Ashley L. Lukefahr, MD, The University of Arizona, Tucson, Arizona, United States of America*

P26 Correlation or Causation? The Role of Benzodiazepines in Combined Drug Deaths with Opioids

****Bryce C. Hoelscher, University of Missouri School of Medicine, Columbia, Missouri, United States of America*

P27 A New Speedball: Methamphetamine and Tapentadol

****Chris R. Cunningham, University of Missouri School of Medicine, Columbia, Missouri, United States of America*

P28 Homicides Disguised as Staged Suicides

****Samuel P. Prahlow, BS, Florida State University, Tallahassee, Florida, United States of America*

P29 Opiates and the Possible Link to Suicide

****Alyssa Lynn Lytle, BS, Plymouth State University Office of Chief Medical Examiner, Concord NH, Plymouth, New Hampshire, United States of America*

P30 A Dry Heat? It's OK We Have Shower to Shower[®] Bath Powder to Conceal the Decomposition Odors and Expedite the Mummification Process

**Heidi L. Reinhard, MD, MS, Penn State Milton S. Hershey Medical Center, Hershey, Pennsylvania, United States of America*

P31 Fatality While Bear Hunting: A Homicide or an Accident?

****Alessandra Spagnolia, University of North Dakota School of Medicine and Health Sciences, Grand Forks, North Dakota, United States of America*

P32 Islet Cell Hyperplasia: A Potential Marker for Androgenic Steroid Use in Bodybuilders

****Jared Weinand, University of North Dakota School of Medicine and Health Sciences, Grand Forks, North Dakota, United States of America*

P33 Acute Subdural Hemorrhage Associated with Both Metastatic Adenocarcinoma of the Dura and Minor Head Trauma: A Case Report and Review of the Literature

****Janet Julson, University of North Dakota School of Medicine and Health Sciences, Grand Forks, North Dakota, United States of America*

P34 An Unusual Case of Sudden Death Due To Subarachnoid Hemorrhage

**Sarah M. Maines, MD, University of Kentucky, Lexington, Kentucky, United States of America*

P35 Get Rich or Die Trying: A Case of Traumatic (Compression) Asphyxia

Corey T. Allard, DO, University of Iowa Hospitals and Clinics, Iowa City, Iowa, United States of America

P36 Large-Scale Computed Tomography Database with Associated Lifestyle and Health Data

Shamsi Daneshvari Berry, PhD, University of Mississippi Medical Center, Madison, Mississippi, United States of America

P37 Severe Lung Injury Associated with A/H1N1pdm09 Infection in the Post-Pandemic Season

Kino Hayashi, MD, Tokyo Medical Examiner's Office, Tokyo, Japan

P38 LifeLink of Georgia's[®] Coroner Referral Program

Charles M. Gammill, BA, LifeLink of Georgia, Norcross, Georgia, United States of America

P39 Dehiscence and Exsanguination of a Healing Surgical Chest Incision Mimicking Traumatic Injury in a Non-Decomposed Person

Jerri McLemore, MD, Wake Forest School of Medicine, Winston Salem, North Carolina, United States of America

P40 Controversial Conclusions: Manner of Death Determination in Fatal Train Collisions

Caroline Pryor, BS, MS, Southern Regional Medical Examiner's Office, Woodbine, New Jersey, United States of America

P41 Drug Immunoassay Testing of Vitreous Fluid as a Surrogate for Urine Testing

Lee Marie Tormos, MD, Medical University of South Carolina, Charleston, South Carolina, United States of America

P42 3,4-Methylenedioxymethamphetamine (MDMA, Ecstasy) Intoxication in a Young Adult with Giant Coronary Aneurysms from Kawasaki Disease

Renee Eigsti, MD, University of Iowa Hospitals and Clinics, Iowa City, Iowa, United States of America

P43 Unsafe Sleep Environments: A Florida Case Series Illustrating the Dangers of Bed Sharing, Soft Bedding, and Prone Positioning

Erika M. Baardsen, DO, University of South Florida-Morsani College of Medicine, Tampa, Florida, United States of America

P44 A Review of 5 Unusual Gunshot Wound Suicides Reflects the Importance of Proper Death Investigation in Determining Manner of Death

Jacquelyn M Wright, MS, Office of The Chief Medical Examiner, Commonwealth of Virginia, Northern District, Manassas, Virginia, United States of America

P45 Evidence at Scene Investigation In Drug-Related Deaths Varies by Neighborhood and Discovering Party.
Christopher Liverman, MD, PhD, University of California San Francisco, San Francisco, California, United States of America

P46 Characterization of Gabapentin-Related Deaths in West Virginia
Marie A. Abate, BS, PharmD, West Virginia University School of Pharmacy, Morgantown, West Virginia, United States of America

P47 Autopsy Case of Nephronophthisis and Fat Overload Syndrome
Raman Baldzizhar, MD, University of Rochester Medical Center, Strong Memorial Hospital, Rochester, New York, United States of America

P48 Nonterrorist-Related Suicide Due to Explosion: A Case Report and Review of the Literature
Shannon M. Crook, MD, University of Kentucky, Lexington, Kentucky, United States of America

P49 Persistent Left Superior Vena Cava as Part of a Wound Path in a Fatal Stabbing
Stephanie L. Stauffer, MD, University of Iowa Hospitals and Clinics, Iowa City, Iowa, United States of America

P50 Suicide by Fire: A Case Report and Review of tThe Literature
Patricia Danielle Pittman, MD,MBA, Duke University Hospital, Durham, North Carolina, United States of America

P51 Turner Syndrome is Another Risk Factor for Aortic Dissection
Allison Edgecombe, MD, Office of the Chief Medical Examiner, Calgary, , Canada

P52 Toxicology Reports – Do They Stand on Their Own, or Fall Flat on Their Asp?
Laura Labay, PhD, NMS Labs, Willow Grove, Pennsylvania, United States of America

P53 Death of a Student Related to Occupational Exposure of Fentanyl
Laura Labay, PhD, NMS Labs, Willow Grove, Pennsylvania, United States of America

P54 Intravaginal Stuffing of Methamphetamine Resulting in Accidental Overdose
Diane C. Peterson, MD, Jackson County Medical Examiner's Office, Kansas City, Missouri, United States of America

P55 Intimate and Familial Murder: Examining Trends in Domestic Violence Homicides in Oklahoma from 2010-2014
Andrea L. Wiens, DO, Oklahoma Office of the Chief Medical Examiner, Tulsa, Oklahoma, United States of America

P56 Suicide by Chop Saw
Elaine Rose Amoresano, MD, University of Vermont Medical Center, Burlington, Vermont, United States of America

P57 Hymen Absence in Prepubertal Girls and Chronic Sexual Abuse: Review of the Literature and a Case Report
Giancarlo Di Vella, MD, PhD, Università degli Studi di Torino - Italy, Torino, , Italy

P58 Two Cases of Deaths by Boiling in Japanese-style Bathtubs
Sakurako Iwadate, MD, Kyorin university, Tokyo, Japan

P59 When Spirituality Leads to Death: Case of Ascetic Fasting and Autopsy Findings
Giancarlo Di Vella, MD, PhD, Università degli Studi di Torino - Italy, Torino, Italy

P60 Pharmaceutical Tablet Excipients in a Placenta: Sign of Intravenous Abuse or Contamination?
David K. Arboe, MD, Oklahoma Office of the Chief Medical Examiner, Eastern Division, Tulsa, Oklahoma, United States of America

P61 A 6-Year-Old Child Dead ilnto a Locked Car: A Case Report
Luisa Andrello, MD, PhD, Medicolegal service of Canton Ticino - Switzerland, bellinzona, , Switzerland

P62 Sudden Death in Pregnancy: A Fatal Case of Acute Chorioamnionitis
Allecia M. Wilson, MD, University of Michigan, Ann Arbor, Michigan, United States of America

P63 A Suicide Involving Multiple Gunshot Wounds: Importance of Correlation of Thorough Scene Investigation and Autopsy Findings in Determining Manner of Death
Phinon PhillipsBeckham, BS, MFS, Office of the Chief Medical Examiner - Northern District, Manassas, Virginia, United States of America

P64 All Tied Up: How a Good Death Investigation Turned a Possible Homicide into an Unusual Natural Death
Amanda Spencer, DO, Penn State Hershey Medical Center, Hershey, Pennsylvania, United States of America

P65 The Role of Mitragynine in Two Postmortem Investigations
Meredith A. Frank, MD, Denver Office of the Medical Examiner, Denver, Colorado, United States of America

P66 WITHDRAWN

P67 Causes of Mesenteric Ischemia at Autopsy: the Importance of Histologic Examination
Noelia Alemar Hernandez, NYU Langone Medical Center, New York, New York, United States of America

P68 Cirrhosis and Emphysematous Change in a 12-Month Old Male Infant
Derek S. Bumgarner, MD, Loyola University Medical Center, Maywood, Illinois, United States of America

P69 Not Another Drug Overdose
Mary E. Pietrangelo, MD, Macomb County Medical Examiner's Office, Mount Clemens, Michigan, United States of America

P70 Hemopericardium Complicating Pacemaker Implantation
Ken Obenson, MD, Saint John Regional Hospital, Saint John, New Brunswick, Canada

P71 Rapid Screening for Drugs of Abuse Using Different Bodily Fluids Using a Workplace Urinary Preliminary Screening Test
Ellen Moffatt, MD, San Francisco Office of the Chief Medical Examiner, San Francisco, California, United States of America

P72 Drug-related Hypersensitivity Reactions and the Autopsy
Nicholas Joseph Barna, MD, New York University Medical Center, New York, New York, United States of America

P73 Type IV Glycogen Storage Disorder (Andersen Disease) in an 8-Week Old Infant
Ben J. Murie, DO, Penn State Hershey Medical Center, Hershey, Pennsylvania, United States of America

P74 Dismemberment by Chainsaw: A Case Report
Andrea L. Wiens, DO, Oklahoma Office of the Chief Medical Examiner, Tulsa, Oklahoma, United States of America

P75 Malignant Asphyxia Due to Laryngeal Adenosquamous Carcinoma: A Case Report
Kendra L. Palmer, MD, University of Iowa Hospitals and Clinics, Iowa City, Iowa, United States of America

P76 Mixed Drug Intoxication In A Patient With Tracheobronchopathia Osteochondroplastica (TPO)
Neha Dhungana, MD, University of Iowa Hospitals and Clinics, Iowa City, Iowa, United States of America

NOTES

Exhibit Schedule

Exhibit Installation

Friday, October 13 10:00AM - 4:00PM

Exhibitor Registration Open

Friday, October 13 10:00AM – 4:00PM
Saturday, October 14 7:00AM – 5:00PM
Sunday, October 15 7:00AM – 12:30PM
Monday, October 16 7:00AM – 5:00PM

Exhibit Dates and Overall Hours

Friday, October 13 4:30PM - 6:30PM
(Exhibits Open during Welcoming Reception and Dinner)
Saturday, October 14 6:45AM - 4:00PM
Sunday, October 15 6:45AM – 10:45AM
Monday, October 16 6:45AM - 4:00PM

Please note: You are only required to be at your booth during designated break times as noted in the Meeting Program and below; however the hall will be open during the above hours. This year breakfast will be served for ALL attendees (Including exhibitors) in the Exhibit Hall.

Published Visiting Hours

Friday, October 13 5:30PM – 9:00PM
Saturday, October 14 10:00AM – 10:30AM
3:30PM – 4:00PM
Sunday, October 15 10:15AM – 10:45AM
Monday, October 16 9:50AM – 10:20AM
3:30PM – 4:00PM

Exhibit Dismantling

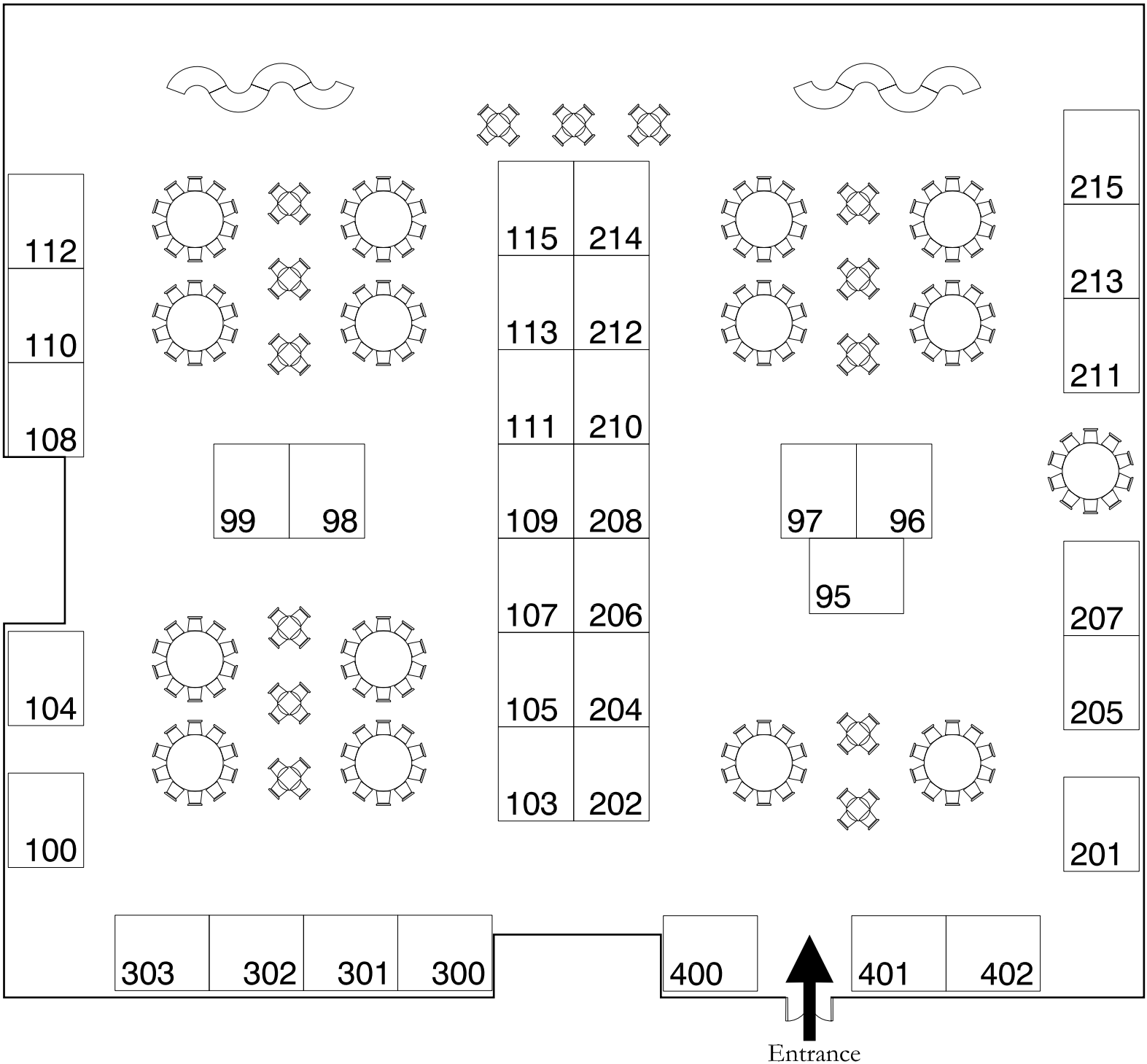
Monday, October 16 4:00PM – 9:00PM

**No packing or dismantling of exhibits will be permitted until 4:00PM, Monday, October 16. Early departure will result in the company or group being penalized a fee no less than \$500 and may result in being prohibited from participating in future NAME events.*

National Association of Medical Examiners

October 13-17, 2017

Doubletree Resort Paradise Valley - Forum Ballroom - South & West
Scottsdale, Arizona



EXHIBITOR DESCRIPTIONS

ADVANCED DETECTION SOLUTIONS (BOOTH # 402)

OFX™ - High-quality, whole-body, multiple projection radiographs in under a minute. Some of OFX™ unique imaging features are as follows: Automated single-push operation, whole body, non-stitched, simultaneous dual view (0° and 90°), high resolution and bariatric friendly. Max body width / height: 43" / 82.7". Body aperture (W x H): 43" x 39.5". Cabin offered to provide radiology room protection.

For more information visit: www.detection-solutions.com

AMERICAN ASSOCIATION OF TISSUE BANKS (BOOTH # 208)

The American Association of Tissue Banks (AATB) is a professional, non-profit, scientific and educational organization. It is the only national tissue banking organization in the United States, and its membership totals more than 130 accredited tissue banks and 2,000 individual members. These banks recover tissue from more than 30,000 donors and distribute in excess of two million allografts for more than 30,000 donors and distribute in excess of two million allografts for more than 1.75 million tissue transplants performed annually in the U.S. Read more here:

www.aatb.org

For more information visit: www.aatb.org

ANAB (BOOTH # 211)

ANAB is the leader for independent third-party accreditation of forensic agencies. ANAB follows all international guidance documents related to ISO/IEC 17025 and ISO/IEC 17020 and uses ILAC G19 in its entirety. ANAB is the longest established provider of accreditation based on ISO standards for forensic testing agencies in the United States, ANAB accredited the first U.S. testing agency to ISO/IEC 17025 in 1999 and the first U.S. forensic crime laboratory to ISO/IEC 17025 in 2001, ANAB and the National Association of Medical Examiners (NAME) have formed a strategic alliance whereby ANAB will administer the NAME accreditation program on behalf of NAME. While NAME accreditation program will be unchanged, each medicolegal office accredited by NAME or seeking NAME accreditation will now also have the opportunity to become accredited to ISO/IEC 17020, the international standard for inspection bodies.

For more information visit: www.anab.org

ASSOCIATION OF ORGAN PROCUREMENT ORGANIZATIONS (BOOTH # 400)

The Association of Organ Procurement Organizations (AOPO) is a non-profit, national organization representing all federally-designated organ procurement organizations (OPOs). The association represents and serves OPOs through advocacy, support and the development of activities that will maximize the availability of organs and tissues and enhance the quality, effectiveness and integrity of the donation process. OPOs are federally-designated non-profit organizations that are responsible for coordinating organ and tissue donation across the United States, bridging the gap between the generous donation of organs and tissues and the thousands in need of these gifts.

For more information visit: www.aopo.org

AUTISM BRAIN NET (BOOTH # 202)

Autism BrainNet is a collaboration of 4 research institutions and the NIH NeuroBioBank created to increase the number of brains available for research. The mission is to create a partnership between the scientific, medical examiner, autism and organ donor communities to develop a sensitive, transparent, and effective strategy for acquiring and distributing the highest quality brain tissue for research worldwide.

For more information visit: www.takesbrains.org

AXIS FORENSIC TOXICOLOGY, INC

Axis for Toxicology (Axis) has been providing forensic toxicology testing and litigation services since 1990 for reference labs, pathologists, medical examiners, coroners, hospitals, law enforcement, sexual assault centers, crime labs, courts of law and attorneys. We are a leader in research and development for designer drug testing and non-routine analysis. Axis Forensic Toxicology is ISO registered. American Board of Forensic Toxicology (ABTF) accredited, and College of American Pathologists (CAP) accredited. www.axisfortox.com. 317-759-4TOX

For more information visit: www.axisfortox.com

BODY SCOOP by B-MOBILE (BOOTH # 303)

The Body Scoop with a 1000 # lift motor on a room covering system, allows a person of any size and strength to make transfers without assistance. The Body Scoop slips under the body with minimal effort.

For more information visit: www.bodyscoop.net

CSI/JEWETT (BOOTH # 112)

For more than 150 years, CSI/Jewett has developed equipment an extensive line of Morgue, Autopsy and Laboratory Equipment. CSI/Jewett provides an integrated system of equipment to enhance work flow, improve space utilization and maximize the efficiency and ease of cadaver handling. From fast and efficient high-volume processing, to customized traditional installations, CSI/Jewett has the best equipment and technical support to meet your needs. For more information visit: www.csi-jewett.com

DODGE COMPANY (BOOTH # 213)

Dodge carries a complete line of embalming chemicals, instruments, safety equipment, protective attire, disinfectants, cosmetics, urns, cremation supplies, Holsag Chairs, InSight Books & Capture Bead Keepsakes. Dodge also offers custom canvas portraits and no cost funeral home web sites. Please register for our web store. www.dodgeco.com or call us: 800-443-6343. For more information visit: www.dodgeco.com

ELITE ALUMINUM CORPORATION (FORTSUSA) (REGISTRATION AREA AND PARKING AREA)

For more information visit: www.footsusa.com

FORENSIC ADVANTAGE SYSTEMS (BOOTH # 108)

Forensic Advantage ® Systems provides innovative, easy-to-use solutions that optimize how medical examiners and coroner offices manage their daily work. Products include Forensic Advantage ® for case management and Incident Response 360 for field investigators and mass casualties. On premise and cloud based options provide flexibility and efficiency of customer implementations. For more information visit: www.forensicadvantage.com

JUSTICETRAX, INC. (BOOTH # 100)

For more information visit: www.justicetrax.com

KUBTEC (BOOTH # 96)

Portable and cabinet x-ray systems for forensics. Portable digital x-ray systems with up to 150 kV for the autopsy suite. DR deflectors with 100 micron resolution. Cabinet systems that support detectors up to 17 X 17 inches with up to 5 micron resolution. For more information visit: www.kubtec.com/forensics

LIFENET HEALTH (BOOTH # 107)

LifeNet Health helps save lives, restore health, and give hope to thousands of patients each year. We are the world's most trusted provider of transplant solutions from organ procurement to new innovations in bio-implant technologies and cellular therapies- a leader in the field of regenerative medicine, while always honoring the donors and healthcare professionals that allow the healing process. For more information visit: www.lifenethealth.org

LIFESIGN (BOOTH # 204)

LifeSign is a medical diagnostics company delivering rapid point of care testing products to caregivers in critical care, physicians' offices, criminal justice and more. Lifesign's line of products is used worldwide for the detection of Infectious Disease, Women's Health, Drugs of Abuse and Cardiac Markers. Our products are developed and manufactured in the USA under ISO, FDA, CGMP and CE Guidelines. For more information visit: www.lifesignmed.com

LODOX SYSTEMS (BOOTH #s 201/205/207)

Full-body,high-speed digital radiology with low radiation emission and scatter. Lodox provides a time-saving, low-dose investigation of the entire body in less than 5 minutes. Institutions across the U.S. and around the world benefit in multiple applications such as major trauma centers, ERs, mass casualty, pediatric imaging, bariatric imaging, bone scans and forensic medical investigations. For more information visit: www.lodox.com

MOPEC (BOOTH # 206)

Mopec provides American-made equipment and laboratory products to the pathology, histology, autopsy and mortuary industries. Founded in 1992, Mopec solutions are among the very best as demonstrated by the vast number of installations in America's top healthcare institutions and facilities. Our reputation, which continues to grow worldwide, is built on decades of superior customer service specializing in consultation and customization. For more information visit: www.mopec.com

MORTECH MANUFACTURING (BOOTH # 300)

Mortech has been manufacturing, designing and installing, quality equipment for over 30 years. We have been family owned and operated since 1985. Mortech offers stationary and elevating pathology grossing stations with a variety of accessories and features to make it your own. At Mortech, we strive for customer satisfaction. From standard units to custom fabrication Mortech is a leader in our field. We fabricate our equipment and we proudly display made in the USA. We are ISO certified and we are also UL and CE listed. With Mortech, The Quality Goes In Before The Name Goes On.

For more information visit: www.mortechmfg.com

MORTUARY RESPONSE SOLUTIONS (BOOTH # 111)

Mortuary Response Solutions (MRS) is the leading manufacturer of mass fatality response equipment which includes the patented Mortuary Enhanced Remains Colling System (MERCSystem), complete portable morgue facilities, identification and processing equipment and complete mass fatality response solutions. MRS also manufactures custom morgue, command post and equipment trailers and vehicles through our parent company, Trailerlogic, LLC. MRS is pleased to offer custom least-to-own mass fatality deployment packages which include but are not limited to the following: refrigeration and storage capabilities, shelters and necessary equipment along with fully functioning DPMU and an FAC which is housed, maintained and deployed by our staff at a moment's notice 24 hours a day, 7 days a week.

For more information visit: www.wwdrq.com

MWL ARCHITECTS (MCCLAREN, WILSON & LAWRIE, INC.) (BOOTH # 109)

McClaren, Wilson & Lawrie, Inc. is a leader in architecture specializing in the forensic sciences and law enforcement with more projects worldwide, in its field of expertise, than any other firm. MWL has designed facilities as large as 665,000SF to smaller facilities repurposed from existing structures. Planning Your Future-Right From the Start

For more information visit: www.mwlarchitects.com

NATIONAL CENTER FOR HEALTH STATISTICS (BOOTH # 99)

For more information visit: <https://www.cdc.gov/nchs/>

NATIONAL DISEASE RESEARCH INTERCHANGE (BOOTH # 105)

The National Disease Research Interchange (NDRI) is a 501(c)(3) not-for-profit, NIH-funded organization that provides project-driven human biospecimen service to academic and corporate scientists. NDRI has 35 years of experience globally distributing human biospecimens for research. Our extensive recovery network has the expertise to provide anatomical structures, organs, and tissues with annotated data.

For more information visit: www.ndriresource.org

NATIONAL INSTITUTE OF JUSTICE (BOOTH # 98)

The National Disease Research Interchange (NDRI) is a 501(c)(3) not-for-profit, NIH-funded organization that provides project-driven human biospecimen service to academic and corporate scientists. NDRI has 35 years of experience globally distributing human biospecimens for research. Our extensive recovery network has the expertise to provide anatomical structures, organs, and tissues with annotated data.

For more information visit: www.ndriresource.org

NMS LABS (BOOTH # 115)

NMS Labs is the leading independent provider of clinical and forensic toxicology and criminalistics laboratory services for the health care and forensic sciences communities. Since 1970, we have built a reputation as a provider of innovative, first-to-market and hard-to-find testing that has evolved to a broad menu of over 2500 laboratory tests. Customers worldwide have recognized NMS Labs for its world-class, full-service facility and emphasis on research and development. NMS Labs provides superior service by providing expert consultative services and clinical research support. For more information, visit us on the web at www.nmslabs.com

For more information visit: www.nmslabs.com

QUALTRAX (BOOTH # 104)

Founded in 1993, Qualtrax provides a complete compliance software package and works with companies worldwide to assist them with achieving compliance goals. This includes managing documentation, automating key business processes, streamlining training management, and ensuring critical industry regulations are addressed-in real time.

For more information visit: www.qualtrax.com

REGIONAL PATHOLOGY AND AUTOPSY SERVICES (BOOTH # 113)

Regional Pathology and Autopsy Services, Inc. (RPAS) was incorporated in 2009 when a team of dedicated experts who had worked together for 20 years came together. With headquarters in California, RPAS is a multi-state autopsy and pathology services company. We provide complete and forensic autopsies for sheriff-coroner/M.E. Offices, hospitals, law firms, research organizations and families.

For more information visit: www.regional-pathology.com

CRC PRESS, TAYLOR AND FRANCIS GROUP (BOOTH # 301)

CRC PRESS, PART OF THE Taylor and Francis Group, is the premier publisher of textbooks, reference books, and e-books on Criminal Justice. Stop by our booth to view our latest titles on Criminal Justice and take advantage of our conference discount. Also be sure to ask about our special pricing for companies looking to purchase books for their employees. If you are interested in writing a book please stop by the booth to speak with our editors about your idea.

For more information visit: www.crcpress.com

RTI DONOR SERVICES (BOOTH # 212)

RTI Donor Services is a not-for-profit tissue recovery network dedicated to serving donor families and the donation community in perpetuating the circle of life. In addition to offering families the option of tissue donation, RTI Donor Services supports their wishes as a responsible steward of human donated tissue gifts, provides family services, and offers community information and awareness. Visit us at www.rtidonorservices.org.

For more information visit: www.rtidonorservices.org

SAMSUNG NEUROLOGICA (BOOTH # 401)

Neurologica, the healthcare subsidiary of Samsung Electronics, develops and manufactures innovative imaging technologies and is committed to delivering fast, easy and accurate diagnostic solutions to healthcare providers. We are the global headquarters and manufacturer of computed tomography (CT). Our advanced medical technologies are used worldwide in leading healthcare institutions, helping providers enhance patient care, improve patient satisfaction and increase workflow efficiency.

For more information visit: www.neurologica.com

SCIMEDICO, LLC (BOOTH # 215)

Scimedico provides project design, specification, installation and preventative maintenance services for the life sciences. Our solutions address project planning and implementation, related quality of care solutions for laboratory procedures and the ongoing preventative maintenance process. To learn more about our solutions please visit www.scimedico.com/NAME

For more information visit: www.scimedico.com/NAME

STEEL FUSION CLINICAL TOXICOLOGY LABORATORY, LLC (BOOTH # 97)

SteelFusion Clinical Toxicology Laboratory, LLC began in 2014 as a small independent business with its core values based around its highly trained professionals with over 75 years combined experience in the clinical and forensic toxicology setting. SteelFusion prides itself on the highest level of compliance and Quality Control. SteelFusion has developed an innovative protocol that utilizes Oral Fluid for the detection and quantification of illicit and prescription drugs. We pride ourselves on unparalleled turnaround time for Oral Fluid toxicology. Normal turnaround is 24 to 48 hours upon receipt to our laboratory. For more information visit: www.steelfusionlabs.com

THE SADS FOUNDATION (BOOTH # 302)

The SADS Foundation is dedicated to informing the general public, families and medical professionals about the effects of undiagnosed/untreated cardiac arrhythmias and the methods by which death can be prevented.

For more information visit: www.stopSADS.org

THE SUDC FOUNDATION (BOOTH # 210)

The SUDC Foundation's mission is to eliminate the tragedy of sudden and unexplained death in childhood. A centralized resource for sudden death in children, it is dedicated to supporting grieving families by developing support and advocacy programs specific to their needs. It works with families, professionals, and the general public to share accurate information, advance medical research, including the SUDCRRRC, and advocate for issues relative to SUDC.

For more information visit: www.sudc.org

TISSUE TECHNIQUES PATH LABS, LLC (BOOTH # 103)

Tissue Techniques a small but efficient lab offering Histology Services at cost effective pricing. Services are H&E, Special Stains, Immuno's and our newest are nail fungus staining.

For more information visit: www.tissuetechpathology.com

UNIVERSITY OF MARYLAND BRAIN & TISSUE BANK (BOOTH # 110)

The University of Maryland Brain and Tissue Bank and the National Institutes of Health seek to enhance the availability of post-mortem autopsy tissue from individuals with autism. The assistance of medical examiners is sought in identifying deceased individuals with autism. The Bank obtains permission for tissue donation from the next of kin. Medical examiners make autism research possible.

For more information visit: www.btbank.org

VERTIQ SOFTWARE, LLC (BOOTH # 214)

VertiQ has been developing ME case management software for 35 years. CME-V3 is a customizable, integrated application for case and workflow management installable on either in-house or our hosted servers. It is 100% Internet Enabled and Mobile using any web browser that is HTML5 compliant. Responsive design allows viewing from a multitude of devices. New features are always available.

For more information visit: www.vertiq.com

GEORGE E. GANTNER, JR., M.D. ANNUAL LECTURER AWARD



THE NATIONAL ASSOCIATION OF MEDICAL EXAMINERS[®]

This lectureship acknowledges and pays tribute to the contributions made by George E. Gantner, Jr., M.D. to the National Association of Medical Examiners. In 1977, when 11-year old NAME needed to relocate from its second home in Wilmington, Delaware, Dr. George E. Gantner, Jr. was Director of the Division of Forensic and Environmental Pathology at St. Louis University School of Medicine and had just been elected as Secretary/Treasurer of the organization. Dr. Gantner generously offered to oversee NAME activities in St. Louis, Missouri and NAME moved there in 1977 and remained there until 2003.

Dr. Gantner served as NAME's Secretary/Treasurer until his death November 15, 1988, having served as the daily overseer of NAME for more than a decade. He availed himself to NAME and its needs and contributed greatly to this organization. It is in his memory and honor that the George E. Gantner, Jr., M.D. Annual Lecturer Award was established in 1994. Those selected by the Awards Committee to give the lecture and receive the award have made outstanding contributions to the advancement of forensic science and have attained professional recognition and respect as an orator in a professional field.

This year's Gantner Lecturer and Award Recipient, Ross E. Zumwalt, M.D., is an excellent addition to the distinguished group of lecturers.



ROSS E. ZUMWALT, M.D.

Ross E. Zumwalt, MD, Medical Investigator and Professor of Pathology:

BA, Wabash College, Crawfordsville, Indiana; MD, University of Illinois College of Medicine; internship and pathology residency at the Mary Imogene Bassett Hospital, Cooperstown, New York; pathology residency at the Southwestern Medical School, Dallas; forensic fellowship training at the Dallas County Medical Examiner's Office; military service as director of laboratories at the Navy Regional Medical Center in Camp Lejeune, North Carolina. Two years as deputy coroner in Cleveland, Ohio, and six years as deputy coroner in Cincinnati, Ohio, before coming to the Office of the Medical Investigator in 1987. Dr. Zumwalt is certified in anatomic and forensic pathology by the American Board of Pathology. He was a trustee of the American Board of Pathology from 1993 to 2004. Dr. Zumwalt served as Chief Medical Investigator of the State of New Mexico from 1991 through 2014.

Dr. Zumwalt has served as president of the National Association of Medical Examiners and has been a member of the following professional organizations: The National Association of Medical Examiners; The American Academy of Forensic Sciences; College of American Pathologists; American Society of Clinical Pathologists; United States and Canadian Academy of Pathology; American Medical Association; and the American Association for the Advancement of Science. He served on a National Academy of Sciences Committee on Identifying the needs of the Forensic Science Community 2007-2009.

OPTIONAL MEETINGS/ACTIVITIES

OPTIONAL SATURDAY NAME FOUNDATION OUTREACH FUNDRAISER, High Profile Cases – Medicolegal Investigation of the Death of Michael Jackson [NOT CME]

Date: Saturday, October 14, 2017

Time: 8:00 PM to 10:00 PM

Cost: Donation

“High Profile Cases – the Medicolegal Investigation of the Death of Michael Jackson”

Speakers:

- Lakshmanan Sathyavagiswaran, MD, FRCP(C), FACP, FCAP, Professor of Medicine and Pathology at Keck School of Medicine USC
- Christopher Rogers, MS, MD, MBA Chief of Forensic Medicine, Los Angeles County Acting Chief Medical Examiner-Coroner
- Steven Shafer, MD, Professor of Anesthesiology, Perioperative and Pain Medicine at the Stanford University Medical Center

A well-managed public information program is crucial to the medical examiner's reputation and ability to communicate necessary information to the public. Most of the work that forensic professionals do is hidden from the public eye. It is only in widely-publicized cases that the public becomes aware of the details of forensic work. Much of the public perception of forensic work comes from how we handle these cases and how they are portrayed in print, television, or electronic media.

Michael Jackson an internationally known singer and dancer who died at his rented Holmby Hills home at the age of 50. He had been preparing for a series of concerts in London and complained to his doctor, Conrad Murray, of severe insomnia. Dr. Murray administered propofol and other sedatives. The doctor was convicted of involuntary manslaughter.

The presentation will cover the following areas:

- The role of the medical examiner in determining cause and manner of death
- The medical examiner's role in deaths during medical and surgical care
- Understand the importance of the public information officer
- The importance of scene investigation
- Security measures needed for high-profile cases
- The autopsy findings in the Michael Jackson case
- Challenges that the medical examiner faced during testimony
- Role of the “Anesthesia Consultant” at the Medical Examiner office and at Trial.

The event will serve as an outreach fundraiser for the NAME FOUNDATION to help raise scholarship money for Forensic Pathology Fellows, Pathology

Residents, and students to attend and make scientific presentations at the NAME Annual Meeting. As such, attendance at this event will be associated with a small donation and require pre-registration. On-line ticketing and registration will be managed by THE CENTER FOR FORENSIC SCIENCES RESEARCH AND EDUCATION at The Fredric Rieders Family Foundation. Ticket donations are \$10 for students and \$20 for everyone else. NAME members may wish to opt for a special package deal: with a \$50 donation, NAME members will receive a 1 year NAME Foundation Membership and admission to the event. Pre-registration at <https://www.eventbrite.com/e/high-profile-cases-featuring-the-medical-investigation-of-the-death-of-michael-jackson-name-tickets-36271336544> - Space is limited

OPTIONAL SUNDAY 20th RIGOR RUN/WALK [NOT CME]

Date: Sunday, October 15, 2017

Time: 6:30 AM

Cost: \$25.00 per person

The NAME Rigor Run/Walk will be approximately 3 miles. The route will start and end at the meeting hotel. Registrants for the Rigor Run/Walk will receive a terrific t-shirt. Runners and walkers can go to the Sunday morning continental breakfast after returning to the hotel. Note: T-shirts will be available on a first come first serve basis. There will be shirts in sizes S, M, L and XL.

OPTIONAL SUNDAY 23rd ANNUAL CADAVER OPEN GOLF TOURNAMENT [NOT CME]

Date: Sunday, October 15, 2017

Time: 1:00 PM

Cost: \$60.00 per player



The tournament will take place at Camelback Golf Club “Padre Course” in Scottsdale, Arizona. From the mind of world-renowned golf course architect Arthur Hills comes a course that promises an enjoyable and unforgettable golf adventure. The Padre Golf Course in Scottsdale features towering trees, subtle landforms and impressive bunkering to sharpen your game. This 6,903-yard, par 72 design is known for its

strategic layout, challenging water holes, and had its 18th hole voted the best water hole in the state by Arizona Golf Magazine. Fees include: Green fees and carts, score cards and cart assignments, staff to manage and score event and a fourball sleeve for each participant. Club rental is available (Taylor Made), \$45 (2 sleeves of balls). Call 480-905-7981

OPTIONAL LEARN TO LEAD, RISE, AND SHINE FROM THE CHIEFS BREAKFAST [NOT CME]

Date: Monday, October 16, 2017
Time: 7:30 AM – 8:30 AM

“Learn to Lead, Rise, and Shine from the Chiefs Breakfast” open to all NAME members who have a burning question for these respected chiefs: Randy Hanzlick, Mary Ann Sens, and Thomas Andrew. The breakfast is designed to discuss common administrative issues from the prospective of experienced and successful chiefs, based on direct audience questions. Preregistration is required, but there is no separate fee for this breakfast. Those attending will need to retrieve breakfast from the main breakfast buffet area and transport it to the meeting room.

OPTIONAL FEMME FATALE LUNCHEON [NOT CME]

Date: Monday, October 16, 2017
Time: 12:00 PM – 1:20 PM

Cost: \$65.00 per person
Femme Fatales (Ladies) - Plan to join your forensic colleagues for lunch and get acquainted. This is a luncheon for all forensic femme fatales! Register early as space is limited!

OPTIONAL YOGA BY DONATION [NOT CME]

Date and Time: Sunday, October 15, 2017 – 4:30 PM to 5:30 PM

Cost: Donation, to go to the NAME Foundation. A suggested \$10 donation per class
Dr. Amy Martin will be leading donation yoga outdoors on the Doubletree Paradise Valley resort, Scottsdale Arizona located at the Health Club. The morning Saturday and Monday classes will be alignment flow classes while the Sunday afternoon class will be a slow flow/gentle yoga. Dr. Martin is a RYT-200 certified yoga teacher. No experience necessary. Please bring your own mat if possible.

NOTES



National Association of Medical Examiners

Abstracts of the 2017 Annual Meeting

October 13 – 17, 2017

DoubleTree Resort by Hilton Paradise Valley-Scottsdale,

Scottsdale, Arizona

NOTES

National Association of Medical Examiners

Abstracts of the 2017 Annual Meeting

October 13-17, 2017

DoubleTree Resort y Hilton Paradise Valley-Scottsdale, Scottsdale, Arizona

ORAL PRESENTATIONS

1.1 The National Institute of Justice's Medical Examiner – Coroner Program

L. Schaeffer

National Institute of Justice/United States Department of Justice, Washington, District of Columbia, USA

National Science and Technology Council's Fast-Track Action Committee on Strengthening the Medicolegal-Death-Investigation System's (FTAC-SMDIS) report titled Strengthening the Medicolegal-Death-Investigation System: Improving Data Systems notes that death investigations performed by ME/C offices are vital to criminal justice by investigating violent deaths. Of the estimated 2.6 million deaths annually, ME/C offices investigate nearly 500,000 cases in approximately 2,400 jurisdictions. FTAC-SMDIS found that the ME/C community lacks adequate personnel and resources to address the country's medicolegal death investigation (MDI) needs. In addition, FTAC-SMDIS reports that there are systemic issues with death investigation data quality and infrastructure, inadequate facilities, and inconsistent expertise levels.¹ Other reports such as the 2009 National Academy of Sciences Report, Strengthening Forensic Science in the United States: A Path Forward have also asserted a need to address deficient facilities, equipment, staffing, education, and training for MDI.

In support of the Medical Examiner – Coroner system, NIJ introduced a new solicitation for the 2017 Fiscal Year entitled, *Strengthening the Medical Examiner – Coroner System Program* (ME/C program). The ME/C program is competitive and designed to support the enhancement of MDI services and increase the supply of forensic pathologists nationwide. NIJ accepted proposals in two purpose areas:

Purpose Area 1: Forensic Pathology Fellowships

Purpose Area 2: Medical Examiner-Coroner Office Accreditation

This presentation will provide a discussion of the initial offering of the ME/C program and what we have learned from the first year, as well as the opportunity for the community to learn more about NIJ's efforts to support the ME/Coroner system.

1.2 The Forensic Pathologist and the Trauma Surgeon

C. Rogers¹, E. Benjamin², B.J. Eastridge³, T.T. Noguchi², D. Demetriades², L. Sathyavagiswaran²

¹Los Angeles County Medical Examiner-Coroner, Los Angeles, California, USA; ²University of Southern California Keck School of Medicine, Los Angeles, California, USA; ³University of Texas at San Antonio, San Antonio, Texas, USA

The medical examiner contributes extensively to the care of the living through the justice system, health care, public health, and organ and tissue procurement in accordance with the law and accepted medical practice. The goal of participation in organ and tissue procurement was to insure a balance between protecting the integrity of the medical examiner's inquiry into cause and manner of death while increasing the supply of organs and tissues for transplantation.

For many years, Los Angeles County Coroner has collaborated with the Trauma Center at LAC+USC Medical Center to provide data on trauma patients who do not survive. In addition to providing autopsy reports, this interaction helps Trauma physicians to assess acts of commission and omission during treatment with a goal of improving patient outcome.

The Coroner assists the Trauma Center in four ways:

1. The Coroner does expedited complete autopsies on cases that the Trauma Center designates as high priority. In most cases, the trauma surgeons ask the forensic pathologist to focus on specific areas of interest in the autopsy. A dedicated senior forensic pathologist is assigned to liaison with the Trauma Center coordinator.
2. The autopsy surgeon fills out a preliminary draft of the Abbreviated Injury Scale (AIS), which is a coding system designed to determine the severity of the trauma. This scale includes items that are not always described in the autopsy report, such as the length and depth of a laceration. By having the pathologist fill out the AIS document, the trauma coder gets a more accurate idea of the severity of the trauma and the trauma surgeons can accurately calculate the probability of survival.
3. The AIS documents are transmitted to the Trauma Center on the date of the autopsy. This provides rapid feedback without having to wait until the autopsy report is completed.
4. A Coroner's representative attends monthly quality assurance rounds at the Trauma Center to provide feedback and improve the quality of trauma patient care.
5. The Trauma Center and the Coroner have collaborated in research.

1.3 NamUs: The National Missing & Unidentified Persons System

D. Driscoll

National Missing & Unidentified Persons System (NamUs), Fort Worth, Texas, USA

With there being close to 4,400 unidentified human remains cases every year and close to 100,000 active missing persons cases on any given day, the nation needed a central repository for case management. The National Institute of Justice held multiple strategy meetings to help find a solution, which later led to the creation of NamUs. NamUs is the first national repository for missing persons and unidentified decedent records accessible to law enforcement agencies, medical examiners, coroners and the public. It is a one stop shop where anyone involved and touched by a missing person case can go for information.

Without cooperation from both sides of the equation, these cases can remain unsolved for many years. As NamUs slowly becomes more a household name, more agencies are reaching out to the NIJ program to help with the much needed forensic and analytical resources that are offered at no cost. A recent partnership between NamUs and the Federal Bureau of Investigation has led to the successful identification of over 100 unidentified persons through fingerprints, which included multiple cold cases and homicides. Because of this, many families will be able to finally bring their loved ones home.

As the forensic resources continue to advance and the partnerships continue to grow, NamUs continues to be a national middle man bridging the gap between the medical examiners and law enforcement communities, helping to make sure each case is at its maximum potential for solvability. The continued cooperation between the medical examiner and coroner community is extremely critical in order to solve these cases.

1.4 Updates on the National Violent Death Reporting System (NVDRS)

K.A. Fowler, J.M. Blair, E. Petrosky, A.E. Crosby
Centers for Disease Control and Prevention, Atlanta, Georgia, USA
The Centers for Disease Control and Prevention's (CDC) National Violent Death Reporting System (NVDRS) collects data on violent deaths occurring in participating states. The NVDRS is currently in 40 states, the District of Columbia (D.C.), and Puerto Rico. The system links information from death certificates, coroners/medical examiner reports, and law enforcement reports and is the most comprehensive violence-related mortality surveillance system in existence. The case definition for NVDRS includes homicides, suicides, unintentional firearm deaths, deaths due to legal intervention (excluding executions), and deaths of undetermined intent. NVDRS has made recent technological advances (e.g., conversion to web-based data entry, electronic death certificate import), and continues to grow, having added 8 states, D.C., and Puerto Rico in September 2016. The goal for NVDRS is full national representation. This presentation will describe how NVDRS monitors the occurrence of violent deaths and provide updates on exciting new developments for the system as NVDRS moves toward national coverage. Updates on technological developments, successful uses of NVDRS data, how the system can benefit medical examiners, and opportunities and challenges related to system expansion will be discussed. The presentation will be followed by a short panel discussion that will include NVDRS staff members as well as medical examiner(s) from participating VDRS states. At the end of the session, participants will be able to 1) describe the purpose of and data sources for NVDRS, 2) describe how NVDRS data can benefit medical examiners, 3) describe how NVDRS data are used to inform violence prevention efforts, 4) identify resources that connect public users to NVDRS data, and 5) identify operational challenges and solutions associated with conducting national violence-related mortality surveillance.

2.1 Clarifying ISO/IEC 17020 Accreditation, Don't Kill the Messenger

S.S. Aiken
Spokane County Medical Examiner's Office, Spokane, Washington, USA
International Organization for Standardization (ISO) has developed more than 19,000 international standards. None of these directly address medical examiner offices. ISO/IEC 17020 is a general standard, most applicable of the ISO/IEC standards to medical examiner offices because it pertains to a judgment-based inspection, such as the autopsy. ISO/IEC 17020 does not supplant NAME accreditation, but overlaps it, and primarily provides requirements for a robust quality management system. This international standard has sections to verify that autopsies are performed with impartiality and independence, and that the office has a process for managing complaints. Other requirements include documentation of training of personnel, calibration of equipment, and policy about confidentiality and what information can be placed in the public domain. NAME, along with the American Board of Forensic Toxicology, and the Association of Crime Lab Directors has selected ANSI-ASQ National Accreditation Board (ANAB) as our accrediting body. For NAME, ANAB will administer both traditional (legacy) accreditation and optional ISO 17020 accreditation. NAME still develops, and modifies the legacy accreditation checklist. Accreditation administrative functions are shifted to ANAB, partly because ANAB is a certified "accreditation body", and NAME, being a small organization, lacks resources to be compliant with international standards, such as ISO/IEC 17011 for such "accreditation bodies".

2.2 Developing Competence By Design Training in Forensic Pathology - The Canadian Experience

J.L. Parai, C.M. Milroy
University of Ottawa, Ottawa, Canada

Postgraduate medical education has traditionally been based upon time spent training. However this methodology is being replaced by competency based training which assesses observable outcomes. In Canada, the Royal College of Physicians and Surgeons of Canada is responsible for all postgraduate medical education and has been creating Competence by Design (CBD) training programs for medical disciplines, with Forensic Pathology among the first to be developed. We present the development of CBD for Forensic Pathology that has been completed in Canada.

CBD involves 4 stages of training, with each stage assessed by Entrustable Professional Activities (EPA). This is applicable for all disciplines, but in Forensic Pathology these must be completed in one year. The first stage of training is Transition to Discipline. This is a short phase. This is followed by the Foundation period and Core period, which should occupy the majority of Fellowship. The final short period is Transition to Practice, where the Fellows are expected to act as junior Staff. Entrustable Professional Activities were developed for each stage, such as an ability to perform certain dissections, preparing forensic pathology reports and consulting for the criminal justice system. We present the results of how the program was created. We will outline the differences between the traditional and competency based models of postgraduate education. We will also present examples of Entrustable Professional Activities developed for Forensic Pathology training in Canada and we will discuss the steps planned within the training programs for a successful implementation starting in July 2018. Fellows will continue to sit the examination for Fellowship of the Royal College of Physicians of Canada in Forensic Pathology to complete certification

2.3 "I didn't choose this field because I enjoy talking to families": Best Practices for Communicating with Next of Kin

J.G. Kuntz¹, J. Pinckard²

¹Emory University School of Medicine, Atlanta, Georgia, USA; ²Travis County Medical Examiner's Office, Austin, Texas, USA

For medical examiners, speaking with next of kin (families) is part of the job. While forensic pathologists may be quite comfortable discussing autopsy findings in court, speaking with families can be far more difficult. In court, the forensic pathologist is speaking as a subject matter expert in an objective, matter of fact, and educational manner. When speaking with a family member, the manner of speaking must, in addition to being factual, also be understanding and empathetic. Furthermore, different people receive and react to information differently, and it is important to be able to ascertain and adapt to an individual's needs. Our clinical colleagues have taken a direct approach to both the concept of how to communicate with patients as well as how to teach those concepts to other physicians. Delivering serious news or unexpected results to a living patient can be challenging at best. Evidence in Medical Oncology literature and elsewhere has demonstrated that when this task approached as a medical procedure with a coherent strategy, it can have an important impact on outcomes such as patient satisfaction and decreased patient anxiety and depression. In addition, using such an approach gives clinicians a better sense of confidence and helps them feel better equipped to have these difficult, yet meaningful conversations. Similar parallels can be drawn to the practice of forensic pathology. When the news centers around notification of death and explanations of autopsy findings, and the next of kin is/are also acutely bereaved, the stakes are high. There is very little time, if any, dedicated to communication skills in pathology training, let alone forensic pathology training, yet forensic pathologists perform this task in their daily routine. Participants in this presentation will be able to 1) identify common pitfalls and barriers to good communication, 2) identify best practices for communicating with next of kin, and 3) list and explain the 6 steps for communicating bad or difficult news.

2.4 Facility Simulation Process Modeling

A.M. Denmark, C. Knorr

SmithGroupJJR, Phoenix, Arizona, USA

Medicolegal autopsy facilities are extremely complex in nature. While many factors ultimately impact facility size and cost, a handful have primary impact. In 2013 the Scientific Working Group for Medicolegal Death Investigation (SWGMDI) released a report and recommendations for facilities relating to construction, staffing, and costs. Among other items, this report developed a number of rules of thumb related to service area and the target number of autopsies for that population. The report recommends a range facility elements based on one of two metrics: amount per 1,000 people in the population service area or amount per 1,000 autopsies performed.

Software based modeling enables simulation of process-driven activities across a range of project types. The goal of this exercise is to simulate morgue and autopsy activities in a static diagram to determine how closely the simulated results align with SWGMDI report recommendations. Specifically, this presentation will cover four recommendations of the report that have the greatest impact on facility planning: body storage capacity and number of autopsy stations, forensic pathologists, and autopsy assistants. Results will be analyzed with regard to different service area populations, body storage conditions, and work days.

2.5 Critical Value Reporting and Forensic Pathology: Is it that Critical?

K. Obenson¹, C. Wright²

¹Saint John Regional Hospital - Dalhousie University, Saint John, Canada;

²Saint John Regional Hospital, Saint John, Canada

Background: Critical value reporting is standard practice in clinical and anatomic pathology. While it exists piecemeal in forensic pathology, the absence of consensus among forensic pathologists about what it signifies and whether it is actually required means that guidelines and its integration into single forensic pathology quality management systems is lacking. In other words the events may be triaged and dealt with appropriately but not in an overall strategic way that may reveal systemic problems earlier. Therefore a properly articulated critical value reporting policy must not only define what a critical value is but must also be proven to:

- a - enhance the safety of autopsy personnel and the public, and
- b - enhance the integrity of judicial and law enforcement processes.

Definition: A critical value in forensic pathology may be defined as any fact or finding obtained in the course of a death investigation that is an immediate danger to public safety; may require urgent testing/monitoring of a decedent's relatives; or may substantially change the nature of a death investigation or impact the outcome in a judicial process.

For example the following events should trigger critical value reporting:

- An infectious, explosive, chemical or radiation hazard
- Unexpected or unconfirmed natural disease which will require testing of living relatives
- Unexpected toxicology results or unexpected trauma that may alter the nature of a death investigation or the judicial process such that criminal charges may be filed, modified or withdrawn.

Discussion: Challenges to implementation include the need for stakeholders working within a wide range of government departments to agree on the definition of critical values and the reporting timeframes. Additional challenges include a determination of which personnel maintains the records, where they are maintained, who approves and reviews the policy, on what review cycle and the personnel responsible for enforcing compliance. Regardless, consultation with stakeholders involved in death investigation is imperative when formulating the policy if maximum compliance is the goal. An ideal policy would also have built in safe guards to ensure compliance.

An annual report of such events should be incorporated into the institutions critical value reporting surveillance system. This panoramic perspective will insure that all aspects of the death investigation and report preparation receive continuous close supervision.

Conclusion: A properly defined critical value reporting system that is incorporated into a quality management system, must add to the surveillance necessary to early detection of systemic problems.

2.6 Improving Photomicrographs by Postprocessing Using Open Source Software

W.R. Oliver

Regional Forensic Center, Knoxville, Tennessee, USA

Photomicrographs have become more important in both trial presentation and in publication with the advent of digital cameras and less expensive color printing. Creating good quality photomicrographs requires good data acquisition -- both in the microscope and the camera. While good quality photomicrographic equipment has become less expensive over time, it can still be very expensive, and some photographic system, particularly smartphone-based methods, are difficult to optimize. A pathologist with limited funds may not be able to take optimized photomicrographs. One option is to restore suboptimal images using postprocessing techniques. Photomicrograph image processing has made great strides, driven in large part by confocal and three-dimensional microscopy needs. Many implementations of optimization methods are available for public domain software such as ImageJ or GIMP. This presentation will discuss the most common kinds of image degradation that occur in suboptimal photomicrographic systems. A discussion of simple configuration changes that may improve photomicrographs before acquisition and how to approach restoring images using common postprocessing methods easily available to users without a computer science or image processing background will be presented. This will include correction for anisotropic illumination, chromatic aberration, spherical aberration, color correction, and deblurring. A short discussion of image restoration as opposed to image enhancement and their Daubert implications will be included.

3.1 Parachute Deaths in Southern Arizona

R.M. Cronin¹, D.C. Winston²

¹University of Arizona Honors College, Tucson, Arizona, USA; ²Pima

County Office of the Medical Examiner, Tucson, Arizona, USA

A retrospective study of parachute related deaths in Southern Arizona was conducted by searching the Pima County Office of the Medical Examiner database between 2001 and 2016. This search revealed 24 deaths. The decedents ranged in age 19 to 61 years of age, with a median age of 36 years. Twenty-two of the decedents were male. The racial breakdown was 22 white, 1 Asian and 1 not recorded. The manner of death in all cases was classified as an accident. All deaths were due to multiple blunt force injuries and only one case was found to have no injuries to the head or neck. The most common circumstances were failure of chute deployment (seven), mid-air collisions (three) and becoming entangled with other parachutists (three). Six deaths occurred during military training. Four of the non-military decedents were described as "experienced" parachutists. One case involved a tandem jump team with a survivor. Natural disease was found in four cases with three having moderate coronary artery atherosclerosis. Toxicology was performed in 21 of the deaths with three positives for cannabinoids, two positives for ethanol and one positive for MDMA.

3.2 Carfentanil and Current Opioid Trends in Summit County, Ohio

K. Waite¹, A. Deeken¹, S. Perch², L. Kohler²

¹Summa Health System, Akron, Ohio, USA; ²Summit County Medical Examiner's Office, Akron, Ohio, USA

Akron, Ohio experienced 302 drug overdose calls to EMS in July 2016, with 52 overdose deaths seen at the Summit County ME's Office. 67% of these deaths were later found to be due to carfentanil. Carfentanil is a synthetic opioid that is 10,000 times stronger than morphine and 100 times stronger than fentanyl. Its only approved use is in veterinary medicine, as a large wildlife tranquilizer (elephant, bison, etc). No other fatal drug overdoses in the area were related to carfentanil before July. Summit County was, to our knowledge, the first to detect carfentanil as a cause for drug overdose deaths. The objectives of this study are to identify the current opioid trend in Summit County, as well as the difficulties encountered during toxicology testing.

A retrospective analysis for all drug overdose cases was conducted through the SCMEO database from Jan. 2009 through Dec. 2016. The database collected case number, date of death, age, sex, race, manner of death, location of death, place of residence, cause of death, and the corresponding cases' toxicology results. A specific query was run for carfentanil from Jan. 2016 through Dec. 2016.

The Summit County Medical Examiner's Office uses a urine immunoassay for screening drugs of abuse. The screening tests showed strong positive results, however, when the urine or blood was run on gas chromatography/ mass spectrometry (GS/MS), unidentifiable mass spectra were found. After sending specimens to other forensic toxicology labs, as well as forensic reference labs, an in-house testing method was developed to identify carfentanil at concentrations as low as 1 ng/mL.

There were 140 presumed carfentanil deaths in 2016, with 118 being confirmed so far. Carfentanil overtook fentanyl as the leading cause of opioid overdose deaths. The number of overdose deaths due to carfentanil decreased per month, starting with 35 deaths in both July and August, to 12 in December. The median age was 38, ages ranged from 17 to 64 years. 46% of carfentanil overdose cases were found to have multiple drugs on toxicology.

Around mid-2016, GC/MS carfentanil concentrations decreased, while cases using carfentanil in combination with other drugs increased. Towards the end of 2016 and continuing into 2017 more fentanyl analogs are being seen used in conjunction with low concentrations of carfentanil. The lower concentrations of carfentanil are harder to detect in urine and blood, shifting the testing to residues from paraphernalia on scene, as well as organ tissue.

3.3 Validation of an HCV Rapid Antibody Test in Postmortem Specimens

C.E. Rose¹, A. Hawes²

¹University of TN Graduate School of Medicine, Knoxville, Tennessee, USA; ²Knox County Regional Forensic Center, Knoxville, Tennessee, USA

A rapid, point-of-care test to detect hepatitis C antibodies would be useful for medical examiners and forensic pathologists to confirm a specific etiology of suspected viral hepatitis and for screening decedents for hepatitis C. One such rapid test is OraQuick® HCV Rapid Antibody Test, a single use immunoassay for the qualitative detection of antibodies to hepatitis C virus (anti-HCV antibody) in fingerstick or venipuncture whole blood specimens. It is a simple, manually performed, visually read, CLIA waived immunoassay. However, it has not been evaluated specifically for use in postmortem testing. The purpose of this study is to evaluate the performance of OraQuick® HCV for detection of hepatitis C virus (HCV) using postmortem blood.

We evaluated the performance of OraQuick® HCV rapid test using postmortem blood in comparison with laboratory-based, FDA-approved serum immunoassay. The study population included 51 decedents whose

deaths were investigated under jurisdiction of the Knox and Anderson County Medical Examiner's Office (MEO). Criteria for inclusion were: known or suspected drug use, opioid use, previous overdose, known or suspected history of hepatitis C infection, suspected overdose death, or suspected sudden natural death. Postmortem venipuncture blood samples from each decedent were tested using the OraQuick® HCV rapid antibody test. For comparison, a blood sample from each decedent was submitted for laboratory-based, FDA-approved immunoassay. Of the 51 study cases identified, consent was later withdrawn in 1 case. Of the remaining 50 cases, 1 had insufficient blood for laboratory-based immunoassay (LBI) and 2 had postmortem samples "too viscous" for LBI. Of the remaining 47 cases, the following results were obtained: laboratory-based immunoassay (22 positive, 25 negative); OraQuick® rapid assay (23 positive, 24 negative). Comparing the OraQuick® rapid test result with the LBI as "gold standard", sensitivity for the OraQuick® rapid test was 95.65% and specificity was 96.15% in postmortem blood. However, we identified one definite false negative by LBI (documented history of HCV, histologic chronic active hepatitis, positive OraQuick®). Another had a marginally positive LBI (1.1 with 0.9 being the cutoff for positivity) with a negative OraQuick® result. Of the two cases not tested by LBI due to viscosity, one was OraQuick® positive and had a well-documented history of HCV, and the other had no known history of HCV and was OraQuick® negative.

Preliminary data review indicates the performance of OraQuick® HCV rapid antibody test is comparable, if not superior to, that of laboratory-based tests for hepatitis C antibody in postmortem blood.

3.4 Hyperoxalosis Secondary to Intravenous Vitamin C Administration as a Non-Allopathic Treatment for Cancer

M.A. Giffen, J.L. McLemore

Wake Forest University Baptist Medical Center, Winston Salem, North Carolina, USA

Natural medicine and homeopathic treatment have expanded into an ever greater role in the treatment of patients. Vitamin C (ascorbic acid) has long been known to have antioxidant properties, with associated claims that it can boost the immune system, fight off infection and help in the treatment of cancer. Similar to many other over-the-counter and herbal medicines, even mega-doses of vitamin C can cause potential side effects and interactions with other pharmaceutical medications. We discuss a case of an elderly woman with widely metastatic adenocarcinoma of the lung. She had undergone several rounds of allopathic chemotherapy; however, treatment was stopped because of relative intolerance to the treatment due to poor oral intake, massive weight loss and disease progression. Ultimately she chose to be treated with 10 courses of intravenous vitamin solutions containing vitamin C at a local homeopathic medical center. Five days after the last vitamin C administration she was admitted to an allopathic hospital due to acute renal failure and oliguria of unknown etiology. Work-up revealed elevated calcium oxalate in her urine and hypovolemia secondary to poor oral intake. During her hospital course, she suffered an acute myocardial infarct, which resulted in death. At the time of autopsy, in addition to her widely metastatic adenocarcinoma and myocardial damage, hyperoxalosis of the kidney was present. An ethylene glycol level was negative. Hyperoxalosis of the kidney is a documented phenomenon related to administration of intravenous and oral vitamin C at super-physiologic doses as recommended by some natural and homeopathic practitioners and is, therefore, an important complication of treatment. This case involves a medical therapeutic complication that contributed to death. Deaths due to medical therapeutic complications are in a grey zone whether the medicolegal community should accept jurisdiction and investigate the death. The issue is more complicated when death may result from what would be considered a non-traditional medical treatment.

3.5 What's the Huff? A Review of Seven 1,1-Difluoroethane Fatalities

L.A. Havrilla¹, J.R. Gill²

¹Duke University Medical Center, Durham, North Carolina, USA; ²State of Connecticut Office of the Chief Medical Examiner, Farmington, Connecticut, USA

We present seven deaths involving inhalational abuse of 1,1-difluoroethane, an aerosol propellant commonly found in computer dust cleaners. It is a colorless and odorless gas that when inhaled causes light-headedness, disorientation, and euphoria. Higher concentrations may result in cardiac dysrhythmias and sudden death. Volatile abuse includes sniffing (direct inhalation), huffing (spraying on a cloth and inhaling), and bagging (filling a plastic bag and inhaling it).

During a four year period, the inhalation of 1,1-difluoroethane caused or contributed to seven fatalities. Investigations of the circumstances surrounding the deaths, autopsies, and toxicological analyses were performed. The decedent's ages ranged from 18 to 40 years with a male to female ratio of 3:1. Autopsy findings were nonspecific and included pulmonary edema and congestion. 1,1-Difluoroethane was detected by gas chromatography/mass spectrometry in all seven fatalities with concentrations ranging from 26 mg/L to 330 mg/L. In all but one, the deaths were certified as acute intoxications. In one instance, the death was certified as heart disease with 1,1-difluoroethane as a contributing condition. In the two instances with the lowest concentrations (26 mg/L and 33 mg/L), additional findings that contributed to death were hypertensive and atherosclerotic cardiovascular disease and acute ethanol intoxication (168 mg/dL ethanol). The source of the inhalant was found at the scene in six of the seven deaths. In the one death without scene evidence or a clinical history of aerosol abuse, 1,1-difluoroethane was unexpectedly detected because it is included in the standard drug screen. All seven deaths involved sniffing/huffing.

1,1-Difluoroethane intoxication has also been reported in drivers involved in motor vehicle collisions. In these instances, it may be difficult to locate the inhalational source as the cans may be mixed within the collision debris. Inhalation of 1,1-difluoroethane also has been used to assist with suicide by placing a bag over the head after inhaling or spraying the inhalant into the bag. In these instances, it may be challenging to determine if death is purely due to an intoxication or whether it includes an asphyxial component due to the method of drug administration (e.g., a plastic bag over the head). The inhalant may not always be found at the scene so death investigators should know if 1,1-difluoroethane is included their toxicology laboratory's routine screen. If not, referral labs may be used for detection and quantification.

3.6 Investigation into the Potential for Post-mortem Formation of Carboxyhaemoglobin in Bodies Retrieved from Fires

C.J. Sully¹, N. Langlois¹, S. Walker²

¹Forensic Science South Australia, Adelaide, Australia; ²Flinders University, Adelaide, Australia

The forensic investigation of deceased retrieved from a fire includes determining if death occurred before or during the event. A blood carboxyhaemoglobin level above 10% is considered indicative of respiration during a fire. Previous spectroscopic studies revealed oxygen can passively diffuse into skin and re-oxygenate haemoglobin¹. It was therefore questioned if carbon monoxide could also dermally diffuse and elevate post-mortem blood carboxyhaemoglobin levels, falsely insinuating an individual had been alive and respired during a fire. The aims of this project focused on determining if carbon monoxide could passively diffuse into the body post-mortem and elevate blood carboxyhaemoglobin levels. Following acceptance of notification by Ethics committees, stillborn piglets were exposed to 1% or 10% carbon monoxide. Spectrophotometry revealed carbon monoxide diffused into the dermal layers of skin. Carboxyhaemoglobin was quantified in blood from the heart and chest cavity. Samples from intact bodies were not affected, suggesting skin is a

reasonable carbon monoxide barrier. Piglets with cavity breaches replicating extensive injuries, exposed to carbon monoxide demonstrated cavity carboxyhaemoglobin levels above 10%. These results identified when physical breaches are present in a body elevation in post-mortem carboxyhaemoglobin can occur that could be interpreted as an individual having been alive during a fire event.

3.7 Death Following Liposuction: A Case Series

K.E. Howell, M. Helenowski, K. Escobar Alvarenga, B. Soriano
Cook County Medical Examiner's Office, Chicago, Illinois, USA

Liposuction is the second most common cosmetic surgery in the United States with over 230,000 procedures performed in 2016. It is a procedure generally considered safe, with a low complication rate, and customarily performed on a healthy population. While multiple minor complications have been described, the incidence of death is incompletely assessed and much of the data quoted is over fifteen years old.

A review of the Cook County Medical Examiner's Office database was performed over a one year period October 2015-September 2016 to identify deaths following cosmetic procedures including liposuction. The cases were reviewed to assess incidence and identify common contributing factors.

We identified five deaths that occurred following liposuction. The decedents were all female with an age range of 28 - 42 years. Four decedents underwent additional cosmetic procedures in addition to liposuction immediately prior to demise. Three decedents showed evidence of previous remote surgery at time of autopsy. Two deaths were determined to be secondary to fat emboli, and both of those deaths occurred during the surgical procedure. The remaining deaths all occurred within days of the cosmetic procedure. One decedent died from *Pseudomonas aeruginosa* sepsis after a brief intensive care unit stay. One decedent died from a hydrocodone overdose with contributing liver disease. One was determined to be a sudden unexpected death following a recent surgical procedure after being found dead in her home. Cosmetic surgery procedures are have some of the lowest mortality rates among all surgeries with an estimated incidence of 1/5000 for liposuction. General anesthesia, pulmonary thrombotic and fat emboli, visceral organ perforation, large volume liposuction, and surgery performed in a hospital instead of a surgical center have all been found to contribute to patient mortality. The operative trauma and somewhat blind nature of the procedure in richly vascular tissue are likely additional contributing factors to death following liposuction. A high index of suspicion for fat emboli, sepsis, and other complications of surgery should be entertained when examining a decedent whose death occurred following a liposuction procedure.

3.8 WITHDRAWN

3.9 What is the Manner of Death? Forensic Aspects of Sudden Cardiac Death Events After Significant Emotional Stress. A Case Series.

I. Lesnikova¹, M. Gilliland²

¹Brody School of Medicine, East Carolina University, Greenville, North Carolina, USA; ²Brody School of Medicine, Greenville, North Carolina, USA

Relatively uncommonly seen, the risk of sudden death after emotional stress has been reported since antiquity and incorporated into the folk wisdom, reflected by phrases such as "scared to death" and "broken heart". It is well-known that severe emotional stress is associated with dramatic neuro-endocrine responses activating the sympathetic nervous system, the pituitary-adrenal axis, and the adrenal medulla. These activations result in excess secretion of cortisol and catecholamines reportedly having cardiotoxic and arrhythmogenic effects triggering sudden unexpected cardiac death.

"A Guide for Manner of Death Classification" from the National Association of Medical Examiner home page approved by the NAME Board of Directors in 2002 includes two such scenarios – "28. Deaths resulting from fright..." and "45. Natural deaths occurring during the exertion of intercourse...." The Guidelines were derived from the "Mind Your Manners" paper from 1997 that did not discuss several scenarios, specifically, "7. Surprise party..." in which an elderly man collapsed and died. This case series is intended to provide a peer-reviewed presentation describing scenarios not included in the Guidelines. Other members of the forensic community will have more current literature to cite during discussions of manners in such cases.

This case series includes eight cases of sudden unexpected cardiac death in middle aged men and women after significant stressful event such as: arrest by police, non-injury motor vehicle collision (MVC), armed robbery, being chased down a lonely road followed by a verbal confrontation, fall from wheel chair in a MVC with no injury; involuntary commitment proceeding at a hospital, sexual intercourse, and severe, acute panic attack with breathing problems. All of these people died shortly after the precipitating event, making the causal relationship between stressful event and death undoubtable. In all cases the autopsy examination revealed hypertensive and arteriosclerotic cardiovascular disease. In six cases chronic obstructive pulmonary disease and in three cases diabetes mellitus were identified as the significant contributing conditions. To our knowledge, despite relatively large number of sudden cardiac deaths after significant acute stressful event, there is no uniformity in certification. Most of the published papers regarding stress-associated deaths are from other countries and discuss the psychiatric aspects of such deaths. A detailed analysis helps achieve uniformity and predictability of certification by medical examiners and coroners and improve the predictability of the outcomes of death investigations for the legal system and for families.

3.10 Fatal Hypoxic Ischemic Brain Injury, Cervical Spinal Nerve Root/Ganglia Hemorrhages and Retinal Hemorrhages Associated With Oropharyngeal Pedunculated Polyp in an Infant

E.V. Cook¹, A.G. McDonald², P.E. Lantz²

¹James H. Quillen School of Medicine/East Tennessee State University, Johnson City, Tennessee, USA; ²Wake Forest Baptist Health, Winston Salem, North Carolina, USA

A thorough autopsy is crucial in cases of sudden unexpected death in infants. We report a unique case of fatal hypoxic ischemic brain injury, cerebral edema, spinal nerve root/ganglia hemorrhage and retinal hemorrhages associated with a pedunculated oropharyngeal polyp in an infant. This presentation highlights the need to perform a meticulous examination of the oropharynx, fundal examination and cervical spinal nerve roots and ganglia dissection in unexpected, unexplained infant deaths.

A 12-month-old male infant with no significant medical history was transferred from a local hospital's emergency department due to status epilepticus with diffuse tonic clonic seizures and rightward eye deviation. He was sedated, but vomited several times during intubation and experienced bradycardia. A cranial computed tomography scan showed diffuse cerebral edema with loss of grey/white matter. His pupils became dilated and non-reactive. He died three days following admission. Child abuse was not suspected clinically according to the neurologist and pediatric intensivist.

Autopsy findings were significant for a clinically unsuspected 1.3 x 0.7 cm oropharyngeal, pedunculated fibrovascular polyp arising from the right palatine tonsil that readily occluded the upper airway at the level of the laryngeal inlet. No subscalpular hemorrhage or skull fractures were present but he had marked sutural diastasis from cerebral edema. The brain had diffuse cerebral edema and cerebellar tonsillar herniation; the dura mater had intradural extravasated blood and an adjacent thin veneer of subdural blood. Histologically, the brain exhibited hypoxic ischemic

changes. Postmortem monocular indirect ophthalmoscopy revealed bilateral retinal hemorrhages (left > right). Optic nerve sheath hemorrhages were not present. Cervical spinal nerve root and ganglia hemorrhages were more prominent in the upper cord. There were no injuries identified that caused or contributed to the infant's death. An upper aerodigestive fibrovascular polyp, a rare and benign tumor in infants, may cause asphyxia, seizures and death. This infant suffered a hypoxic ischemic brain injury from a pedunculated oropharyngeal fibrovascular polyp that occluded his airway resulting in hypoxia, seizures, cerebral edema and cerebellar tonsillar herniation. Postmortem fundal examination revealed retinal hemorrhages not clinically suspected. He also had spinal nerve root/ganglia hemorrhages considered by some authors as specific for cervical flexion/extension. This case report highlights the need to perform a careful dissection of the oropharynx in infants who die suddenly and unexpectedly and remain open-minded when findings of retinal hemorrhages and spinal nerve root/ganglia hemorrhages are found in infants at autopsy.

3.11 Characteristics of Fire and Carbon Monoxide Inhalation-Related Homicides in Wayne County, Michigan

K.S. Conway¹, C.J. Schmidt², T.T. Brown²

¹University of Michigan, Ann Arbor, Michigan, USA; ²Office of the Wayne County Medical Examiner, Detroit, Michigan, USA

Fire and carbon monoxide inhalation-related homicides are substantially less common than fire and carbon monoxide inhalation-related accidental deaths or suicides. We examined autopsy and toxicology reports for 42 homicides involving fires and/or carbon monoxide toxicity in Wayne County, Michigan, from 2007 through 2017. Of the decedents, 67% were male, 67% were black, and the mean age was 37.7 years, with 21% under 18 years. The most common circumstances were apartment or house fire (67%), direct ignition of the decedent (19%), and car fire (5%). In 17% of the cases, there was evidence of blunt trauma, stabbing, or a gunshot wound prior to or concurrent with death.

The presence of carboxyhemoglobin was identified in 69% of cases, either from hospital records or postmortem toxicology, with a mean saturation of 46% (range 2% to 91%). The presence of a respiratory depressant was identified in 25% of cases. Among all adult decedents, the mean body mass index (BMI) was 29, the mean heart weight was 469 grams, 42% had a heart weight greater than 95th percentile for weight, and 24% had evidence of coronary artery disease. No significant association was found between carboxyhemoglobin saturation and BMI, heart weight, cardiomegaly, coronary artery disease, or the presence of respiratory depressants. The absence of any such association is most likely due to the small sample size and heterogeneity of circumstances in the cases reviewed.

We categorized causes of death into one or more of three causes: inhalation, including smoke and soot inhalation or carbon monoxide toxicity (62%), burns (48%), and antecedent event, including blunt trauma, stabbing, or gunshot wounds (17%). In 29% of cases, the cause of death was attributed to two of these categories. In cases where inhalation was the sole cause of death, carboxyhemoglobin concentrations were significantly higher than both in cases where inhalation was combined with another cause and in cases where inhalation was not listed as a cause of death (58% vs. 39% vs. 23%, $p = 0.007$). These findings suggest that carboxyhemoglobin levels are useful in determining the degree to which inhalation contributed to the death. In particular, levels of carboxyhemoglobin saturation under 40% are suggestive of a secondary contributing cause, and levels under 30% suggest that inhalation may not have played a primary role in causing death.

3.12 Unusual Suicides: A Florida Case Series

A.R. Perkins¹, C. Dominguez¹, E. Baardsen¹, S. Thomas¹, S.S. Rivers², L. Chrostowski²

¹University of South Florida, Tampa, Florida, USA; ²Hillsborough County Medical Examiner's Office, Tampa, Florida, USA

Florida is well known for its bizarre, headline inciting news stories. The cases that present to the Hillsborough County Medical Examiner's office in Tampa, Florida are often of no exception. Deaths due to intentional self-directed injurious behavior with the intent to die, or suicide, are the 10th leading cause of death in the nation but in Florida, it ranks 8th. Firearms are implicated in the vast majority of these cases, followed by suffocation, including hanging and poisoning. Despite these statistics, occasionally individuals use unusual and complex means to successfully complete their suicide. In some instances, these measures may impede identification of the true manner of their death and prove to be diagnostically challenging. We present several cases that posed these diagnostic dilemmas due to their peculiar death scenes, unique circumstances, and/or unexpected autopsy findings. These cases reflect a variety of causes of death including: a man found with multiple nails in his head from a single-shot nail gun, a man who used a circular saw to cut his throat, a woman that laid on the tracks of an oncoming train, a man found in a sealed bathroom with remnants of burnt charcoal in cooking pots, and a young man found restrained to a bed with a plastic bag over his head, connected to a nitrogen tank. When approaching cases with unusual circumstances, it requires that the entire death investigation team maintain an open-mind, explore every possibility, and closely scrutinize all the evidence in order to establish the true cause and manner of death.

3.13 Common Cause and Manner of Early Death in Autism with Respect to Scene Investigation

J.K. Cone, M. DiStasio, M.P. Anderson

Beth Israel Deaconess Medical Center, Boston, Massachusetts, USA

Autism is a neurodevelopmental disorder affecting social interaction, characterized by repetitive and potentially self-injurious behavior. Only a fraction of autism cases can be tied to specific genetic etiologies. Human brain tissue is vital to investigating neuronal circuit dysfunctions and CNS pathologies producing the behaviors of autism and vital to understanding the multifactorial contributions of genetic, immunologic, infectious, and environmental variables leading to the disorder. Autism BrainNET is a network of brain banking programs that coordinates human brain tissue procurement and distribution to research labs as part of its mission to advance the understanding of autism. Autistic patients are approximately two times more likely than the general population to suffer early mortality, generally linked to a specific subset of natural, accidental, or suicidal manners of death. 20-40% of autistic patients have concurrent epilepsy, to which most natural-cause early deaths are attributable, with 2-17% labeled sudden unexplained death in epilepsy (SUDEP). Morning discovery of the deceased in bed with an otherwise unremarkable scene is common. Accidental-cause early deaths in autism are most commonly linked to drowning or asphyxia. Desertion and wandering behaviors predispose autistic patients to both. In drowning, the patient is often found alone, face down in water, with white, foamy fluid surrounding the mouth and nose. Asphyxia is commonly positional with the patient unable to right him or herself from an oxygen-deprived position. Additionally, autistic patients have a nine times higher suicide rate than the general population. Cases featuring the above characteristics without other obvious external cause of death should trigger a neuropsychiatric history review, emphasizing behavioral predispositions (as in autism) contributing to risky circumstances. As the majority of scene findings in autism-related deaths are non-specific, ruling out other causes of death (namely infectious and overdose) is vital. Culturing blood and cerebrospinal fluid, noting drug use history and performing toxicological workup are useful. Autism BrainNET is forging partnerships with OMEs throughout the United States to further tissue procurement for autism research. OMEs are a unique resource, as

they may be able to recognize a medical history or circumstances of death suggesting autism as a factor in death and alert BrainNET to the case. Additionally, Dr. Anderson, Director of Neuropathology at Harvard Medical School and Beth Israel Deaconess Medical Center, provides clinical neuropathology reports free of charge to the OME. Here we present data from a review of our current brain bank cases that highlights features relevant to death investigation.

3.14 Silicone Pulmonary Emboli Resulting from Illegal Buttock Injections: A Tale of Two Cities

S. Murthy, S. Lenfest

Southwestern Institute of Forensic Sciences, Dallas, Texas, USA

Silicone injections for body modification have existed since the 1970's. However, the United States Food and Drug Administration (FDA) has not approved silicone injections for any augmentation of the body. Despite the risks, illegal injections are appealing because they are far less expensive than conventional plastic surgery. Thus, there is a thriving black market for these injections, predominantly performed by individuals without medical licenses. We present a case of a 34-year-old female who visited a salon in Dallas, Texas for silicone injections into her buttocks. The following morning, she was found unresponsive in the back of the salon and was pronounced dead at the scene. External examination of the decedent revealed needle puncture wounds on both buttocks that were seeping a viscous fluid. Incisions into the buttocks revealed innumerable, variably sized, smooth walled, cystic spaces filled with colorless viscous fluid and dense fibrosis scattered throughout the adipose tissue. Microscopic sections from the buttocks revealed diffuse, chronic foreign body reaction, fibrosis, and cystic spaces. Microscopic sections from the lungs revealed round, non-polarizable, clear spaces within the vasculature, intraparenchymal hemorrhage, and patchy pulmonary edema. Postmortem toxicology was negative for drugs and alcohol. Samples of the left buttock tissue and clear fluid expressed from the tissue were sent to the FDA for analysis. Silicone compounds were identified in both samples. The cause of death was determined to be silicone pulmonary embolism associated with cosmetic silicone injections of the buttocks. The manner of death was ruled a homicide. Approximately 5 months later, a 22-year-old female received silicone injections into her buttocks at a hotel in St. Louis, Missouri. She later died from these injections. Autopsy findings were similar and included needle puncture wounds, cystic spaces within the buttocks tissue, and silicone emboli within the lungs. Samples from this case were also sent to the FDA, confirming the presence of silicone compounds. During the initial investigation of the second case, it was discovered that the two primary suspects were the same two individuals known to be involved with the death in Dallas. The Office of the Medical Examiner in St. Louis consulted with the Southwestern Institute of Forensics in Dallas in order to collaborate on specimen selection, handling, and results.

4.1 Medical Assistance in Dying - Early Experiences in Alberta, Canada

M.L. Weinberg¹, S. Weinberg², J. Andrews³

¹Alberta Office of the Chief Medical Examiner, Edmonton, Canada;

²Virginia Commonwealth University, Richmond, Virginia, USA; ³University of Alberta, Edmonton, Canada

Medical assistance in dying (MAID) is a controversial subject with wide-ranging opinions. While legal in a small number of jurisdictions, it is illegal in most Western nations and was not legal in most of Canada prior to 2015. In February 2015, the Supreme Court of Canada ruled in Carter vs Canada that prohibition against physician-assisted dying violated the Canadian Charter of Rights and Freedoms. In June 2016, the Canadian Parliament passed Bill C-14, legalizing MAID in Canada under specific criteria, including the patient being 18 years old and having a 'grievous and irremediable medical condition that causes enduring and intolerable suffering'. Individual provinces and territories were left to determine the

administration, regulation, and supervision of MAID. In Alberta, MAID cases have occurred since April 2016. We will present how MAID occurs in Alberta, including available protocols and medications used and collective demographic data on patients' underlying medical conditions through August 2017. We will briefly discuss how MAID deaths are certified by the medical examiner staff at the Alberta Office of the Chief Medical Examiner. Preliminary data through February 2017 includes 95 MAID cases, with a near-even gender split. Approximately two-thirds of patients had an underlying diagnosis of some form of cancer and approximately 20% suffered from a degenerative neuromuscular condition (such as multiple sclerosis or amyotrophic lateral sclerosis). Age ranged from 42 to 97 years old. Thus far, all patients have availed themselves of the intravenous route of medication administration. Over the first eleven months of legality, the MAID case rate in Alberta was 24.4 cases per million residents per year.

4.2 The Elephant in the Room: Outbreak of Carfentanil Deaths in Minnesota and the Importance of Multiagency Collaboration

R.M. Wilcoxon¹, O. Middleton¹, S. Meyers¹, J. Kloss², S.A. Love²

¹Hennepin County Medical Examiner's Office, Minneapolis, Minnesota, USA; ²Hennepin County Medical Center, Minneapolis, Minnesota, USA

Carfentanil is a synthetic opioid with a potency 10,000 times that of morphine (and 100 times that of fentanyl) used in veterinary medicine for tranquilizing large animals [1]. It has allegedly been involved as a chemical warfare agent in Russia [2] and recently been implicated in 23 deaths in Ohio in 2016 [3]. Carfentanil is difficult to detect in biologic specimens due to decreased cross reactivity with immunoassays its presences at very low concentrations. Limited reports indicate significant overlap of carfentanil concentrations between fatal (range 0.0107 – 0.535 ng/mL) and non-fatal (range 0.0118 – 0.293 ng/mL) cases [4-5]. Over a 2 month period in early 2017, the Hennepin County Medical Examiner's office investigated 9 apparent opioid toxicity deaths. These deaths occurred in three separate urban, suburban, and rural counties in Minnesota and involved males (5) and females (4), 23-43 years of age, who were known substance abusers. All decedents had reportedly recently used heroin and most were found with drug paraphernalia, including syringes, nearby. Complete autopsies variably showed classic stigmata of opioid overdose (pulmonary edema, foam in the airways, urinary retention) with no significant injury or natural disease to explain death. Initial toxicology screens failed to identify heroin or other narcotic substances and 8 cases were positive for quinine/quinidine in the urine or the blood, a known cutting agent in illicit drugs. Several cases were presumptively positive for fentanyl by immunoassay yet failed to confirm positive for fentanyl. Following American Board of Forensic Toxicology reporting standards, these cases were reported as negative for fentanyl by the laboratory, as carfentanil was not within the scope of testing. Due to the discrepant scene and toxicology findings suggestive of an opioid toxicity death, further discussion between the medical examiners and toxicologists prompted additional testing at a referral laboratory. This resulted in quantifiable blood carfentanil in all cases (mean 0.26 ng/mL, range 0.12 – 0.64 ng/mL). Co-intoxicants included ethanol (2), methamphetamine (3), benzodiazepines (3), and cocaine (1). No case had definitive evidence of acute heroin intoxication, but two cases had low levels of morphine present (0.03 and 0.06 ng/mL), and two others had 6-monoacetyl morphine present in the urine without morphine in the blood, suggesting recent use. All deaths were certified as accidental acute or mixed carfentanil toxicity.

These cases present additional information about carfentanil-related deaths, with postmortem levels higher than previously reported, and highlight the importance of collaboration with forensic toxicologists.

4.3 The Shock of Strep: Rapid Deaths Due to Group A Streptococcus

K. Thompson, A.K. Sterkel, R. Corliss

University of Wisconsin Hospital and Clinics, Madison, Wisconsin, USA

Background:

Streptococcus pyogenes, also known as group A strep, is a gram positive coccus responsible for several million infections every year. The types of infections vary widely from pharyngitis to myositis, but all can advance to severe life threatening invasive disease. Of those infected, approximately 1,100-1,600 people die each year due to invasive disease. Why certain individuals' contract severe infections is not known, but many stains of *Strep. pyogenes* are known to produce toxins that can result in toxic shock. Streptococcal toxic shock syndrome has seen a recent increase in recognition and is considered a reportable disease by the CDC. The purpose of this study is to familiarize pathologists with the pathogenic, gross and histologic characteristics of this disease.

Methods:

A retrospective search of our electronic pathology database PowerPath (Sunquest Informational Systems) as well as our forensic autopsy database was undertaken for deaths related to *Streptococcus pyogenes* (group A) infections between 1994-2017.

Results:

Three autopsies were performed on patients with invasive group A streptococcal infections at the University of Wisconsin Hospital and Clinics between 1994-2017.

Case 1

A 37 year old women with Klippel-Trenaunay-Weber syndrome presented three days before death with swollen, red legs and hyperthermia after stubbing her left great toe. She subsequently developed acute respiratory distress, end organ damage and expired. At autopsy she showed mild pulmonary edema, severe hepatic necrosis, and erythema of the left great toe.

Case 2

A 5 year old previously healthy boy expired at home. At autopsy he showed massive soft tissue edema and coagulopathy.

Case 3

A 31 year old previously healthy male presented to the emergency room with severe altered mental status, hypotension, and skin marbling. His family reported a two day history of weakness, sore throat, upper respiratory symptoms, and diarrhea. Within an hour of admission he experienced cardiac arrest and expired. At autopsy he showed severe pulmonary edema and early decompositional changes.

Discussion/Conclusion:

Invasive *streptococcus pyogenes* infections have been shown to cause significant morbidity and rapid mortality. In many cases patients expire before full antemortem testing can be performed, causing physicians and families to look to forensic pathologists for answers. Understanding the pathogenesis of invasive group A strep infections as well as the gross and microscopic findings is critical for forensic pathologists to diagnosis this condition, and assist in the education and protection of the communities they serve.

4.4 Exercise-associated hyponatremia

P.S. Uribe, J.S. Will, R.C. Oh

USAMEDDAC, Fort Benning, Georgia, USA

Exercise-associated hyponatremia (EAH) is a readily preventable condition associated primarily with overconsumption of hypotonic fluids exceeding renal capacity to diurese in a setting of exercise. EAH can be seen in elite athletic populations such as marathon runners, triathletes, and military populations. Classically, the treatment of severe hyponatremia has been focused upon correcting the sodium deficit slowly to prevent the critical complication of central pontine myelinolysis. This traditional approach for chronic hyponatremia may not apply to the current model of exercise-associated hyponatremia in this younger athletic population. The drop of serum sodium due to overconsumption in an athletic event or during exercise can occur rapidly and once recognized,

must be corrected rapidly with 3% hypertonic saline. The gradual correction of hyponatremia using 0.9% saline in these patients may be insufficient to reduce cerebral edema and concomitantly may worsen volume overload, causing potentially increasing cerebral edema, brainstem herniation and death. Misinformation regarding how much water is needed during exercise exacerbates the problem of EAH. This presentation explains the physiology of EAH, examines three cases of fatal EAH, and reviews the diagnosis and treatment algorithms currently in development by the US Army.

4.5 The Importance of Infectious Disease Reporting

K. Pinner¹, S. Ibrahim²

¹Montgomery County Forensic Services, Conroe, Texas, USA;

²Montgomery County Public Health District, Conroe, Texas, USA

The public health role of medical examiner's and coroner's (ME/C) offices is often overshadowed by criminal investigations and high profile cases; although this function is of equal importance. In an outbreak with presentations of sick individuals and deaths at different healthcare facilities, the ME/C may be the first to make the connection between deaths and an infectious agent as well as provide important fatality surveillance.

We present the case of a 3 -1/2 year old boy who died suddenly and unexpectedly following a brief but rapidly debilitating illness. The mother reported initial symptoms of abdominal pain and vomiting followed by altered mental status with hallucinations. Within 5 to 6 hours he became unresponsive and developed a rash. Emergency medical personnel were summoned to the residence and he was found to be hypotensive, febrile, tachycardic and tachypneic. Due to the presenting symptoms, a lumbar puncture was performed which revealed clear cerebrospinal fluid which had no white blood cells and an initial gram stain was negative. His condition declined and he was subsequently pronounced dead 1-1/2 hours after arrival to the hospital. Given the lack of a diagnosis and negative lumbar puncture results, an autopsy was performed approximately 5 hours after he was pronounced dead. The autopsy findings indicated the possibility of a highly infectious disease, prompting notification of the county health department's epidemiologist who initiated an investigation and subsequent treatment plan for affected individuals. Prompt recognition of infectious diseases is an important role of pathologists, both in the forensic and hospital setting. Communication between pathologists and local health officials is critical for the prevention of additional deaths and the protection of at risk individuals through administration of prophylactic medications or vaccines.

4.6 Death Certification in Northern Alberta: Error Occurrence Rate and Educational Intervention

K.A. Wood¹, S.H. Weinberg², M.L. Weinberg³

¹University of Alberta, Edmonton, Canada; ²Virginia Commonwealth

University, Richmond, Virginia, USA; ³Alberta Office of the Chief Medical Examiner, Edmonton, Canada

Background: Studies show that death certificates (DCs) are often fraught with errors, indicating a need for DC completion education. Prior work has shown that interactive case-based sessions produce the greatest improvements in reducing DC completion errors..

Aim: We assessed the effectiveness of an educational seminar targeting the most common and important errors identified by an evaluation of local DCs.

Methods: We retrospectively reviewed DCs completed by Alberta physicians between August and November 2015 to categorize and quantify errors, noting physician speciality and interest in palliative care. This data was used to design a 60-minute didactic seminar with case scenarios for family medicine resident and staff physicians, with

administration of pre-(Pre-S), immediate post (IPost-S), and 2-month post (2Post-S) surveys.

Results: Of the 1392 DCs evaluated the majority were completed by family physicians (73%), followed by internists (18%), and surgeons (3%). Specialties had error occurrence (EO) rates between 32 and 75% (26-68%, excluding formatting errors). Family physicians experienced in palliative care had an EO rate of 32%, significantly lower ($P<0.001$) than family physicians without special interest in palliative care (62%), internists (62%) and surgeons (75%). The most common errors were use of abbreviations (26%), mechanism used as underlying cause of death (McUCoD, 23%) and no underlying cause of death recorded (NoUCoD, 22%). When McUCoD occurred, 95% of the time, NoUCoD also occurred ($P<0.05$).

Results from the Pre-S (n=72) showed an EO rate of 71.5% (64% excluding formatting errors), with no statistical significance between staff (n=9) and residents (n=63) or frequency of DC completion. We found that a lower EO rate, when excluding formatting errors ($P<0.05$), was observed for persons with formal DC education (54%) or electives in pathology (56%) or palliative care (60%) compared to those with informal DC education (67%) or no electives (71%), respectively. Most significantly, IPost-S (n=75) and 2Post-S (n=24) demonstrated a lower overall EO rate of 34% (12%, excluding formatting errors) and 24% (15%, excluding formatting errors), compared to the Pre-S ($P<0.05$). Additionally, the majority of participants found the seminar to be useful (81%), were more confident following participation (81%), and recommended repetition (88%).

Conclusion: A 60-minute seminar on DC completion can significantly reduce the EO rate of common errors with lasting effects.

4.7 Drug Overdose Deaths Involving Fentanyl: The National Picture

M. Warner¹, M.R. Spencer², P.A. Braun²

¹National Center for Health Statistics, Hyattsville, Maryland, USA; ²CDC

National Center for Health Statistics, Hyattsville, Maryland, USA

Background: Fentanyl, a synthetic opioid that is manufactured both pharmaceutically and illicitly, has been increasingly involved in drug overdose deaths. State-based analyses have linked increases in fatalities to the introduction of illicitly manufactured fentanyl. Fentanyl's multiple derivatives and analogs (e.g., acetyl fentanyl, butyryl fentanyl, carfentanyl, U-47700) have various potencies that can be lethal in very low concentrations. National statistics for drug deaths are traditionally limited to International Classification of Diseases, Tenth Revision (ICD-10) drug categories. ICD-10 categorizes fentanyl with other synthetic opioids which limits utility for tracking deaths involving fentanyl. This study utilizes a new method to supplement analyses of ICD-10 drug categories using the literal text data from death certificates (i.e., the written information on cause of death in Part I, Part II, and the how the injury occurred box) to help characterize fentanyl involvement in mortality.

Methods: National Vital Statistics System mortality files linked to literal text information from death certificates were analyzed for 2011-2014 (note by the NAME conference more recent statistics will be cleared to present). SAS Contextual Analysis Software was used to help identify fentanyl related deaths, including misspellings, derivatives and analogs as well as common phrases and terms often included with mentions of fentanyl on death certificates. Age-adjusted death rates were calculated using the direct method and the 2000 standard U.S. population.

Results: From 2011 through 2012, the age-adjusted drug overdose death rate involving fentanyl was 0.5 per 100,000. Starting in 2013, the rate increased significantly. From 2013-2014 the rate doubled from 0.6 per 100,000 to 1.3. In 2014 there were over 4,200 deaths involving fentanyl. Deaths involving fentanyl often involve other drugs. For

instance, in 2014, 63.9 percent of fentanyl-related deaths involved one or more drugs, such as heroin or cocaine, concomitantly. The specificity of information reported on death certificates impacts these rate. Over time reporting of at least one specific drug in the literal text improved from 67% of drug overdose deaths in 2010 to 78% of drug overdose deaths in 2014. Discussion: Fentanyl related deaths are on the rise, and can be identified using analysis of the literal text data on death certificates. In recent years, more medical examiners and coroners are specifying the drugs involved on death certificates which enhances drug mortality surveillance for the nation.

5.1 Suspicious Deaths in Water Workshop

L.D. Knight¹, R. Stoppacher², M. Moody³, C. Yerdon⁴, A. Zaferes⁵

¹Washoe County Regional Medical Examiner's Office, Reno, Nevada, USA; ²Onondaga County Medical Examiner's Office, Syracuse, New York, USA; ³Oswego County District Attorney's Office, Oswego, New York, USA; ⁴New York State Police, Central Square, New York, USA; ⁵Team Lifeguard Systems, Inc, Shokan, New York, USA

Investigation of water-related deaths is challenging, because of the scene environment, associated artifacts, and the fact that drowning is a pathologic diagnosis of exclusion. Proving that a drowning is a homicide can be particularly difficult, and requires a multi-disciplinary investigative approach. During this 2-hour workshop, we will present the case of a teenaged young woman whose body was found floating near the shore of a lake in a well-populated beach area. The cause of her death was determined to be drowning, and the manner of death homicide. We will describe sequentially the scene investigation, autopsy findings, further law enforcement investigation, pre-trial case analysis and ultimately successful prosecution of the case. The workshop presenters, consisting of the autopsy pathologist, testifying pathologist, lead police investigator, prosecuting attorney, and a water-related investigations expert, all participated in the case and will present unique facets of the multi-disciplinary approach to solving the case. Additionally, a review of key investigative steps and critical considerations and findings in suspicious water-related deaths will be presented.

6.1 Leptomenigeal Melanocytic Brain Tumor Associated with Nevus of Ota: Case Report and Review of Literature

F. Pontoriero¹, C.H. Revercomb²

¹Rutgers-Robert Wood Johnson Medical School, New Brunswick, New Jersey, USA; ²Southern Regional Medical Examiner's Office, Woodbine, New Jersey, USA

This presentation will impact the forensic community by raising awareness about the appropriate process involved in the evaluation of melanocytic CNS lesions and how some may grossly mimic cortical bruising leading to misinterpretation of trauma. We describe an index case that provoked a review of the literature on similar rare cases.

The decedent was found at home and pronounced there. She had presented 3 years prior to death with headache and left eye blurred vision, and imaging showed a left M1 segment MCA aneurysm. About 6 months before her death she had left arm paresthesia, and imaging was felt most consistent with a cavernous sinus meningioma extending into the left Sylvian fissure. She had radiosurgery, and 2 months prior to death the lesion had decreased in size. It had not been biopsied due to location surrounding blood vessels in the left Sylvian fissure. The decedent had longstanding left-sided focal facial and ocular pigmentation consistent with nevus of Ota. She had deep leg vein thrombosis about 3 months before death, and was still anticoagulated (Coumadin) when she died.

The autopsy revealed a well-nourished 51 year old woman. External examination revealed the described facial and ocular pigmentation and no signs of trauma, and was otherwise unremarkable. Internally there was multifocal dark brown-black pigmentation of the leptomeninges involving a 9 x 6 cm area of the right and left frontal lobes; a 7 x 5 cm area of the

lateral right cerebral hemisphere; and a 7 x 7 cm area of the lateral left frontoparietal and the left temporal cerebrum. The left Sylvian fissure was focally expanded by dark brown to black tissue surrounding blood vessels medially, and a solid up to 1.2 cm nodule of soft red-brown tissue laterally. The lateral ventricle was dilated, particularly the anterior horns, and had discontinuous dark discoloration of the ependyma. There was tonsillar herniation as a potential mechanism of death, with wrapping of the cerebellar tonsils around the compressed-appearing medulla. The remainder of the autopsy was essentially unremarkable, with no pulmonary thromboemboli. Toxicology, including screening for the prescribed anticonvulsant levitiracetam, was negative. Microscopically, the tumor was composed of loosely-cohesive pleomorphic cells with large round nuclei, prominent nucleoli, and cytoplasmic pigment, and involved the leptomeninges and Virchow-Robin spaces, with superficial invasion of the cerebrum.

The cause of death of this decedent was listed as: Leptomenigeal melanocytic brain tumor associated with nevus of Ota. Manner - Natural.

6.2 Cerebral Vasculitis in a Young Adult: A Diagnostic Algorithm for the Medical Examiner.

A. Gupta, N. Zoumberos, D. Gordon, A. Wilson, K. McFadden
University of Michigan, Ann Arbor, Michigan, USA

Primary CNS vasculitis, defined as an inflammatory process involving only cerebral blood vessels, is exceedingly rare with an estimated incidence of 2.4 cases per 1,000,000 individuals. Diagnosis in the clinical setting is often challenging as the presentation and radiologic appearance are often variable and nonspecific. We present a fatal case of primary cerebral vascular inflammation in a 35-year-old male. The decedent's history was significant only for persistent headaches two weeks prior to presentation at an outside hospital due to an acute increase of intensity of his headache. Initial imaging studies were unremarkable and the patient was discharged for outpatient follow up. On the night of discharge, the decedent's wife heard a bottle drop in the shower and found the decedent with acute onset right sided weakness and garbled speech. Imaging upon readmission was again negative, and the decedent was treated for a presumed ischemic cerebrovascular accident with thrombolytic therapy. He experienced increasing difficulties and magnetic resonance imaging demonstrated changes consistent with acute anoxic brain injury involving the cerebral hemispheres and cerebellum, as well as a large hemorrhagic lesion in the right basal ganglia and surrounding white matter. The decedent rapidly expired. Autopsy findings were significant for mainly intimal, but occasionally transmural, inflammation of the medium and small sized cerebral blood vessels with an unusual, exuberant, intimal giant cell proliferation as well as fibrinoid necrosis. Changes consistent with global acute anoxic damage were also noted. Sampled extra-cranial blood vessels, with the exception of a vertebral artery, did not exhibit vasculitis but were remarkable for significant atherosclerosis. There was no evidence of systemic inflammatory, infection, or neoplasm although systemic influences on CNS vascular inflammation, such as autoimmune/rheumatic diseases, infections, drugs or vasculitis, are often impossible to entirely exclude. We present this unusual case as a basis for discussing the diagnostic differential and challenges involved in evaluating CNS vasculitis in a forensic context.

6.3 Cerebral Infarcts Caused by Topical Hemostatic Agent Embolism: Two Case Reports and Literature Review

W. Tlomak¹, E.J. Cochran²

¹Milwaukee County Medical Examiner's Office, Milwaukee, Wisconsin, USA; ²Medical College of Wisconsin, Milwaukee, Wisconsin, USA

Case 1. A 44-year-old male presented with worsening neck and shoulder pain, difficulty swallowing, voice changes, slurred speech, and 40-pound weight loss. Medical history included hypertension, hepatitis C, non-Hodgkin lymphoma, and alcohol, heroin, and cocaine abuse. He underwent a spinal fusion of the occiput to C3 and needle biopsy of

periodontoid tissue. Brisk intraoperative bleeding along the superior border of the right C1 arch was controlled with Gelfoam and thrombin powder. Postoperatively the patient had right nystagmus and right arm dysmetria. MRI showed an area of restricted diffusion in the right posterior brainstem. CT angiogram showed occlusion of the right vertebral artery. He was diagnosed with a right lateral medullary infarct. Three days after surgery he died.

Autopsy revealed right lateral medulla and cervicomedullary junction infarct and occlusion of the right vertebral artery by reddish-gray material. Right vertebral artery microscopic examination showed an embolus composed predominantly of an amorphous eosinophilic branching non-birefringent material.

Case 2. A 63-year-old female was admitted to the hospital for scheduled anterior cervical discectomy, bilateral foraminotomies, and C3-C6 fusion, due to degenerative disc disease with severe neck pain, radiculopathy, paresthesia, and weakness. During surgery, brisk bleeding, encountered on the right side at the C3-C4 level, was treated with thrombin foam pledgets and Flowseal. After surgery, she experienced delayed awakening and was not breathing spontaneously. CT angiogram of the head and neck showed occluded left vertebral artery with low density material and air emboli in the bilateral V4 segments and basilar artery. She died the day after surgery.

Autopsy showed brainstem, cerebellar, and right temporal and parietal lobe infarcts, and occlusion of the right vertebral artery by reddish-gray material, which was also seen on postmortem angiography. Microscopic examination of right vertebral artery showed emboli composed of amorphous eosinophilic branching non-birefringent material.

Various resorbable and nonresorbable topical hemostatic agents are widely used in neurosurgical procedures to control intraoperative bleeding and prevent rebleeding. Each has a characteristic morphology allowing identification; these vary in degree of birefringence, staining properties, and architecture. Multiple reports of complications of hemostatic matrix use in neurosurgical procedures are reported, including pulmonary vasculature thromboembolism, cerebral venous sinus occlusion, and post-operative development of an inflammatory mass lesion containing the hemostatic agent.

The intravascular material identified in our two cases is morphologically consistent with gelatin foam. These are the first reports of inadvertent intra-arterial embolization of a hemostatic agent each resulting in cerebral infarcts leading to death.

6.4 Maximizing use of Human Brain Donations for Research on Autism Spectrum Disorders

C.M. Schumann¹, C.K. Hare², A.K. Halladay³

¹University of California at Davis, Sacramento, California, USA; ²Autism BrainNet, Sacramento, California, USA; ³Autism Science Foundation, New York, New York, USA

Autism spectrum disorder (ASD) affects at least 1:68 children in the United States but unfortunately still little is known about the underlying neurobiology of ASD and there are no effective biological treatments for core symptoms. The study of postmortem brain material is essential for defining the neurobiology and varying types of ASD, determining causes, refining diagnostic measures, and developing pharmacologic interventions. However, very few brains from individuals with ASD are available to study, which dramatically hinders research progress. To answer the critical need for high quality postmortem brain tissue, an international effort Autism BrainNet was formed in 2014 and continues to be supported by the Simons Foundation Autism Research Initiative (SFARI). In order to make progress in ASD, Autism BrainNet needs brain tissue from individuals with ASD during life and those without ASD or any known medical disorder affecting the brain. Brain tissue is collected from multiple sources, of which Medical Examiners have been a crucial conduit. However, human brain tissue is scarce and must therefore be shared amongst multiple studies ranging from neuropathology to genetics. The

goal of Autism BrainNet is to prepare and process tissue donations in such a way that allows for each brain to be distributed to as many different studies as possible.

In this presentation, Dr. Cyndi Schumann will discuss recent findings from Autism BrainNet facilitated research and how every brain donation can make a large impact on our understanding of ASD. She will provide an example of how a single brain donation provided tissue for up to 30 different research studies. One group of researchers utilized this brain to define the organization of different types of brain cells and how this organization differed from age-matched non-affected brains. A different group of researchers are using this same brain to understand how neurons connect and communicate by better understanding the differences in the size and shape of neuronal dendrites and spines in those with autism. Genetic and epigenetic analyses on this same brain have also revealed genetic mutations that are specific to brain tissue and not found in blood. This latter finding further demonstrates the critical need for brain donations to support research progress in understanding the causes and underlying biology of ASD. Finally, Dr. Schumann will discuss the vital importance of successful partnerships between Autism BrainNet and Medical Examiners in order to move the field of ASD biological research and treatment development forward.

6.5 Occupational Exposure to Radioactive Isotopes After Brain Death Study: Knowing a "Hot" Body When You See One

V.L. Richards¹, R.W. Hilbrandt², K. Ashar¹

¹Westchester County Medical Examiner, Valhalla, New York, USA;

²Westchester County, Valhalla, New York, USA

Use of radioactive isotopes for brain death determination has increased in recent years. Autopsy pathologists, technicians, and funeral home personnel are within close proximity to these bodies shortly after isotope injection, often with our hands in contact with these radioactive ("hot") internal tissues and body fluids. Universal precautions regarding PPE do not effectively mitigate exposure of staff to radioactivity. It is our right to know that a body is "hot" prior to handling it.

Since March 2015, Westchester County Medical Examiners' Office has had a portal radioactivity monitor and has conducted surveillance of radioactivity of all bodies upon accessioning. This study encompasses a 25 month period. The monitor was set to a detection level of 25µrem/h. Any alarm resulted in exposure assessment (mR/hr) by our internal Radiation Safety Officer with a hand-held survey meter. A member of our office staff then followed up with the hospital to determine details of administration (dose, date and time, and radioisotope). The second phase of our investigation was to identify the current policies regarding radioactive decedents held by regulating agencies and professional societies and initiate conversations about the gap in precautions.

During the time of study, 9 bodies were accessioned without any prior knowledge of isotope administration and 3 additional bodies were "hot" upon accessioning as expected by history given (0.15-5.0mR/h). All 12 decedents had received Tc^{99m} for cerebral blood studies as part of the brain death determination. The public may receive up to 2mR/h from a decedent. Our office received 3 bodies exceeding 2mR/h. The result is that autopsies were delayed, causing logistical dilemmas for family members and funeral personnel. Consequently, we have incorporated queries of radioisotope administration at the time of the initial phone report to our office.

The current policy of Nuclear Regulatory Commission distinguishes therapeutic radionuclide administration from diagnostic tests (cerebral blood scintigraphy) and does not recognize the potential harm in this omission. Guidelines from CDC and NAME assume the medical examiner would know about the potential radioactivity prior to autopsy.

We have found that advance knowledge has improved our office case flow and planning. Members of our autopsy staff are reassured that we are working at acceptable levels of exposure because the levels have been measured. The next step is to work with regulatory bodies and professional associations to address the potential exposure this diagnostic study presents to individuals involved in postmortem care or death investigations.

7.1 Value of Postmortem Oral Fluid Analysis for Detection of Illicit and Prescription Drugs in Forensic Pathology,

M. Pandey

Lucas County Coroner's Office, Toledo, Ohio, USA

Our office case load has been steadily rising due to increased drug related deaths in this opiate epidemic. Ohio, has unfortunately become one of the prominent states leading in drug deaths in United States. Oral fluid toxicology analysis of drugs is being routinely done by law enforcement for drug impaired drivers. It is being used clinically by employers to check drug use at work or after any work related incident and also monitoring drug of abuse in correctional institutes. Pharmacokinetics of the drugs in oral fluid is described in literature as being closer to those in blood concentrations, which signifies recent use of the drug. The presence of drugs in urine indicates chronic prior exposure to drugs.

The objective of this 10-week prospective study on approximately 50 cases at Lucas County Coroner's Office, Toledo Ohio was to be able to use oral fluid illicit and prescription drug analysis as an adjunct to body fluid toxicology especially in cases such as decomposition where other body fluids are difficult to obtain. Peripheral blood is considered the optimal sample for postmortem toxicology because of postmortem redistribution of drugs in central blood samples such as from heart. A clinical toxicology laboratory was identified which has recently developed a protocol to detect and quantify illicit and prescription drugs in postmortem oral fluid. The toxicology analysis of oral fluid was done by liquid chromatography tandem mass spectrometry (LC-MS-MS) because of the small volume of sample. This lab usually reports the results of the oral fluid test within 24 to 48 hours as against weeks for a blood test. Parameters of the study were defined. They consisted of a test group, which are drug related deaths, and a control group, which is non-drug, related deaths. The deceased names were not identified in the study. The procedure involved collecting peripheral blood from both groups and submitting it for toxicology analysis to the Coroner's Office toxicology laboratory. The oral fluid was collected from both groups and sent to the laboratory per established protocol in the oral fluid collection kits obtained from the clinical toxicology laboratory. Data was compared and analyzed to determine the value of using postmortem oral fluid analysis for detection of drugs in Forensic Pathology.

7.2 How Many Pills Were Ingested? Danger Ahead, Proceed with Caution!

L. Labay, M. Rieders

NMS Labs, Willow Grove, Pennsylvania, USA

When cause of death is attributed to a drug overdose, the forensic practitioner may be asked about the quantity of pills that were consumed to achieve the reported drug concentration. While formulas exist to address this question, any calculated result must be used with the utmost of care and caution.

To highlight this concept, a case of a deceased two-year old male is reported where toxicology testing revealed the presence of oxycodone at 1200 ng/mL on a peripheral blood sample. The request from an attorney was to determine the number of 40 mg extended-release tablets that would have been swallowed to achieve this concentration. Before performing the calculation several case-specific assumptions needed to be outlined. These included: a) single-dose ingestion; b) that the postmortem blood concentration represented the peak concentration

(C_{max}) and accurately reflected the antemortem blood concentration; and d) no drug or metabolite distribution into other fluids and tissues. It was also presumed that the volume of distribution (V_d) and the blood to plasma drug ratio (b/p) of oxycodone in a 2-year old are consistent with those of an adult. Using the formula ($Dose = C_p \cdot V_d \cdot Wt$), the oxycodone dose was calculated to be 42 mg. This is approximately equivalent to the amount of oxycodone contained within one 40 mg extended-release tablet.

Once the math is completed, it is prudent to then consider if one 40 mg extended-release tablet is capable of producing the analytically determined oxycodone concentration. From a single 40 mg dose, plasma concentrations achieve a C_{max} of approximately 40 ng/mL. This concentration is not consistent with the 1200 ng/mL of oxycodone found in this case. Reasons for the discrepancy outside of postmortem influences include, but are not necessarily limited to, the following: a) the pharmacokinetic parameters are derived from an adult population and are not representative of the pharmacokinetic parameters found in a 2-year old; b) a single 40 mg extended-release tablet was not consumed in its intact form (e.g., it was crushed which resulted in the rapid release oxycodone) or c) more than one 40 mg extended-release tablet in its intact form was ingested.

The complexities and assumptions associated with a pharmacokinetic calculation using a postmortem blood-drug concentration are readily apparent. Over interpretation and considering the final pill consumed count as absolute needs to be avoided. Proceed with caution!

7.3 Intrauterine Fetal Demise and Methamphetamine Exposure

A.L. Wiens, R.J. Miller

Oklahoma Office of the Chief Medical Examiner, Tulsa, Oklahoma, USA

Methamphetamine is a widely abused illicit substance in Oklahoma and is commonly detected in adult postmortem toxicology specimens. There is a paucity of published data regarding the presence of methamphetamine/amphetamine in postmortem specimens of infants, the potential contribution(s) of these substances to fetal demise, and correlation with negative outcomes like placental abruption. We reviewed all cases of intrauterine fetal demise (IUFD) that fell under jurisdiction of the Oklahoma Office of the Chief Medical Examiner (OCME) for the last five years to analyze the incidence of intrauterine methamphetamine/amphetamine exposure.

Fifty-eight (58) cases of IUFD were investigated by the OCME from January, 2012, through December, 2016. Of those, 39 fell under OCME jurisdiction due to reported maternal drug abuse during pregnancy or a positive maternal urine drug screen at the time of delivery, seven for maternal trauma, 10 for being unattended by a physician, one for concern of congenital toxoplasmosis, and one for maternal sudden death due to asthma. Eleven (11) of the 39 cases with maternal history of drug abuse were positive for methamphetamine/amphetamine upon fetal postmortem toxicology testing; there were no instances of fetal positivity for methamphetamine/amphetamine in the absence of maternal history of drug abuse. Methamphetamine levels ranged from 0.84 mcg/mL to 1.4 mcg/mL for heart/cavity blood, less than 0.25 mcg/g to 2.4 mcg/g for liver, and 0.19 mcg/g to 1.3 mcg/g for brain. Amphetamine levels ranged from 0.13 mcg/mL to 0.16 mcg/mL for heart blood, less than 0.24 mcg/g to 0.27 mcg/g for liver, and were less than 0.25 mcg/g for brain. Several cases that were negative for methamphetamine/amphetamine showed positivity for butalbital, ethanol, ketamine, methadone, and phencyclidine. Postmortem toxicology testing was not performed in 12 cases.

Ten of the 58 cases of IUFD showed placental abruption. Of those 10 cases, four showed fetal positivity for methamphetamine/amphetamine, four had maternal history of drug abuse but negative fetal toxicology, one had maternal history of phencyclidine abuse and positive fetal liver phencyclidine, and one occurred in the setting of maternal abdominal trauma. Of the 48 IUFD cases without placental abruption, 30 had a

positive history of maternal drug abuse and 18 did not. Despite the known risk for placental abruption associated with methamphetamine/amphetamine abuse during pregnancy, Pearson's Chi-square analysis of our data did not support this association ($p=0.09$). However, this review did provide a quantitative assessment of methamphetamine/amphetamine in cases of IUFD.

7.4 Isn't Loperamide a Safe Over-The-Counter Anti-Diarrhea Medication?

A. Chan-Hosokawa¹, D. Theriot², C. Ledoux²

¹NMS Labs, Willow Grove, Pennsylvania, USA; ²Terrebonne Parish Coroner's Office, Houma, Louisiana, USA

Since 2015, the opioid epidemic keeps the death toll rising nationwide. In recent years, post-mortem toxicology performed on suspected opioid overdoses routinely identifies not only commonly abused opiates/opioids such as morphine as a metabolite of heroin, fentanyl, and oxycodone, but also designer opioids and even loperamide. Loperamide is an over-the-counter synthetic opioid used to control diarrhea. The lack of central nervous system activity makes loperamide a drug with low potential for abuse when used therapeutically (blood concentrations up to 3.0 ng/mL). As some drug users seek 'highs' that mimic the effect of opioid abuse from non-traditional opioids, we report a case where loperamide was detected as an out of scope finding in cardiac blood and became a crucial finding. Statistical information on loperamide concentrations from 145 cases is also presented.

The case involved a 35 years old Caucasian female found unresponsive at her residence. Clear and sanguine-colored fluid was observed on the decedent's mouth and nose. A full autopsy was conducted; however, no significant finding was revealed (minimal posterior lung congestion). The routine postmortem toxicology panel indicated 0.20 mcg/mL butalbital and 220 ng/mL promethazine in cardiac blood. Additionally, loperamide was detected as out of scope finding via LC/TOF-MS. Loperamide (LOP) and its inactive metabolite, N-desmethylloperamide (D-LOP) were subsequently confirmed 360 and 1700 ng/mL, respectively using LC-MS/MS. The cause and manner of death was determined to be an accidental combined drug overdose. Vitreous fluid and urine were also analyzed: 120 (LOP) and 160 (D-LOP) ng/mL in vitreous fluid; 4900 (LOP) and 42000 (D-LOP) ng/mL in urine.

From August 2016 to May 2017, loperamide has been reported in 145 cases by NMS Labs, with blood concentrations ranging from 6.7 to 1500 ng/mL, with mean and median concentrations of 208 and 140 ng/mL, respectively. The mean and median blood desmethylloperamide concentrations were 882 and 560 ng/mL, respectively (range; 18-10000 ng/mL). 90% of the deceased were ages between 18 and 64 with the median age of 36 years-old; 8% belongs to pediatric and 2% were geriatric populations. Positive loperamide cases were reported in 34 states and Canada, making this a non-regional specific issue. Although loperamide is a safe anti-diarrhea drug at therapeutic dosages, fatalities have been linked to the use of large quantities of loperamide due to over-medication and recreational use. When toxicology results does not support death investigation and autopsy finding in suspected opioid overdoses, consider loperamide and pursue specialized testing to confirm.

7.5 Toxicology Results from an Immunoassay-only Panel Compared to Expanded LCQTOF Testing in a Series of 57 Death Investigation Cases.

B.K. Logan¹, D.M. Papsun¹, S. Colman¹, A. Ross²

¹NMS Labs, Willow Grove, Pennsylvania, USA; ²East Baton Rouge Parish Coroners Office, Baton Rouge, Louisiana, USA

Forensic Pathologists and Medical Examiners make tough decisions every day in balancing the resources available to them, against their commitment and obligation to provide forensically defensible determinations of cause and manner of death. Selection of the appropriate toxicological testing is just one of those decisions, but an

important one as while truly comprehensive toxicology testing can be a major expense, failure to test for possible contributing drugs or poisons can make the difference between the ability to make a determination and not. The 2016 NAME Autopsy Standards require that toxicology testing be performed when appropriate, but provides no guidance as to what scope of testing is appropriate for which circumstances, leaving that to the discretion of the pathologist. In this assessment we evaluated the differences in findings between a basic immunoassay based toxicology panel, versus a more comprehensive Liquid Chromatography Time of Flight Mass Spectrometry (LC-QTOF) approach.

A total of 57 death investigation cases from East Baton Rouge, Louisiana Medical Examiner's office underwent a 13 panel immunoassay (ELISA) based screening (with LCMSMS confirmation of all screened positives) as per the office's SOP. The cases were subsequently subjected to a more comprehensive LC-QTOF screen for over 230 therapeutic and abused drugs and their metabolites, with additional assessment of out of scope findings for emerging drugs including opioids and fentanyl analogs and other designer drugs.

Additional drugs were detected by LCQTOF in 26 cases (46%) which were outside the scope of immunoassay testing. Of these 26 cases, 51 new findings were confirmed. 16% were drugs that were in the scope of the original ELISA test, but were initially undetected due to the lower sensitivity of the ELISA. These included alprazolam (3), lorazepam (2), midazolam (1), and methamphetamine (1). 42 (82%) of the new findings were over-the-counter (OTC) or prescription drugs, including diphenhydramine (4), acetaminophen (3), amitriptyline/nortriptyline (2), quetiapine (2), and tramadol/O-desmethyltramadol (2). There was one instance of an out of scope finding of furanyl fentanyl which was subsequently confirmed at 2.9 ng/mL. Furanyl fentanyl has been a significant contributor to opioid related deaths over the past year.

The death certificate findings of cause and manner of death for each of the cases were evaluated based on determinations made from the basic ELISA results compared to determinations based on the expanded LCQTOF screening, and will be discussed.

7.6 The Family and Friends Discount: Fatal Drug Overdoses Involving Multiple Family Members or Friends

S.E. Ohanessian, M.S. Kessler

Virginia Office of Chief Medical Examiner, Roanoke, Virginia, USA

Background: As drug overdoses increase across the country, our offices have seen these deaths occur in family members, friends, or acquaintances. They may overdose simultaneously or within a short time span of each other. Questions arise such as "What were the surrounding circumstances?" or "Did they overdose with the same drug(s)?"

Design: We examined cases from the past 10 years in the four regional OCME districts of Virginia. The case database was searched by substance abuse codes: ethanol, prescription drug, illegal drug, inhalant, over-the-counter, ethylene glycol, and mixed category poisoning. Accidental, suicidal, and undetermined manners of death were represented. The list was sorted by resident address and place of injury. Duplicates were screened to confirm relation or acquaintance of the decedents which revealed forty-two instances of multi-fatal or related drug deaths (85 total deaths).

Results: Decedents sets were identified as husband-wife (5), boyfriend-girlfriend (16), brother-brother (5), roommates (3), friends (2), father-son (2), and one each of sister-sister, mother-son, father-daughter, and cousin-cousin. One group of three consisted of brother-brother-girlfriend. Place of residence was the same 64% of the time; location of injury was the same 90% of the time.

Half (21) of the overdoses occurred while the pair of decedents were together in the same place, two occurred on the same day with the decedents in different locations, and 18 occurred at different times ranging from five days to four years apart. As expected, sets of overdoses occurring jointly or those which took place on the same day but in different

locations involved nearly identical drugs. Some of those included fentanyl with prescription opiates, methadone with benzodiazepines, cocaine with benzodiazepines, cocaine with fentanyl, heroin and MDMA, amphetamine with an SSRI, and methylfentanyl with oxycodone. Drug similarity between individuals was even seen in those whose deaths were months or years apart.

Interesting cases included a couple, both alcoholics, who ingested methanol in addition to their beer with a fatal outcome; ruled accidents. Two prison inmates at the same facility, in separate incidents on the same day, both overdosed on heroin with fentanyl. Identical twins sisters with the painful condition Pectus excavatum requested donation of their bodies for research, and overdosed together on hydrocodone and propranolol. Two other double suicides were husband-wives with failing death; one took phenobarbital, the other secobarbital.

Conclusion: The increase in drug deaths also reflects those persons who overdose in groups.

7.7 Unusual Fentanyl Overdoses: 2 Case Reviews (Neither one is Prince)

L.L. Bush¹, K. Hobron², L. Morris-Hughes²

¹Virginia Commonwealth University, Richmond, Virginia, USA; ²Virginia Department of Health, Richmond, Virginia, USA;

The first case to be discussed illustrates the need for close collaboration with the scientists performing postmortem toxicology testing. An adult male was found unresponsive by his girlfriend after snorting heroin together. Autopsy revealed evidence of drug overdose with marked pulmonary congestion and edema, congestion of internal organs and a fresh tongue bite. PM toxicology testing was negative for alcohols and standard drugs of abuse though witness statements and autopsy findings were consistent with an overdose. After consulting the toxicologist, the blood was retested for the new fentanyl analogs recently identified in Virginia and revealed Despropionyl Fentanyl(DF). It was signed out as DF toxicity.

DF, a new illicitly produced drug of abuse, may be an analog of, as well as, a metabolite of Fentanyl(FE). It is a known precursor chemical for the illicit production of Fentanyl and is available online as a reference standard for toxicology and drug-testing or as a drug for personal use/ingestion.

Virginia first detected DF in 2016 with a total of 209 DF related deaths. 73 cases had both DF and FE present and 136 cases had DF without FE. 206 of these cases were called accidents and 3 were undetermined. The Northern office had 102 of these deaths, Central and Tidewater districts each had 50 and Western had 4. The greatest numbers of deaths were seen in 25 to 34 year olds. The majority of the decedents were white(158) with 38 blacks, 4 Hispanics, 3 Asians, 5 other and 1 unknown race/ethnicity. Males predominate with 148 males to 61 females. The typical DF overdose decedent is a 25 to 34 year old, white male from Northern Virginia who died accidentally.

The second unusual Fentanyl overdose illustrates how easily inadvertent administration can occur. This white, pre-school male was found collapsed and bradycardic at home. He was normal in the morning but after being out of sight for <5 minutes he was found lying on the floor limp, unresponsive, with difficulty breathing. He frequently got into things and was known to rummage through the garbage can. When he was found, a used Fentanyl patch was stuck to his nose. He was revived with Naloxone(Narcan) and within 10 seconds was awake. No Fentanyl blood levels were done, but they would have been fatal if not treated. This Maltese puppy was saved by quick thinking and pre-treatment information about the Fentanyl patch.

7.8 Illicit Drug Abuse in the Elderly

E. Moffatt

San Francisco Office of the Chief Medical Examiner, San Francisco, California, USA

The American population is aging. The number of people in the United States over the age of 65 is projected to grow from 15 percent of the population in 2004 to 24 percent of the population in 2060. Much of this growth is due to the aging of the Baby Boomer Generation, who have the reputation of using illicit substances.

As a person ages and develops natural disease, it would be natural to assume that the use of illicit drugs would decline. However, our experience in San Francisco shows that this is not the case. From 2005 to 2015 (the last year of complete data), the number of persons over the age of 60 dying from illicit drug use (cocaine, methamphetamine, heroin or other non-prescription drugs) increased from 4 in 2005 to 26 in 2015. In these years, the caseload was relatively stable (from a low of 1222 in 2014 to a high of 1398 in 2005) and the number of illicit drug deaths overall was also relatively stable (from a high of 669 in 2011 to a low of 616 in 2006).

The absolute number of elder deaths due to illicit drug use in San Francisco is small, 26 deaths in a total of 1233 deaths investigated by our office in 2015. In most of these cases, drugs or paraphernalia was found at the scene, or family stated that there was recent drug use, prompting testing for illicit substances. Many other cases of drug overdose may be missed, since many of these decedents have a history of natural disease which may cause death and toxicology testing may not be performed due to biases toward natural disease and disbelief that elderly people use illicit substances.

Other medical disciplines have recognized this phenomenon. Emergency room physicians, mental health workers and social workers have seen a trend of illicit drug use that began in youth and continued to old age. The use of ethanol in the elder population is well known, but there is much less information available on illicit drug use by the elderly. Elderly decedents may also require toxicology to determine a cause of death.

8.1 Determination of Manner of Death in Snake Bite Related Fatalities: A Comparison of Accident vs. Suicide

K.V. Crowns, M. Montonera

Travis County Medical Examiner's Office, Austin, Texas, USA

Every year in the United States people are bitten by venomous snakes. The CDC reports that an estimated 7,000 – 8,000 people are bitten every year with about 5 of these victims dying. There are approximately 20 venomous snakes in North America divided into four groups: rattlesnakes, copperheads, cottonmouths and coral snakes.

Since 2009, Travis County has had three snakebite related fatalities. Of these cases, two were ruled accidents, one was ruled suicide. Comparison of the three cases examined included characteristics regarding the type of snake, the bite wounds, the scene and the decedent's behavior at the scene.

In the two accidental deaths, the decedents encountered a native timber rattlesnake in the wild. In the suicide, the decedent possessed a permit to own the non-native monocle cobra. Rattlesnakes are native to the U.S. and present throughout Texas whereas the monocle cobra is generally found in India, China, Vietnam and Cambodia. Scene examination for the accidental deaths determined the snake was unintentionally discovered whereas in the suicide case, the snake was purposely removed from a secure container. Also the accidental cases had no experience with the rattlesnakes as opposed to the suicide case where the decedent was a pet store employee with a valid permit to own the snake that killed him. In comparison to the two accidental cases, the suicide case showed multiple paired puncture wounds of the forearms with only one incised wound. The accidental death cases demonstrated incised wounds consistent with the snake being aggressively pulled off of the extremity by the decedent or witness as compared to the paired puncture wound in the suicide similar to when an individual "milks" a venomous snake. Typically

a snake will strike once as seen in the accidental cases however, there are multiple bites sited in the suicide case. The behavior of the decedent in the accidental cases was to run and seek help whereas in the suicide case the decedent stayed in his car after he slightly opened the car door and released the snake. The cobra itself was not found at the scene and was recovered the next after having been run over in a roadway.

Comparing these three cases demonstrates a clear separation between unintentional and intentional snake bite related fatalities based on the circumstances surrounding death, the scene, the type of snake and the injuries found at autopsy.

8.2 Anterior Cervical Spine Fractures with Accompanying Prevertebral Fascial Hemorrhage but Without Cervical Spinal Cord Injury: A Casual Observation at a Forensic Autopsy or a Finding of Potential Clinical Relevance?

M.J. Caplan, P.F. Mellen

Suffolk County Office of the Medical Examiner, Hauppauge, New York, USA

Most forensic pathologists have likely encountered during their careers the innocent artifact of a fractured cervical spine. Following removal of the anterior neck compartment structures, the fracture of the anterior surface of the cervical vertebral body and the accompanying laceration of the anterior longitudinal ligament is visualized, and the conspicuous absence of adjacent prevertebral fascial hemorrhage confirms the injury as a postmortem phenomenon. Much less commonly observed, however, is the combination of an anterior cervical spine fracture and surrounding soft tissue hemorrhage. We describe this observation in 4 autopsies with the following common clinical features: 1) the decedents were elderly male adults ranging from 64-79 years; 2) the fractures were localized to the lower cervical vertebral levels (C4-C6); 3) all of the decedents sustained falls with blunt-impact injuries characterized by faint, thin-layered frontal or frontoparietal subgaleal scalp contusions and minimal external injuries (facial and forehead abrasions); 4) the consistent predisposing factor for the cervical spine injury was age-related degenerative changes of the cervical spine; 5) all of the decedents had natural disease histories dominated by hypertensive and atherosclerotic cardiovascular disease, which were primary or contributory causes of death in all of the cases. The common theme emerging from this small series is that the advanced age of the decedents and associated degenerative cervical spine changes likely facilitated the creation of minor injuries sustained in terminal falls that were precipitated by acute natural disease events, most frequently cardiac arrhythmias complicating advanced hypertensive and atherosclerotic cardiovascular disease. While these injuries probably played no significant role in the pathophysiologic sequence of events culminating in their death, they do raise the consideration of cervical spine injury in the resuscitation of elderly patients, which involves some degree of neck hyperextension during the standard maneuvers employed to establish an airway. Degenerative disk disease results in disk space narrowing and shortening of intervertebral distance, and cervical spondylosis encompasses the spectrum of degenerative vertebral body and intervertebral disk disease occurring in the cervical spine of elderly patients, along with osteophyte formation and bulging of the ligamentum flavum. Therefore, it behooves resuscitation specialists to be aware of the potential hazards of airway management in the elderly.

8.3 Whole Body Digital Scanning (WBDS) vs Computed Axial Tomography (CT): Experience of the Armed Forces Medical Examiner System (AFMES)

H.T. Harcke, E.L. Mazuchowski

Armed Forces Medical Examiner System, Dover AFB, Delaware, USA

The AFMES has had the opportunity to perform postmortem imaging with two advanced digital radiographic units: the Lodox Statscan® whole body scanner (WBDS) and the GE Lightspeed® 16 CT scanner (CT). The CT scanner is upgraded for forensics with a larger bore and extended table

travel. Use of both machines has afforded the opportunity to compare the systems regarding advantages and disadvantages. AFMES protocol for every forensic pathology investigation conducted is to image with both systems. AFMES has performed over 250 investigations with this protocol; these include traumatic and non-traumatic deaths.

Factor Comparison	WBDS	CT
Equipment (16-64 slice CT) Cost*	450K 15K per year	<250K (used), >400K(new) 125K per year
Maintenance* Operation	Simple, Rad Tech not required	Complex, best done by Rad Tech
Imaging (16 slice CT) Capability	Whole body scan in 13 seconds, Image immediately available	Whole Body Scan 1.5 min, Image processing 3 min
Flexibility	Frontal, Lateral and Oblique scan Whole Body or Region PACS** not required	Axial Scan with 3D Multiplanar Reconstruction Whole Body or Region PACS recommended
Archiving		
Visualization on Imaging Skeletal Organs Metal	Displaced and misaligned fractures visible Limited organ assessment Sharp edge visualization	Superior for subtle fractures Good Organ Assessment Metal Streak Artifact

*Estimate \$, not including installation and facility upkeep

** Picture Archiving and Communication System

The WBDS is a good replacement for conventional 2D digital radiography. A high volume of cases can be scanned with considerable time saving over conventional radiography and minimal manipulation of the body. When metal detection is the goal the unit is adequate. While there is good visualization of metal, the WBDS (even with two views) is not as precise for localization as CT. Despite having both units the AFMES still on occasion utilizes a fluoroscopic (C-arm) unit for recovering small ballistic fragments.

Forensic requirements for CT differ from those for clinical scanning; there is no concern for motion and need for high speed acquisition. It is our opinion that multislice scanners of 16-64 slice capability are more than adequate. The metal streak artifact on CT makes characterization of metal fragments difficult even with the scout view. The superior fragment visualization with the WBDS dictates the AFMES procedure to use both in concert. If the goal is to provide a capability for limited and/or non-invasive autopsy, CT affords better detection of organ and skeletal pathology. The WBDS cannot substitute for the versatility of cross-sectional imaging provided by CT.

8.4 Streptococcal Wound Infection in a Pathologist Following a Scalpel Injury During an Autopsy of a Man with Fatal Group A Streptococcal Bacteremia

M. Bell

Palm Beach Medical Examiner Office, West Palm Beach, Florida, USA

A 66-year-old previously healthy man developed malaise, head and body aches and low-grade fever over the course of two days. He died suddenly at his residence on the third day. Despite refrigeration, his body at autopsy 16 hours after death showed evidence of accelerated putrefaction. Blood

vessels in all sampled organs contained bacterial cocci microscopically. Group A streptococcus was grown from postmortem blood cultures. During the autopsy, a 54-year-old previously healthy pathologist superficially punctured the skin of his left 2nd finger with the tip of a contaminated scalpel blade. Within 24 hours after the autopsy, the pathologist developed a spreading cellulitis with malaise and low-grade fever that was successfully treated with intravenous antibiotics. Occupational blood-borne infection in autopsy pathology often focuses on hepatitis or human immunodeficiency viruses. Occupational hand injuries are common in autopsy pathology and may lead to self-limiting localized bacterial wound infections. As this case demonstrates, group A streptococcus can be invasive, disseminate rapidly and prove fatal and therefore any penetrating skin injuries sustained during the autopsy of a person with this aggressive bacteria should also be treated aggressively.

8.5 Organ/Tissue Procurement Organization Costs Associated with Tissue Recovery from ME/C Cases

K.A. Collins¹, M. Reiner², L. Jares³

¹Newberry Pathology Associates, Wadmalaw Island, South Carolina, USA; ²Musculoskeletal Transplant Foundation, Atlanta, Georgia, USA;

³Musculoskeletal Transplant Foundation, Edison, New Jersey, USA

Over the past several years, there has been a dramatic increase in the interactions between Medical Examiners (ME)/Coroners (C) and Organ/Tissue Procurement Organizations (PO). Reasons for this increase include heightened awareness by the general public to sign organ and tissue donor cards as well as the legal requirement that these procurement agencies must follow the wishes of the decedent as outlined on the donor card. The need for donor organs and tissues for transplantation continues as new therapies prove to be life enhancing. POs have a responsibility to honor individuals' wishes and attempt to recover every organ/tissue every time.

Hospitals are required to refer all deaths to their designated PO regardless of the cause of death. However, as a large number of individuals die outside of a hospital, attention has been turned to cases under ME/C jurisdiction. Many of these cases are deaths of individuals under 55 years of age, thus optimal donors for tissues in high need by patients awaiting transplantation.

This increased interaction with PO can place additional burdens on the ME/C offices. A growing number of ME/C have worked closely with their PO to provide in-house recovery areas. An earlier survey conducted by Mary Dudley, MD and the Musculoskeletal Transplant Foundation's Medical Examiner and Coroner Advisory Committee (MECC) questioned ME/C about their involvement and attitudes toward donation. No questions were asked regarding charges to PO by ME/C offices for their involvement in cases under their jurisdiction.

In the fall of 2016, the MTF MECC sent a survey to 28 Medical Examiner/Coroner Liaisons working at 25 PO. Results of the survey showed that despite the increased ME/C – PO interaction, only 44% of the respondents stated that their PO had a MOU with their ME/C offices. The survey specifically looked at the costs that ME/C were charging procurement agencies to assistance with tissue donations.

Cost for use of facilities was the most common charge by the ME/C offices to the PO. 75% of PO stated that they paid rent for use of a recovery room/suite. Other costs associated with recovery included: copies of the official autopsy report (42%), repairs and upkeep of the equipment and recovery area (33%) and a copy of an official death certificate (25%). This survey is the first to collect national information on charges by ME/C to the PO during the overall process of recovery and transplantation.

8.6 Beyond Bone Chips and Corneas

K.A. Collins¹, L. Jares², M. Reiner³

¹Newberry Pathology Associates, Wadmalaw Island, South Carolina, USA; ²Musculoskeletal Transplant Foundation, Edison, New Jersey, USA;

³Musculoskeletal Tissue Foundation, Atlanta, Georgia, USA

Every medical examiner/coroner (ME/C) interacts with organ and tissue procurement organizations (PO), some on a daily basis. This often involves much time at all hours of the day. It requires conducting an accurate medicolegal death investigation and also allowing recovery to save and enhance lives. The ME/C serve the living. But, as most ME/C offices are currently understaffed and underfunded, taking the time to work with PO and recovery is often perceived as a burden. In 2017, what does allowing tissue recovery really mean? In other words, what advances in transplantation have been made to make the ME/C decision to allow recovery in forensic cases so impactful? This presentation will update the audience on the advances in tissue transplantation including the use of stem cells, adipose tissue, peripheral nerves, veins, cartilage and others needed for life enhancing AND life-saving procedures. Pathology and potential causes of death will be presented and the role of tissue transplant treatment discussed, emphasizing the role of the ME/C.

8.7 Increasing Tissue Donations From A Non-Hospital Death Referral System Via ME/Coroner EMR

D.A. Lanter, R.J. Gegg

Mid-America Transplant, St. Louis, Missouri, USA

Purpose: To gain greater access to potential donors that expire outside of the hospital and because nearly 70% of potential donors fall under the medical examiner/coroner jurisdiction, our Organ Procurement Organization (OPO) collaborated with our local Medical Examiner (ME) programs to increase the number of referrals and tissue donors from non-hospital deaths. The ME programs included cover three counties and a population base of over 700,000 people.

Methods: Mortality data collected suggested that the OPO was not receiving all the potential donors meeting the OPO criteria. As a result, we collaborated with the ME offices to implement a more systematic program to provide 100% referral of all eligible tissue donors. The software utilized was the Medicolegal Death Investigation Log (MDILog) managed by the Occupational Research and Assessment (ORA) Company. This software electronically interfaces with our OPO's call center. Once the Death Investigator enters their information into the electronic medical record (EMR) MDILog and saves, the data is transmitted automatically to the OPO. If the OPO identifies the referral as an eligible tissue donor, they will contact the family to secure authorization for donation. MDILog was launched on 10/01/2015 and is utilized by three counties within the OPO's DSA.

Results: The measures below were utilized to evaluate the effectiveness following the implementation of the MDILog.

Outcome Measure	10/01/2016-03/31/2017	10/01/2015-09/30/2016	10/01/2014-09/30/2015
Total referrals	826 (annual. 1652)	1206	1012
Number of approaches	80 (annual. 160)	176	139
Number of authorizations	60 (annual. 120)	125	98
Authorization rate	75%	71%	70%
Total eye & tissue donors	37 (annual. 74)	80	62

Results after one year demonstrate that total tissue referrals increased by 19% and the number of eligible approaches by 27% that yielded a 29% increase in total eye and tissue donations. Based on the most recent two quarters, referrals are expected to increase 37% with a 75% authorization rate, up from 71%. In addition, Electronic referrals have significantly reduced the need for phone calls to the ME offices and has resulted in increased ME office staff satisfaction.

Conclusion: Implementation of the MDILog demonstrated eligible non hospital death referrals and donors have increased. This systematic process has also led to the referral of all eligible donors electronically,

significantly streamlining the referral process. In addition, a more formalized role to our ME/Coroner Relations Specialist has developed. This OPO will continue the MDILog interface and seek to expand the implementation to further increase non hospital referrals/donors.

9.1 The Determination of Causes of Death in a Global Surveillance Network: The DeCoDe Process in the Child Health and Mortality Prevention Surveillance (CHAMPS) Program

D.M. Blau¹, P. Raghunathan¹, J. Ord², S.R. Zaki¹, R. Breiman³, J. Koplan³

¹Centers for Disease Control and Prevention, Atlanta, Georgia, USA;

²ISGlobal Barcelona Institute of Global Health, Barcelona, Spain; ³Emory University Global Health Institute, Atlanta, Georgia, USA

Every year, nearly six million children under the age of five die.

Unfortunately, the causes of these deaths often remain a mystery due to gaps in disease surveillance, death registries and data to inform evidence-based policy—especially in low-resource countries, where mortality rates are highest. The Child Health and Mortality Prevention Surveillance (CHAMPS) Network works to close these gaps by gathering the evidence needed to save young lives. As a 20-year program supported by the Bill & Melinda Gates Foundation, CHAMPS seeks to identify definitive causes of and prevent child deaths through community engagement, diagnostic and laboratory innovations, surveillance network advances, policy-to-action activities and rapid, open access to data. The initial network sites are located in South Africa, Mozambique, Kenya, Mali, Bangladesh and Sierra Leone. As part of the diagnostic and laboratory innovations, minimally invasive tissue sampling (MITS) is performed postmortem with subsequent histological, molecular and microbiological testing. The histological evaluation includes pathogen specific immunohistochemistry, and PCR from formalin-fixed paraffin blocks. The authors will present these detailed testing methods and preliminary diagnostic results from two of the sites. In order to further understand and define the causes of death in these surveillance sites, CHAMPS will utilize a panel approach to adjudicate the diagnoses. This Determination of the Cause of Death (DeCoDe) panel includes clinicians, pathologists, microbiologists and medical epidemiologists selected by each surveillance site. The authors will describe the training provided for these panel members, the detailed process flow of these cause of death determinations, and quality assurance procedures. Finally, preliminary cause of death data from the network will be described.

9.2 Two Accidental Infant Hyperthermia Deaths in Closets

E.D. Christensen, M. Belenky, J. Pestaner, P.S. Ulmer
Office of the Medical Examiner, Taylorsville, Utah, USA

Introduction

Childhood death caused by environmental heat exposure is not common. We report two deaths of infants (twelve and eighteen months old) that were placed in closets with cribs and electric space heaters for warmth. The cause of death for both cases was hyperthermia and both were viewed as accidental deaths.

Case 1

The mother placed her 18 month female infant for the night in a crib in a closet where the child had been sleeping for the past 6 months. The closet was cold so she turned on the heater and closed the door. The following morning she found the child deceased. There was in-floor heating which was inefficient and portable heaters were used throughout the house. There were some concerns from the parents that the closet would get too warm, so a fan was placed in the closet to help cool it off. Autopsy revealed drying of the skin and focal skin sloughing. No intrathoracic petechiae were noted and there was no anatomic cause of death. Vitreous electrolytes revealed urea nitrogen of 45 mg/dL, creatinine of 1.1 mg/dL, sodium of 138 mmol/L, and chloride of 124 mmol/L.

Case 2

The father placed his 12 month male infant down for the night in a crib in a closet which was where the child always slept. The house had baseboard heating which did not work. The weather had gotten warmer but concern over warmth caused the father to turn on the space heater that night. The child was found unresponsive the following morning.

When fire personnel arrived, they took thermal readings in the closet.

Thermal readings taken 30 minutes after the closet door was opened were as follows: crib 98°F, ceiling 108°F, and floor 105°F. Readings in the adjacent bedroom were 72°F at the ceiling and 67°F on the floor.

Autopsy revealed drying of the skin and focal skin sloughing. The visceral surfaces were not dry. Epicardial and thymic hemorrhages were present and there was no anatomic cause of death. Vitreous electrolytes revealed urea nitrogen of 27 mg/dL, creatinine of 2.1 mg/dL, sodium of 158 mmol/L, and chloride 136 mmol/L.

Discussion

Placing infants and children in closets is not unusual but the two cases reported are the only cases of hyperthermia from such a sleep environment that we are aware. The cases underscore the importance of complete and thorough death investigations to determine cause of death.

9.3 WITHDRAWN

9.4 Explained Infant Suffocation Deaths Attributed to Soft Bedding, Overlay, and Wedging

A.B. Erck Lambert¹, S. Parks², L. Camperlengo², C. Cottengim², T. Covington³, F. Hauck⁴, C. Shapiro-Mendoza²

¹DB Consulting Group, Contractor for Center for Disease Control and Prevention, New Orleans, Louisiana, USA;

²Centers for Disease Control and Prevention, Atlanta, Georgia, USA; ³National Center for Fatality Review and Prevention, Washington DC, District of Columbia, USA;

⁴University of Virginia, Charlottesville, Virginia, USA

Background: Sudden unexpected infant death (SUID), including accidental suffocation and strangulation in bed, Sudden Infant Death Syndrome, and undetermined causes, is an important cause of US infant mortality. Local and state child death review teams review and discuss death scene and autopsy information to understand the circumstances surrounding SUID cases and explore the role of soft bedding, overlay, and wedging in accidental suffocation deaths. Understanding the mechanisms that contribute to suffocation deaths can inform prevention strategies.

Methods: To better understand the mechanisms of explained infant suffocation deaths, we analyzed data from 10 states participating in the SUID Case Registry; these data are a subset of cases reported to the National Child Death Review Case Reporting System. Using the SUID classification algorithm, all SUID Case Registry cases are assigned a category and, if categorized as possible suffocation or explained suffocation, the case is also assigned one of four mechanisms (soft bedding, overlay, wedging, or other). In the analysis, we included deaths that occurred from 2011 through 2014 and were categorized as explained suffocation. Explained suffocation is comprised of cases with a complete case investigation, non-conflicting evidence of full external airway obstruction, and no other potentially fatal conditions. Frequencies and percentages of the prevalence of selected unsafe sleep factors (e.g., sleep place, sleep position, and surface sharing status) and mechanisms to which suffocation was attributed were reported for explained suffocation deaths.

Results: Among explained suffocation deaths (n=250), soft bedding was the most prevalent mechanism (64%), followed by overlay (20%), wedging (13%), and other (2%). Among explained suffocation soft bedding deaths, most infants were found prone (88%) on an adult bed (46%) or in a crib/bassinet (31%) with their airway obstructed by a blanket(s) (35%) or a pillow(s) (25%). Among overlay deaths, most infants were placed to sleep on an adult bed (73%), and overlay by their mother (47%) was most

frequently reported. Among wedging deaths, most infants were found wedged between an adult bed/mattress and a wall (48%), followed by between an adult mattress and the bedframe (27%).

Conclusions: This analysis shows that the information gathered during the death investigation is crucial in understanding specific risk factors in infant sleep environments, which can help inform and refine prevention messages, specifically the importance of removing soft bedding from infant sleep environments and that surface sharing can lead to overlay.

9.5 Sudden Unexplained Death in Childhood: Systematic Analysis of the Hippocampal Landscape

D. McGuone¹, R. Reichard², A. Faustin³, M. Snuderl³, C. William³, T. Wisniewski³, B. O'Connell³, L. Crandall³, O. Devinsky³

¹Office of Chief Medical Examiner New York City, New York, New York, USA; ²Mayo Clinic, Rochester, Minnesota, USA; ³New York University Langone Medical Center, New York, New York, USA

INTRODUCTION: Sudden unexplained death in childhood (SUDC) is the sudden death of a child older than 12 months whose cause of death remains undetermined following thorough case investigation including a review of the clinical history, circumstances of the death, and a complete autopsy with appropriate ancillary testing. Previous retrospective case series have implicated developmental abnormalities of the hippocampus in many SUDC cases, with bilamination of the dentate gyrus frequently reported as a key finding. The frequency and significance of hippocampal developmental abnormalities in SUDC and control cases is poorly defined. No national guidelines exist for investigating SUDC cases and there are no standardized neuropathology guidelines for examination of the brain in SUDC.

METHODS: We undertook a retrospective review of 57 cases of previously certified sudden unexpected childhood death referred to the SUDC Registry and Research Collaborative (SUDCRRC) to assess comprehensiveness and standardization of the initial neuropathology examination. A systematic protocol comprehensively examined the brain in suspected SUDC incorporating 3-T MRI imaging, photography, macroscopic examination, sectioning using anatomic landmarks and sampling of 15 brain regions including hippocampus bilaterally and at multiple levels for histology. All microscopic slides were scanned using an Aperio digital pathology slide scanner. Three board-certified neuropathologists undertook blinded reviews of whole brain digital photographs as well as scanned microscopic sections for 12 cases including one control examined prospectively per this protocol.

RESULTS: Marked variation in approach to neuropathologic examination between forensic institutions was identified on retrospective review of 57 previously completed cases. 47% of these cases had 3 slides or fewer of brain for neuropathologic evaluation and many had an insufficient number of slides to permit adequate neuropathologic examination. On prospective blinded review of 12 cases including one control, hippocampal microscopic changes were identified by at least one neuropathologist in all cases and by 2 neuropathologists in 9 of 12 cases including the control. Most frequently observed and agreed upon changes were alternating dentate gyrus thickness, irregular configuration of the dentate gyrus, granule cell loss in the dentate gyrus and gliosis. Dentate gyrus bilamination was present in a minority of cases. Red neurons typical of acute hypoxic-ischemic neuronal damage were not found in any case. CONCLUSION: A systematic protocol for brain examination including correlation with radiology and molecular biology findings is greatly needed to advance our understanding of the significance of hippocampal microscopic changes and their biologic significance in the pathogenesis of SUDC.

9.6 Febrile Seizures and Asphyxial Deaths in Infants and Toddlers with Hippocampal Developmental Abnormalities

D. Mileusnic-Polchan

Knox County Regional Forensic Center, Knoxville, Tennessee, USA

Five cases of sudden unexplained deaths in young children, ages 12 months to 4 years, are described. Investigative challenges and the impact on several local pediatric practices are discussed. All five boys died while sleeping in prone position, each face down in a pillow. Accidental asphyxia would not be a consideration unless unforeseen circumstances prevented these children from changing positions. Since kids this age should be able to extricate themselves, other reasons for their inability to change positions and therefore asphyxiate were considered, including foul play. Similar to few cases described in the literature, several important investigative clues and factors became apparent. All children had recent or current episodes of low grade fever. In one 1-year old, the fever was associated with mild cold. One child (18-months) had recently had a middle ear infection. One of the 4-year-old boys had a combination of cold and middle ear infection. Another 1-year-old and the second 4-year-old had gastrointestinal symptoms with vomiting and diarrhea. Two children (both 4-years-old) had at least one previous episode of febrile seizure. After the autopsy report was finalized, the mother of one of the 1-year-old boys revealed that she had febrile seizures as a child. Her son received a set of vaccinations (diphtheria/tetanus/pertussis, measles/mumps/rubella, varicella) in spite of low grade fever the day before his death. The other 1-year-old boy was one of twins born to a couple that utilized donor eggs, therefore family history was not available. He had recently received the same vaccinations as listed above. In one case, the question of febrile seizure in close relatives was not broached. All five cases had varying histologic degrees of congenital hippocampal microdysgenesis. Two of these children were patients in the same pediatric group practice. Subsequently, the group instituted practice changes such as temporarily withholding vaccinations until a child is afebrile. Our subsequent investigative emphasis included obtaining histories of febrile seizures for all children and their close relatives. Multilevel sampling of the bilateral hippocampi is recommended in cases that fulfill the following criteria: 1. Sudden death while sleeping in prone position between 9 months and 4 years of age; 2. Recent history febrile illness; 3. Diagnosis of at least one episode of febrile seizures in either the child or a close relative.

9.7 CDC's Sudden Unexplained Infant Death Investigation Reporting Form (SUIDIRF)

C. Cottengim, E.O. Johnston, L. Camperlengo, A. Erck Lambert, S. Parks Brown

Centers for Disease Control, Atlanta, Georgia, USA

Background:

In 2015, there were about 3,700 sudden unexpected infant deaths (SUID) in the United States. Although the cause of death may be unexplained, most occur while the infant is sleeping in an unsafe sleeping environment. Improved death investigations can lead to a better understanding of the circumstances associated with SUID, which can inform prevention strategies.

In 1992, the US Congress recommended that a standard infant death scene investigation protocol be established. In 1993, a workgroup was formed and the original Sudden Unexplained Infant Death Investigation Reporting Form (SUIDIRF) was released in 1996. In 2006, CDC and partners updated the SUIDIRF and developed an accompanying training curriculum for conducting a thorough SUID scene investigation. After 11 years, it is unknown if end-users find the form helpful, or have suggestions for improvement.

Methods:

In April 2017, CDC's SUID Case Registry staff participated in an evidenced-based entrepreneurial training, Ideation Catalyst (I-Catalyst). This training, hosted by CDC's Office of Technology and Innovation and Georgia Tech's VentureLab, is a customized program to equip CDC staff with an expanded skill-set and the tools to engage end-users into solutions.

As part of the I-Catalyst program, CDC staff interviewed 50 stakeholders about their experience with the SUIDIRF. Stakeholders included death scene investigators, law enforcement officers, pathologists, state health office staff, and child death review members. Through the phone interviews, CDC staff sought to understand how infant deaths are investigated, if and how the form is used in the field, the potential need and suggestions for revisions to the form, and training needs.

Results:

Preliminary results suggest that investigators use the SUIDIRF as one source of information to compile a case narrative, and that it is often not used as a stand-alone tool nor completed thoroughly. Along with suggestions for modifications, the respondents stressed the importance of continued training for new staff. Respondents felt that investigators needed training on interviewing techniques as well as the importance of understanding infant development, infant feeding, and family history of sudden death. Suggestions for modifications included reordering the form, reducing redundancy, and clarifying definitions like wedging. Respondents stated they would be willing to adopt an updated SUIDIRF.

Conclusions:

Participation in the I-Catalyst program provided critical feedback that the current SUIDIRF meets most investigators' needs, but investigators would both welcome and be willing to use an updated form. It was determined that in-person training should accompany any SUIDIRF revision.

9.8 Surveillance of SUID in 16 States and Two Jurisdictions: CDC's SUID Case Registry & Classification System Update

S.P. Brown¹, C. Cottengim¹, A.E. Lambert², L. Camperlengo¹

¹Centers for Disease Control and Prevention, Atlanta, Georgia, USA; ²DB Consulting Group, Silver Spring, Maryland, USA

In 2009, the Centers for Disease Control and Prevention (CDC) launched the Sudden Unexpected Infant Death (SUID) Case Registry. In 2014 we added the Sudden Death in the Young (SDY) Case Registry, expanding the surveillance of sudden unexpected death to include children up to the age of 18 years old and incorporating biospecimen genetic testing for a sample of cases. Since 2014, when we last presented this information at the National Association of Medical Examiners Annual Meeting, SUID surveillance has also expanded from 9 states to 16 states and two jurisdictions. Cases from these 18 locations account for 30% of all U.S. SUID.

In 2014, CDC developed its SUID classification algorithm, which employs a standardized approach to categorizing SUID cases based on levels of available evidence, including information from the death certificate and scene investigation. The algorithm does not reassign cause of death, but groups cases into categories for the purposes of surveillance and prevention efforts.

This presentation will provide updates on the SUID and SDY Registries, including key findings to date. Results from 4 cohorts of SUID and SDY case registry data to which the SUID classification algorithm has been applied will be discussed along with a review of the algorithm national roll-out.

Grantees have completed quality assurance reviews for 5 complete death year cohorts (2010-2015), resulting in 3,503 completed cases in the SUID Case Registry as of January 15, 2017. For the SDY registry, there are 82 cases with biospecimens, 10 of which will undergo genetic testing.

CDC has applied the SUID classification system to 1,745 cases that occurred from 2011 through 2014. The majority (41%) of cases were assigned to the *unsafe sleep factors* category, followed by *incomplete case information* (27%), and *explained suffocation with unsafe sleep factors* or *possible suffocation with unsafe sleep factors* (both 14%). Of the cases assigned to the *explained suffocation* or *possible suffocation*

categories, 69% were attributed to the soft bedding mechanism, 17% to overlay, and 9% to wedging/entrapment of an infant between two objects.

The SUID surveillance system and now the CDC SUID algorithm for classification aim to improve surveillance and understanding of SUID in the United States through continued data quality improvement and application of the standardized SUID classification algorithm.

Understanding the circumstances of these deaths using the SUID Case Registry and the data compiled from death investigators allows users to more accurately understand and prevent future deaths.

10.1 Sudden Unexpected Infant Death Certification in New York City: Intra-agency Guideline Compliance and Variability

M.A. Pasquale-Styles¹, M. Regensburg², R. Bao¹, C. Lin³

¹New York City Office Of Chief Medical Examiner, New York, New York, USA; ²Sudden Infant and Child Death Resource Center, New York, New York, USA; ³Stony Brook University, Stony Brook, New York, USA

Background: Sudden infant death certification has undergone a diagnostic shift with a decrease in Sudden Infant Death Syndrome (SIDS) and increase in Asphyxia and Undetermined deaths primarily due to increased awareness of risk factors of asphyxia in the scene. Variability in certification of similar types of cases exists among forensic pathologists. This study sought to measure adherence to intra-agency guidelines for infant death certification in one jurisdiction and describe the number and type of risk factors for asphyxia and other findings that may cause forensic pathologists to differentiate SIDS, Asphyxia and Undetermined causes of death.

Materials and Methods: A retrospective study of cases over an 11-year period at the New York City Office of Chief Medical Examiner identified sudden infant deaths during sleep with autopsy, a complete assessment of five risk factors for asphyxia and whose cause of death was ruled SIDS, Asphyxia or Undetermined, resulting in a data set of 427 infants. Investigative and autopsy reports were reviewed for risk factors for asphyxia, reasonably conclusive evidence of asphyxia (witnessed overlay, obstruction of the nose/mouth or covered head) and potential competing factors such as natural pathology or suspicions surrounding the death. Descriptive analysis was performed.

Results: Of 427 deaths, 100 (23.4%) were ruled as asphyxia due to unsafe sleep, 43 (10.0%) as SIDS, and 284 (66.5%) as Undetermined cause. Forensic pathologists conformed to agency guidelines in 382 death certifications (89.5%). In 41 deaths (9.6%), the medical examiner ruled the death as SIDS despite meeting unsafe-sleep exclusion criteria in the guidelines, though conformity increased over the 11-year study period. Of 328 deaths (76.8%) with 3 or more risk factors for asphyxia, 13 were ruled SIDS, 89 as asphyxia, and 226 as Undetermined cause. Of SIDS deaths, 30/43 had 1 or 2 risk factors; none had 0 risk factors; the most common risk factor for asphyxia in SIDS was loose bedding or object in the sleep area (38/43). Reasonably conclusive evidence of asphyxia was found in 174 (40.7%); 13 of these were ruled SIDS, 72 as Undetermined, and only 18 of the undetermined cases had a potential competing factor.

Conclusion. Guidelines in one agency were effective at reducing SIDS diagnoses in unsafe sleep environments over time. The interpretation of certain risk factors is subjective and may affect compliance. Undetermined cause is used in many cases where asphyxia is a more appropriate diagnosis. More specific guidelines are recommended for improved infant death certification.

10.2 Saving DNA Samples and Utilizing Genetics to Investigate Sudden Death in the Young: Lessons Learned From The Sudden Death in the Young (SDY) Case Registry

H. MacLeod¹, O. The SDY Case Registry Steering Committee²
¹SDY Case Registry, Elmhurst, Illinois, USA; ²SDY Case Registry, Okemos, Michigan, USA

In a 2013 position paper, NAME recognized the importance of including genetic testing in the investigation of sudden and unexplained deaths and published recommendations for sample collection, storage and shipping. The Sudden Death in the Young (SDY) Case Registry incorporated these recommendations as part of its Biorepository Standard Operating Procedure (SOP). In addition, diagnostic genetic testing donated by Invitae for SDY cases has started to be incorporated into the death investigation. The SDY Case Registry has served as a pilot in the implementation of the NAME Position Paper recommendations and will share lessons learned for further incorporating genetics into understanding sudden death in the young.

The SDY Case Registry is a collaborative effort between the NIH, the CDC and MPHI. The SDY Case Registry currently supports multi-disciplinary teams in 10 states/jurisdictions. For each SDY case that occurs in a funded grantee state, a blood sample in an EDTA (purple top) tube and fresh frozen liver and/or spleen samples are collected. DNA is extracted at the SDY Biorepository at the University of Michigan. If family consent is obtained, DNA is saved for DNA banking, research genetic testing and diagnostic genetic testing. Consented samples from autopsy negative cases are sent to Invitae for diagnostic arrhythmia panel testing. Test results are shared with the ordering pathologist who shares results with the family. Families are notified of the results and referred to genetic counseling and follow-up medical care.

Implementation of the NAME position paper for postmortem samples have proven to be routinely successful for the extraction of DNA with 154/155 (99.3%) of cases yielding high quality DNA. To date, 14 samples have been sent to Invitae for a testing from the grantee states of GA, MN, and NV. Barriers to ordering diagnostic testing for SDY have included: obtaining consent from families, releasing and shipping samples to the biorepository for DNA extraction, training MEs and staff on ordering testing, obtaining National Provider Identifier (NPI) numbers and developing processes for documentation and storage of diagnostic genetic testing results.

Multiple barriers for saving DNA samples and implementing genetic testing into the death investigation have been overcome as demonstrated by the SDY Case Registry experience. Opportunities and resources for implementation in non-SDY states are available including dramatically reduced cost of diagnostic testing, development of recommended practices for high quality DNA extraction and an increase in the number of professionals qualified to discuss genetic testing results with families.

10.3 Modernizing the National Vital Statistics System

K.K. Lewis¹, P. Krautscheid¹, D. Fowler², P. Braun³, M. Warner³
¹CMS Alliance to Modernize Healthcare, MITRE Corporation, Bedford, Massachusetts, USA; ²Office of the Chief Medical Examiner, Maryland, Baltimore, Maryland, USA; ³National Center for Health Statistics, Centers for Disease Control and Prevention, Atlanta, Georgia, USA

The National Center for Health Statistics (NCHS) has engaged the CAMH Federally-Funded Research and Development Center (FFRDC), operated by The MITRE Corporation, a not for profit organization, to assist with efforts to modernize the National Vital Statistics System (NVSS). The CAMH team is conceiving and piloting a next-generation electronic death registration system (Next Gen EDRS), intended to improve quality and timeliness of mortality data. The Next Gen EDRS will address many challenges related to mortality data capture, registration, sharing and

analysis, using a systems approach that is intuitive, mobile, modular, and that enables future evolution to address emerging needs.

10.4 The Use of Skeletal Healing and Entomological Observations to Corroborate Lengthy Post Mortem Interval in an Unusual Case Involving Suicidal Evidence in a Mummified body

W.C. Rodriguez, T.M. King, D.R. Fowler
Office of the Chief Medical Examiner, Baltimore, Maryland, USA

Estimation of the post mortem interval is certainly one of the most difficult questions to answer in death investigation. The longer the actual post mortem interval the more difficult it is to provide an estimate. Mummification of a body due to unique environmental circumstances can act to preserve the body anywhere from months, years or millennia. Once a body has undergone complete mummification its state of preservation can in most cases only be altered by either animal depredation, primarily insects or environmental re-hydration of the tissues allowing natural bacterial degradation to occur. The case to be presented involves the mummified body of a 46 year old Caucasoid male, which was discovered on October 4, 2016. Examination of the body at autopsy revealed the presence of multiple sharp force injuries to the wrist, back and neck. The cause of death was later determined to be the result of multiple sharp force injuries and narcotic (free morphine) intoxication. Complications in the investigation arose when information from law enforcement noted the deceased missing nearly four years. The conflict regarding post mortem interval dealt with the body showing no signs of post mortem insect activity. Forensic anthropological examination of the body revealed two important clues, one being evidence of extraction of a maxillary molar and the presence of heavy fungal growth within the body cavity. Records obtained included a missing person's report dated December 17, 2012, evidence of bank ATM activity a day before and the day of disappearance, and a dental record noting the extraction of a molar on November 8, 2012 and plans for an implant. The presence of the empty second molar socket with marginal healing corroborated the time of death to be consistent with death occurring in December of 2012. Entomological studies have demonstrated that the presence of various fungi will inhibit the activity of demisted beetles. The small microscopic hyphae of fungus have been shown to enter the respiratory system of the beetles essentially obstructing it resulting in death of the beetles. In review it is important that it be recognized that bodies which undergo mummification can be quite resilient in terms preservation. Certain aspects of the post mortem environment must be taken into account which might possibly alter ones perceived notion of expected decompositional changes.

10.5 Warming Up Cold Cases: Recent Fingerprint Initiatives at the FBI Laboratory

B.T. Johnson
Federal Bureau of Investigation, Quantico, Virginia, USA

This presentation will discuss the recent initiatives undertaken by the FBI's Latent Print Units to support the identification of unknown deceased. Partnerships with National Missing and Unidentified Persons System (NamUs), improved workflows with Criminal Justice Information Services (CJIS) Division, a better searching algorithm in the FBI's fingerprint database, Next Generation Identification (NGI), and leveraging the skill set of latent print examiners have led to the identification of over a hundred unknown deceased within the past year alone. Renewed searching has been fruitful in cases from across the US, and in cases as old as 1975. This talk will also discuss what steps Medical Examiner/Coroner Systems can take to ensure their unidentified records have been searched using these new options and opportunities.

The NGI database, housing over 117 million records, is the FBI's fingerprint and palm print repository and AFIS system. Replacing IAFIS in 2013-2014, new algorithms which allow for improved searches of poorer quality cards, searching against more cards contained within the system, and the ability to search each recording (rolled and plain) of a

finger, has increased the likelihood of a successful search. Leveraging the skill set of a latent print examiner for a more focused search of the individual fingers, can also increase the likelihood of an identification. This new technology, compiled with some new workflows, offers the potential for positive results, even when prints were searched multiple times in the past.

With these new tools and resources, the Latent Print Support Unit (LPSU) has partnered with NamUs and the Special Processing Center at CJIS, to provide support to their efforts in identifying unknown deceased. Additionally, the Latent Print Units of the FBI Laboratory are undertaking a cold case initiative, searching prints in past cases submitted to the Laboratory, which may also generate new identifications.

At the end of this talk, the audience should be aware of the efforts carried out to leverage these new options in cold case work, and will understand how to take advantage of these opportunities to request searches unidentified fingerprint records from cold cases or current cases against the FBI's records.

11.1 Sudden Death During Resistance to Law Enforcement Restraint

S.B. Karch

Retired, Berkeley, California, USA

When should an autopsy be considered negative? If grossly identifiable lethal injury is absent, should stress-restraint, force options used, position/weight force, catecholamine excess, or known probability of sudden cardiac death (SCD) be considered a cause of death?

A reasonable estimate would suggest that, when cardiac arrest occurs during law enforcement restraint, at least half the death certificates, will list "while restrained by police," "position" or "weight force," "TASER CEW exposure", or "catecholamine storm" as contributory causes, if not the actual cause of death. The first half of this lecture will review the science of alleged "contributory causes." The second half will discuss the latest developments in the genetics of SCD, and the very high mutation rates observed in stress-related SCD.

SCD with no apparent lesions is presumably arrhythmic in origin. For a lethal arrhythmia to occur, a trigger and substrate are required. Substrates may be obvious, such as total occlusion of a coronary artery, in which case the trigger would be increased oxygen demand. A less obvious substrate is interstitial fibrosis surrounding an old area of infarction. Fibrous tissue can deflect depolarization fronts, leading to reentry and SCD.

Genetic mutations supply a substrate by causing malfunction of membrane ion channels. Two principal types of mutation are recognized: (1) those producing abnormal ion channel function and long QT syndromes, (2) Mutations of the ryanodine gene (RYR2) that disrupt intracellular calcium handling. Exercise and emotional stress, such as occur during Excited Delirium, are triggers causing loss of intracellular calcium homeostasis, resulting in catecholaminergic tachycardia (CPVT). A third type of mutation discovered in 2016 involves the TERCL gene. TERCL mutations can cause cardiac arrest, stress-induced ventricular, and atrial tachycardia, and QT prolongation. The sole known TERCEL trigger is adrenergic stress.

The genetic component of stress-related death is underappreciated. Krex found that in 53% of successive stress/restraint-related SCD (only 10% involved police) had normal hearts, while Topol performed whole exome sequence sequencing on 25 successive SCDs under age 45. Only 5 had apparent anatomic causes. Exome sequencing identified a likely cause in 16%, a plausible cause in 24%. Roughly 1/3 had speculative genetic causes, and roughly 1/3 had no detectable cardiac mutations. Thus 40% of the sample was found to have likely or plausible mutations as a cause of death, suggesting that whole exome sequencing should be performed by for adding "contributors" to the death certificate.

11.2 Disputed Suicides: Investigation and Response by the Medical Examiner's Office

W.M. Gunther, G.R. Robinson

Office of the Chief Medical Examiner, Commonwealth of Virginia, Norfolk, Virginia, USA

Disputed suicides command a disproportionate share of time and resources in the medical examiner/coroner's office. Families who dispute the manner of suicide frequently express doubts about the extent or quality of case investigation; question investigators' conclusions about whether their loved one was suicidal; and may express concern about bias on the part of the authority conducting the investigation. Families describe decedent behaviors prior to death, which they consider inconsistent with suicide; suspicion of another person they deem to be inadequately investigated, who may have caused the decedent harm; scene elements that suggest to them a manner of homicide or accident; absent evidence in cases where they suspect bias, such as video camera record of a prison cell suicide; and the absence of a suicide note. Family doubts can range from valid questions about inadequate investigation to an unyielding form of disbelief based in guilt or shame. This presentation highlights the essential components of good death investigation in cases of suspected suicide, with methods of response to angry, guilty, or ashamed families disputing suicide. Medicolegal investigation incorporates law enforcement investigation and, optimally, medical examiner/coroner staff scene response. Adequate investigation includes a thorough history of the decedent, including emotional state; behavior; medical, mental health, and social history; access to the lethal agency; premises and security; alcohol and drug use; and any digital or handwritten suicide note and/or material. A death investigator interview with next of kin, specifically focused on whether death was intentional, may shape the course of the entire investigation. If the medical examiner/coroner's office can show that they have performed a good fundamental investigation as well as utilizing advanced techniques, this may constitute a valid response to oversight agencies and families. Utilizing deidentified cases from the Virginia OCME experience, including prison suicides, hangings, gunshot wounds, and suicide by car exhaust, this presentation reviews family reasons for disputing suicide, trained methods of responding to these families, and whether the medical examiner/coroner was able to resolve the dispute. Clear procedures for escalating the complaint were made available to the family if the in-person meeting did not produce a resolution; the outcomes of escalation in these cases are reported. The SPIKES protocol for giving bad news, and methods from psychological aikido technique, are discussed in relation to responding to families empathetically and in unison with law enforcement, with successful and unsuccessful outcomes from cases from the Virginia experience.

11.3 Strengthening Medicolegal Death Investigation Data Systems Through Consistent Data Elements and Interfaces

P.A. Braun¹, J. Pinckard², M. Warner¹

¹Centers for Disease Control and Prevention, Hyattsville, Maryland, USA;

²Travis County Medical Examiner's Office, Austin, Texas, USA

Background: Forensic pathologists (FPs) rely on data from multiple sources to diagnose cause and manner of death. These data come in at different times and in different ways and are stored in case management systems—typically electronic systems, paper files, or some combination thereof. Case management systems capture similar data elements, however they store data in different ways, which presents challenges when there is a need to compare or aggregate mortality data across medicolegal death investigation (MDI) jurisdictions. Furthermore, data requestors have different needs and ask for data in different ways to support those needs, which puts additional burden on MDI offices.

Approach: The National Institute of Standards and Technology (NIST) Organization of Scientific Area Committees (OSAC) MDI Subcommittee

met in April 2017 to begin to explore ways to establish data elements and data-element specifications to facilitate timely data sharing and statistical reporting, as recommended by the National Science and Technology Council. During this meeting participants discussed 1) the perceived benefits of making mortality data available from MDI offices in more consistent ways, 2) scenarios under which more real-time data sharing would support MDI needs as well as the needs of Federal data requestors, and 3) examples of how the medical community has approached similar data sharing challenges through Health Level Seven's Fast Healthcare Interoperability Resources (FHIR) standard.

Discussion: The OSAC MDI Subcommittee agreed that it would be beneficial to MDI offices to have more coordinated, consistent, and secure ways to exchange information with one another and more modernized methods to provide information to data requestors without workflow disruption. As a starting point, meeting participants reviewed guidelines written by Gib Parrish, MD and Randy Hanzlick, MD from CDC's Medical Examiner/Coroner Information Sharing Program. The Subcommittee acknowledged that, while the document was dated (January 1995), the content was relevant and generally reflected information captured in their respective case management systems. Meeting participants also discussed ways advances in hardware, software, and network technologies can help make data exchange more efficient and timely. The Subcommittee recommended that the information be presented at the NAME annual meeting to garner early feedback from the MDI community and help guide ongoing discussions about how working with standards development organizations can help strengthen MDI data systems and infrastructure.

11.4 Medicolegal Death Investigator Curriculum Standards Update

S.C. Clark¹, J.M. Jentzen², J. Howe³, M. Ernst⁴

¹Occupational Research and Assessment, Big Rapids, Michigan, USA;

²University of Michigan, Ann Arbor, Michigan, USA; ³Saint Louis

University, St. Louis, Missouri, USA; ⁴Saint Louis University (Ret), St. Louis, Missouri, USA

The purpose of this presentation is to provide an overview of the 2017 update to the national Medicolegal Death Investigator (MDI) curriculum standards. This presentation will highlight the current and possible future practice standards for death investigator education and training programs.

Background

The first medicolegal death investigator training standards were published in the 1996 text; Medicolegal Death Investigator – A Systematic Training Program for the Professional Death Investigator. This curriculum development project was funded and directed by Occupational Research and Assessment, with several members of the National Association of Medical Examiners (NAME) volunteering their time as subject matter experts during the initial DACUM (Developing A Curriculum) workshop and subsequent job analysis and materials validation activities.

The resulting curriculum (MDI training text, student modules, presentation materials and assessments) have been used by thousands of medical examiner and coroners (ME/C) offices nationally and internationally. This MDI curriculum was used to shape the National Guidelines for Death Investigation (NIJ, 1997, 1999, 2011), as well as the founding curriculum of the American Board of Medicolegal Death Investigators (ABMDI). MDI student assessments, written test banks and performance checklists (ORA, 1994) developed as a result of the 1994-1996 work continue to serve as the MDI certification standard for many national, state and local agencies.

The goal of this national revalidation project was to verify the importance of current MDI curriculum standards, and identify new and emerging skill requirements that might be considered for future MDI training and education programs.

Methodology

The survey technique used to conduct this skill standards validation was the three-round Delphi survey. Membership lists from the ABMDI, International Association of Coroners and Medical Examiners (IAC&ME), NAME, Society of Medicolegal Death Investigators (SOMDI) and the Medical Examiner/Coroner Information Network (MECIN) were used to identify 3,163 unique members.

Validation

Each respondent was asked to rate the importance of each skill/knowledge using a five-point scale. Statistics were presented to respondents to consider for each round of surveying. Results indicated that 100% of the 52 introductory death investigator skill requirements (1994-96) are still essential to MDI. Respondents suggested additional skills that may need consideration for future MDI training program design.

Summary

Advances in digital technology over the past 20 years appear to be simply "tools" for the MDI. Critical skills involving communication and interaction with all levels of participant, and the ability to apply both scientific and practical skills remain the hallmark of a successful death investigator.

11.5 WITHDRAWN

11.6 Death Scene Investigations after Natural Disasters and Other Weather-Related Events: A Newly Developed Toolkit

S. Hodge¹, S.D. Redman¹, C.Q. Fromknecht¹, S. Poland¹, A. Issa², T. Bayleyegn², R. Noe²

¹NORC at the University of Chicago, Bethesda, Maryland, USA; ²Centers for Disease Control and Prevention, Atlanta, Georgia, USA

Information collected at the death scene helps death certifiers understand the context for the physical examination of the decedent and ultimately informs cause and manner of death; it also highlights risk factors that public health can target in preparedness prevention strategies. However, because of the complexities of a disaster or other weather-related event, information routinely collected at a death scene may not provide enough context for the medical examiner or coroner (ME/C) to appropriately attribute the death to the event. In recent disasters, considerable disparities were found between the number of disaster-related deaths reported and recorded by state-based vital statistics departments and those reported by other agencies, including local, state, and federal agencies. Enhancing the data collected during disaster-related death investigation could improve the accuracy of reporting disaster-related deaths and future disaster response planning.

NORC at the University of Chicago, in collaboration with the Centers for Disease Control and Prevention (CDC), state and local ME/C, forensic pathologists, death scene investigators, forensic anthropologists, and epidemiologists, is finalizing a new toolkit to assist death scene investigators with disaster-specific data collection. It will ultimately allow death certifiers to more accurately and consistently attribute deaths to disasters.

The toolkit contains both supplemental forms and checklists for frequently occurring disasters and other weather-related events such as hurricanes, tornados, and extreme heat and cold exposures so that investigators can use whichever tool is more useful and easily integrated into their existing death scene investigation processes. Both formats prompt investigators to collect information specific to the disaster or other weather event, that is often available only immediately after the event. Examples of disaster-specific data include information about the decedent (e.g., engagement in activities related to disaster preparation or clean up); and the disaster or event itself (e.g., weather conditions or ongoing alerts).

A training resource is also being created to assist ME/Cs in preparing their staff to investigate disaster-related deaths. Incorporating these new tools into a jurisdiction's standard operating procedures will not only help improve the disaster-specific information available to the death certifier but by extension it will also improve state and local public health departments' identification of risk and preventive factors associated with disaster-related

deaths and refine strategies to prepare, respond, and recover from future disaster events. This presentation will provide an overview of the new toolkit and forthcoming training to explore ways in which the ME/C may wish to use it in their offices.

11.7 Modern Faces of Death: Considerations of Death Investigation in Today's Social Media Landscape

B.C. McCleskey¹, B. Yates², D.S. Atherton¹

¹University of Alabama at Birmingham, Birmingham, Alabama, USA;

²Jefferson County Coroner/Medical Examiner's Office, Birmingham, Alabama, USA

Faces of Death is a pseudo-documentary film produced in 1978 containing a mixture of real and fake footage of human deaths. It gained popularity through the 1980s and has earned a unique position in the history of communication and distribution of recorded death footage. In the 1990s, the Internet revolutionized the media landscape; all kinds of death footage became freely accessible through simple website repositories or keyword searches. Recently, the Internet and camera-enabled cellular phones have provided a simple means for individuals to broadcast actions in real-time, and reports of livestreamed footage of individuals committing violent acts, some leading to death, are becoming increasingly common. The psychology behind this emerging phenomenon is one of great interest, but inevitably this footage provides a valuable source of investigative material during death investigations for coroners and medical examiners. There are a number of investigative challenges including simply identifying that these type of data are available and acquiring that data from Internet and social media sources. We report a case of a 22 year old male who died of a contact-type gunshot wound of the right side of the head. Two other individuals were with the decedent at the time of his death. These witnesses indicated that the decedent was depressed, had threatened suicide in the past, and became upset with his girlfriend at which time he picked up a handgun and shot himself. Further investigation by law enforcement revealed the decedent had been livestreaming during the evening of his death and the events that led up to the shooting. The livestream footage was acquired and reviewed. The multimedia mobile application's file showed the decedent drinking alcohol, seemingly playfully interacting with his friends, and acting out multiple positions with both he and his friend holding the gun. The footage then showed the decedent abruptly cocking the gun, placing it to the side of his head, and pulling the trigger. These sorts of cases present a number of challenges and opportunities during the investigative and examination stages of death investigation, as well as during the manner of death designation. Social media sites and app-based image messaging platforms allow for more day-to-day life to be recorded than ever before, and can be valuable resources in modern death investigation.

POSTER PRESENTATIONS

P1 Detection of Methanol in a Subdural Hematoma after Embalming.

B.E. Criss¹, R.H. Powers², R.G. Topmiller³, D.E. Dean³

¹University of Cincinnati, Cincinnati, Ohio, USA; ²University of New Haven, West Haven, Connecticut, USA; ³Hamilton County Coroner's Office, Cincinnati, Ohio, USA

Analyses of subdural hematomata have been traditionally used to determine the ante mortem level of drugs and/or ethanol based on the assumption that the sequestered nature of materials within the hematoma makes them less subject to metabolism or degradation than in the freely circulating blood. Results derived from hematomata are presumed to more closely resemble the drug or alcohol concentration at the time of injury than those determined from postmortem blood. In a cautionary note, we report the case of an 87-year-old woman whose death was not reported to the coroner's office until after her body had been embalmed. The gross

autopsy examination documented significant hypertension as well as a traumatic brain injury with a subdural hematoma causing a mass effect. Testing of the subdural clot revealed methanol (51.8 mg%), without additional analytes. There was no indication that the decedent had been poisoned with methanol. We postulate that methanol diffused into the clot after introduction with the embalming solution (consisting only of methanol and formaldehyde; no ethanol, isopropanol or acetone was contained in the preparation used). These findings suggest two cautions should be exercised regarding postmortem hematoma findings. First, methanol can be present in such postmortem samples in the absence of other low molecular weight alcohols (LMWAs) and acetone, and yet not represent a methanol poisoning; secondly, that the interior of hematomata are not necessarily "protected space" from the postmortem diffusion of at least methanol, and potentially other LMWAs. A search of the English literature for cases of subdural hematomata in embalmed decedents failed to reveal any previously published reports with analogous results. Therefore, to our knowledge, this is the first case of the detection of methanol in a postmortem, previously embalmed subdural hematoma.

P2 Public Transportation Deaths in Chicago from 2014 to 2016

M.D. Eckhardt¹, E. Eason²

¹Cook County Medical Examiner, Chicago, Illinois, USA; ²Cook County Medical Examiner Office, Chicago, Illinois, USA

Public transportation is a vital service in Chicago with millions of people utilizing it every day. There are 2 main modes of transportation serving Chicago including the elevated or "L" train which runs throughout Chicago and the public bus. This study will seek to examine deaths that occurred on the Chicago Transit Authority (CTA) from 2014 to 2016, analyzing them by both type of death and mode of transportation on which the death occurred.

A search of the Cook County Medical Examiner's Office database from 2014 to 2016 was done to find deaths whose circumstances were related to the CTA. There were 37 deaths related to public transportation that occurred in Chicago between 2014 and 2016 that were investigated by the Cook County Medical Examiner's office in which the decedent died while on the mode of transportation. Of these, 6 were female and 31 were male. The age range was 21 to 82 and the racial demographics showed 22 of the decedents were black and 15 were white.

Twenty-three of these deaths were certified as Accident due to drug overdose, with 13 found on the "L" train and 9 found on the bus. A breakdown of the drugs taken demonstrated fentanyl and fentanyl analogues, either alone or in combination was involved in the majority of cases (72%) and ethanol was involved in 7 of the cases. Interestingly, 9 of the 13 who were found dead on the train were found on the Blue line, which is a 24-hour train with service to O'Hare airport, and 8 of those 10 were found at O'Hare airport, the last stop on the line, between the late evening to early morning. A closer look at these cases showed the decedents were all male and overwhelmingly white (7/8). In a few of these cases, the decedent was either known or speculated to be homeless, which would make the blue line a more common line owing to the fact that it is a 24-hour line.

Fourteen of the cases were certified as Natural, with a cardiac cause in 13 of these cases and one case of acute asthma exacerbation.

Finally, there was one homicide of a 25-year-old black female who was stabbed to death by her boyfriend on the Red line.

This study will provide a detailed analysis of these cases and act as a resource for CTA related research in the future.

P3 Fatal Bioprosthetic Root Fungal Endocarditis in a 14-Year-Old Girl

J.D. Berg¹, R. Rabah², K. Snell¹

¹USD Sanford School of Medicine, Sioux Falls, South Dakota, USA;

²University of Michigan Health System, Ann Arbor, Michigan, USA

Prosthetic valve and aortic root endocarditis (PVE) is associated with high mortality and morbidity and may occur in the perioperative period or later as a consequence of secondary hematogenous seeding from a distant infectious focus. Causative organisms include streptococci, staphylococci and enterococci, thus antibiotics prophylaxis is recommended for these patients during dental procedures and other surgeries with increased infection risk. Fungal PVE is less common, with candida and aspergillus being the most frequently identified organisms. We present the case of a 14-year-old girl with a complicated past medical history of truncus arteriosus and coarctation of the aorta status post multiple cardiac operations, the most recent surgery was 5 months prior to death and included redo neo-aortic root and ascending aorta replacement with 25 millimeter Medtronic Freestyle bioprosthetic root, modified Konno procedure and replacement of right ventricle to pulmonary artery conduit with 25 millimeter pulmonary allograft with Gore-Tex proximal extension. She had been in her normal state of health until experiencing intermittent low grade fevers, nausea, and respiratory difficulty for a 1 week duration that had necessitated the patient stay home from school. On the final day of life, the patient had increased respiratory difficulty and was taken to the hospital. In route, the patient lost consciousness and was found to be in asystole upon presentation to the emergency department. At postmortem examination the heart was enlarged with left ventricular hypertrophy and dilation. The aortic bioprosthesis appeared dusky with loosely adherent vegetation partially occluding the coronary ostia composed of numerous septated hyphae. The fungal growth was limited to the bioprosthetic root and valve without invasion of surrounding tissue or extension to the native aorta, left ventricular outflow tract tissue, other valves or the right ventricular conduit. The left ventricle demonstrated hypertrophic changes, patchy necrosis with neutrophilic inflammation consistent with acute myocardial infarction and additional areas of fibrosis indicative of previous older infarcts. GMS stain highlighted rare fungal elements in small coronary arteries, pancreas, adrenal gland, and peripheral pulmonary vessels consistent with fungal sepsis. The exact type of fungus can't be further determined since the postmortem iliac blood cultures were negative. The morphologic findings were not characteristic for candida or aspergilliosis. Fungal endocarditis is a very rare but possibly late complication of prosthetic valve surgery and must be in the postmortem differential so as to ensure proper collection of culture specimens.

P4 Peculiar Patterns of High-Voltage Electrocutions

A.R. Perkins¹, S.S. Rivers², L. Chrostowski²

¹University of South Florida, Tampa, Florida, USA; ²Hillsborough County

Medical Examiner's Office, Tampa, Florida, USA

Electrocution is an uncommon cause of death in the United States; but still remains a leading occupational hazard, particularly among those working in the construction industry. Both low and high voltage current exposure, defined as less than and greater than 600 Volts, respectively, can lead to an individual's death. Unlike those seen in low-voltage electrocutions, where external wounds may be minimal to absent, injury patterns in high-voltage electrocutions are often severe, presenting little diagnostic challenge to the experienced forensic pathologist. Entrance and exit site wounds (commonly on the hands and feet, respectively), multiple and confluent third-degree burns, along with limb amputations are frequently noted on external examination. Despite the majority of cases showing these changes, atypical patterns of injury or a complete lack thereof, can be seen. We present multiple cases of high-voltage electrocution deaths that demonstrate atypical patterns of injury and/or distracting additional injuries on examination including scalding pattern burns, unusual entrance and exit wounds, and cases that lacked external evidence of electrocution.

It is important when approaching a case where electrocution is apart of the differential for the cause of death, that while high-voltage electrocutions often demonstrate signature and severe injury patterns, to be aware that an individual may exhibit uncharacteristic wounds or lack injuries. These atypical presentations, while uncommon, do not exclude electrocution as the cause of death, especially when the scene and investigation are supportive.

P5 Death Due to Chikungunya - Forensic Case Report

W. Xing¹, S. Souccar²

¹Department of Medical Examiner-Coroner Los Angeles, Los Angeles, California, USA; ²St George's University, Grenada, Grenada

Chikungunya should be highly suspicious in patients who have history traveling from affected areas particularly if they are elderly, neonates or have other co-morbidity. Mosquito born illnesses, such as Chikungunya must be ruled out when establishing the cause of death as it may resemble other viral infections. While Chikungunya can rarely cause death in the United States, it may easily be mistaken for other illnesses. History along with a clinical presentation of the patient are a crucial part while arriving at an accurate diagnosis. Autopsy and microscopic tissue examination can be unequivocal in their findings. Therefore appropriate testing must be done when establishing the cause of death. SERO and WHO have proposed specific criteria and testing to establish the diagnosis of Chikungunya and should be followed when noted travel from affected areas is in place. There are laboratory testings for confirmation of diagnoses, such as Viral Isolation and ELISA, however RT-PCR is an efficient and quick way to check. Here is a case of a 63-year-old man with other risk factors that was misdiagnosed; the initial laboratory testing of IgG antibodies was negative. Initial forensic examination and finding showed that the cause of death was still pneumonia and septic shock. The Pathologist at the coroner's office then requested RT-PCR testing on a blood sample, which returned positive and the cause of death was attributed to Chikungunya, proving that the similarities between it and other symptoms can cause it to be overlooked as a cause of death.

P6 Sudden Cardiac Death While Scuba Diving: Hypertrophic Cardiomyopathy and the Importance of Histologic Evaluation in Cases with Subtle or Absent Cardiac Hypertrophy

L.M. Schuppener¹, R.F. Corliss²

¹University of Wisconsin-Madison Hospital and Clinics, Madison,

Wisconsin, USA; ²University of Wisconsin Hospital and Clinics, Madison, Wisconsin, USA

Background:

Hypertrophic cardiomyopathy (HCM) is an autosomal dominant genetic disease that carries an increased risk of sudden cardiac death. The diagnosis of HCM is often initially based on the gross finding of prominent asymmetric septal hypertrophy; however, cases of HCM without asymmetric septal or even prominent ventricular hypertrophy have been described, constituting the "non-hypertrophic variant." In cases with minimal or absent gross cardiac hypertrophy, the histologic findings of myocyte disarray, interstitial fibrosis, and vascular abnormalities may be the only diagnostic feature identified through routine autopsy. As with other hereditary arrhythmia syndromes, diagnosis of HCM in sudden unexpected deaths has significant implications to relatives of affected individuals.

Methods:

An autopsy and a review of the literature were performed.

Case Report:

A 54-year-old man without known medical history was recovered unresponsive in 11 feet of water while scuba diving. Investigation revealed functional diving equipment with air remaining. No significant trauma was identified externally. On internal examination, the sphenoid sinus, lungs

and stomach were without significant fluid accumulation. The 420 g heart had several remote infarcts and mild asymmetric septal hypertrophy (2.3 cm interventricular septum) with 1.9 and 0.6 cm left and right ventricles, respectively. Histologic sections showed florid myocyte disarray within the anterior and posterior septum, left and right ventricular hypertrophy, and interstitial fibrosis with prominent regional intramural vasculopathy. Blood and urine were negative for drugs and alcohol. Other findings at autopsy included moderate coronary atherosclerosis with up to 50% stenosis, hepatomegaly, and a benign renal papillary adenoma.

Results:

The cause of death was ruled fresh water drowning while scuba diving, associated with previously undiagnosed HCM. No genetic testing was performed on the deceased; however, due to the genetic nature of HCM, his only first degree relative (sister) was contacted and it was recommended that she be screened for HCM. An echocardiogram was performed and was within normal limits. A CT scan and genetic testing were offered but declined. The deceased had no children and no other relatives were tested.

Discussion:

A diagnosis of HCM should be considered in cases of suspected sudden cardiac death, and may present with subtle or absent ventricular or septal hypertrophy. Histologic evaluation of the heart is needed in these cases to initially identify HCM. If HCM is diagnosed at autopsy, first-degree relatives of the deceased should be notified and offered genetic counseling and screening to mitigate the chances of sudden cardiac death in affected family members.

P7 Farm Machine Related Deaths in Alberta from 2000 - 2015.

J.A. Andrews¹, E. Brooks-Lim²

¹University of Alberta, Edmonton, Canada; ²Alberta Office of the Chief Medical Examiner, Edmonton, Canada

Alberta is a landlocked Canadian province bordered by the Rocky Mountains on the west, expansive prairies to the east as well as south, and the Canadian arctic to the north. Over the past 100 years, there was a trend for Alberta farms to amalgamate resulting in a single owner maintaining a larger breadth of land. Consequently, large machinery plays integral to a single owner cultivating on average more than 1,000 acres of land. As with other industries, such as manufacturing, the presence of heavy machinery introduces further risk of morbidity and mortality. In a detailed retrospective analysis, this poster will examine the demographics, characteristics, and trends of machine related farm deaths in Alberta from 2000 to 2015.

Initial data for agricultural related deaths were obtained through the Alberta Office of the Chief Medical Examiner. Inclusion criteria: death directly related to farm accident; involved farm machinery; any age or gender; and death occurred either during work or recreational activities. Exclusion criteria included: homicide or suicide manners of death; and death occurred on or around a machine but was not related to the machine. We collected multiple data points surrounding demographics, circumstances of death, machinery involved, and mechanism of death.

A total of 308 accidental farm deaths occurred in Alberta during the examined period of which machine related accidents resulted in 54% of deaths and non-machine accidents accounted for the other 46% of deaths. For machine related deaths a total of 28 deaths occurred in individuals less than 18 years old (17%); 86 deaths occurred in individuals between the age 18 to 64 (52%); and 52 deaths occurred in individuals over the age of 65 (31%). The vast majority of individuals killed by machines were the farm owner or family member (84%). Tractors were the deadliest object on the farm (47 deaths), followed by off road vehicles

(22 deaths). Deaths related to machines most commonly involved being pinned/struck (33%), vehicle rollover (22%), runover (17%), and entangled in machinery (13%).

During the sixteen-year period examined, the majority of agricultural deaths were farm family members and involved a piece of machinery. In addition, the clear majority of deaths occurred in males, in sunlight hours, during work related activities. Overall, this data provides a more complete view of farm machine related deaths and will assist in future efforts to reduce agricultural related deaths.

P8 Death Related to Fistulas Involving the Gastrointestinal and Cardiovascular Systems

A.J. Medwick, J.A. Prahlow

Western Michigan University Homer Stryker MD School of Medicine, Kalamazoo, Michigan, USA

Gastrointestinal tract fistulas are relatively uncommon and can be congenital or acquired. Fistulas may communicate with a variety of anatomic locations, including body cavities, the skin, and other organ systems. Acquired fistulas which communicate with the cardiovascular system are of particular concern, as they may be associated with significant morbidity and mortality. This study reports on 3 cases of acquired, post-surgical fistula formation involving the gastrointestinal and cardiovascular systems.

Case 1 - A 57-year-old man experienced sudden cardiac death shortly after having a permanent pacemaker placed for atrial fibrillation. Approximately 2 years earlier, he underwent surgical resection of his esophagus for cancer, and he had a diaphragmatic hernia repair several weeks before death. He also had hypertensive and atherosclerotic cardiovascular disease and emphysema. At autopsy, the cause of death was determined to be upper gastrointestinal tract hemorrhage due to a gastro-left atrial fistula which developed as a complication following surgeries for esophageal cancer.

Case 2 - A 67-year-old female with severe chronic obstructive pulmonary disease (COPD), as well as a thoracic aortic aneurysm for which she had undergone aortic reconstruction with graft placement, presented to the hospital with massive hematemesis with associated breathing difficulties. Prior to dying, an upper endoscopy revealed a probable esophageal fistula thought to be communicating with the respiratory system. At autopsy, the fistula was found to be communicating with the aorta.

Case 3 - A 51-year-old woman was found unresponsive at home. All resuscitative efforts were unsuccessful. The case was referred for medicolegal autopsy. She had a past history of COPD, gastric bypass surgery, and relatively recent bacterial pericarditis, which required drainage and antibiotic therapy. Autopsy revealed the presence of a gastric fistula involving and traversing the left hemidiaphragm to involve the posterior wall of the left ventricle of the heart. Approximately 500-1000 mL of dark blood intermixed with gastrointestinal contents was present within the stomach and proximal small intestines, but no fresh-appearing hemorrhage was evident.

Postoperative gastrointestinal-cardiovascular fistulas are relatively rare, but can result in significant morbidity and mortality. They may develop following gastrointestinal tract or cardiovascular surgery. Clinicians are advised to be aware of these rare, but often fatal, post-operative complications. The cases serve to remind investigators of the importance of obtaining pertinent detailed medical/surgical history as a part of an adequate death investigation. Forensic pathologists are reminded that proper dissection techniques and photographic documentation are essential when confronted with such cases.

P9 Sarcoidosis Deaths in Wayne County, Michigan: A 20-year Retrospective Study

M. Webb¹, K.S. Conway¹, M.K. Ishikawa¹, F.J. Diaz²

¹University of Michigan, Ann Arbor, Michigan, USA; ²Wayne County Medical Examiner's Office, Detroit, Michigan, USA

Sarcoidosis is a disease of unknown etiology characterized by the formation of non-caseating granulomas in various organ systems. This paper reviews 84 cases of natural death in decedents with sarcoidosis between the years 1996 and 2017 and autopsied at the Office of the Wayne County Medical Examiner in Detroit, Michigan. Each case was reviewed based on information available in autopsy reports. The median age of decedents was 44 years (29 – 59 years of age). Blacks comprised 95% of the cohort, and 52% were female. Sarcoidosis or direct sequelae of sarcoidosis were the cause of death in 79% of cases. 29% of patients had a documented history of sarcoidosis. 70% of patients had evidence of systemic sarcoidosis. The most common sites of involvement were lungs or hilar lymph nodes (92%), heart (45%), liver (39%), and spleen (30%). Only pulmonary and cardiac disease had significant rates of isolated involvement, with 26% of decedents having isolated pulmonary disease and 4% of decedents having isolated cardiac disease. Decedents with cardiac involvement, when compared with decedents without cardiac involvement, were more likely to have no documented history of sarcoidosis (87% vs. 59%, $p=0.004$), more likely to have died of a sarcoidosis-related cause (97% vs. 65%, $p<0.001$), and died at a younger mean age (41 years vs. 46 years, $p=0.001$). Our findings suggest that sarcoidosis is significantly under diagnosed among our affected demographic and cardiac involvement is a uniquely poor prognostic factor.

P10 Spontaneous Hepatic Rupture in a Pregnant Woman with Preeclampsia: An Autopsy Case

J. Park¹, J. Na², Y. Oh¹, Y. Lee¹, S. Oh¹, H. Kim¹

¹National Forensic Service Gwangju Institute, Jangseong, Korea, Republic of; ²Chonnam National University Hospital Biomedical Research Institute, Gwangju, Korea, Republic of

Spontaneous hepatic rupture which is a complication of hypertension in pregnancy is rare, but it shows high maternal and perinatal mortality. It is frequently associated with the thirties, multipara, severe preeclampsia or HELLP syndrome (clinical syndrome with hemolytic anemia, hepatic enzyme increase, thrombocytopenia). The authors experienced an autopsy case that twin pregnant 42-year-old woman at 36 weeks gestational age suffered sudden developing and rapid progressing hypertension in pregnancy and she died because of spontaneous hepatic rupture despite emergent operation.

She took sudden abdominal pain of right upper quadrant (RUQ) after waking up in early morning. She had history of stillbirth in 23 gestational week 2 years ago and was being treated with insulin for diabetes diagnosed afterwards. Her weight (102 kg and 109 kg), blood pressure (156/91 mmHg and 157/96 mmHg) and her urine protein (+/- and 4+) measured in regular check-up at 2 weeks and 1 day before the onset of the symptom and preeclampsia was suspected. When she visited ER with the abdominal pain, her BP was 110/70 mmHg. After conducting blood and urine analysis, emergent caesarean section was performed. She gave birth to one live baby and one stillborn baby, and surgery was performed in hepatic capsular rupture with hemoperitoneum found during the surgery. After surgery, sudden cardiac arrest occurred. Emergency measures such as cardiopulmonary resuscitation (CPR) were conducted, but she did not recover and expired. According to guardian of the deceased, the deceased did not have history of even the slightest trauma in her whole body, especially including abdomen.

Autopsy revealed that capsule in right lobe of liver adjacent to diaphragm was torn in various directions and massive coagulated blood was found between liver capsule and parenchyma. After resection of liver, there was no specific finding like bleeding in parenchyma and histological

examination of liver parenchyma revealed multifocal necrosis. It also revealed that hypovolemic signs such as weak postmortem lividity, and palor of skin, conjunctiva and solid organs.

It is our opinion that close examination of the trunk and liver for classification of cause of rupture, and investigation of past medical history such as preeclampsia are needed during postmortem examination in all cases of pregnant women with hepatic rupture or her fetus. To our best of knowledge, this fatal complication of pregnant women is not yet presented with postmortem examination in Korea so the authors report to share the knowledge with our case.

P11 Unknown Cause of Recurrent Metabolic Acidosis Diagnosed by Autopsy

M.H. Schild, L.A. Havrilla, W.T. Harrison, T.A. Sporn

Duke University Medical Center, Durham, North Carolina, USA

Early diagnosis and treatment of ethylene glycol poisoning can prevent considerable morbidity and mortality. Sequelae of ingestion include central nervous system depression, cardiopulmonary compromise, and renal insufficiency. Ethylene glycol itself is not toxic; however, its organic acid metabolites cause considerable metabolic derangement and organ damage. Laboratory findings include an increased anion gap metabolic acidosis, increased osmol gap, calcium oxalate crystalluria, and detectable ethylene glycol in the serum. Administration of ethanol or fomepizole, sodium bicarbonate, and hemodialysis are mainstays of treatment.

We present a 38 year old female with a history of alcohol abuse, prescription drug abuse, seizures, and chronic kidney disease who was admitted multiple times for lactic acidosis, acute kidney failure, and altered mental status. Laboratory values revealed a high anion gap metabolic acidosis, an elevated lactic acid, and a normal osmol gap. Extensive toxicology workups did not detect ethanol, methanol, isopropyl alcohol, ethylene glycol, heavy metals or volatile gases. Her prescription Depakote levels were low, thiamine was elevated, and cyanide and metformin levels were within normal limits. She was treated empirically for beta-blocker and cyanide toxicity without improvement and was placed on hemodialysis for kidney failure, subsequently passing away. The differential diagnosis at the time of death included unknown toxicity, unspecified metabolic disorder, and unspecified mitochondrial disorder. The family was concerned about a possible genetic mitochondrial disorder causing the patients recurrent lactic acidosis and consented for an autopsy. Autopsy findings included microscopic intravascular and perivascular dumbbell shaped crystals, consistent with calcium oxalate monohydrate crystals, confirming the diagnosis of ethylene glycol toxicity. This case demonstrates the difficulties in identifying ethylene glycol toxicity clinically and the importance of autopsy in this diagnosis. A normal osmol gap does not exclude ethylene glycol poisoning. Ethylene glycol and its first metabolite, glycoaldehyde, contribute to a high osmol gap, however, the later metabolites, glycolic acid and glyoxylic acid do not. Therefore, the osmol gap is raised in the initial stages of ethylene glycol toxicity, but decreases later while the anion gap increases. Ethylene glycol has a half-life of 2.5-8 hours and positive ethylene glycol toxicology results depend on the time of ingestion. Measurement of glycolate may help the diagnosis following metabolism of ethylene glycol, however, this analysis is not readily available in most hospital laboratories. Furthermore, metabolites of ethylene glycol can cross-react with the most common lactic acid assays, leading to falsely elevated serum lactate levels.

P12 The Fungus Among Us: A Fatal Case of Invasive Aspergillosis in a Non-Transplant Patient

S. Reed, K. Jasnosz

Allegheny General Hospital, Pittsburgh, Pennsylvania, USA

Invasive aspergillosis is a life-threatening infection with a striking mortality rate that varies according to anatomic site of involvement. The overall case fatality rate (CFR) for invasive aspergillosis has been estimated at

58%; central nervous system involvement is nearly uniformly fatal with a CFR of 99%. The most commonly affected patients include those with hematologic malignancies, solid organ transplants, and profound immune compromise such as HIV/AIDS, with a much smaller percentage of cases (around 1-2%) seen in patients with chronic obstructive pulmonary disease (COPD).

This was a 65 year old Caucasian female with a medical history of oxygen-dependent COPD and acute on chronic respiratory failure. She had recently been diagnosed with influenza pneumonia, which exacerbated her respiratory failure such that she required a tracheostomy and placement in a long-term care facility. Approximately one month later, she developed cavitory lung lesions that were suspicious for tuberculosis. Her condition was declining despite treatment with multiple antimicrobial agents, and she was transferred to our facility for advanced care. She developed mental status changes, sepsis and multiorgan failure. Despite increased ventilator, hemodynamic and dialysis support, she unfortunately passed away.

An unlimited autopsy revealed extensive bilateral pulmonary aspergillosis, including a 6 cm fungal abscess of the right upper lung lobe, multiple associated pulmonary infarcts, fungal pleuritis, and diffuse organizing pneumonia. The patient's brain had several hemorrhagic infarcts in the left frontal lobe and thalamus, with associated fungal hyphae and mycotic vasculitis. Lung tissue cultures grew *Aspergillus fumigatus*. The cause of death was overwhelming pulmonary aspergillosis with spread to the central nervous system.

Considerations for disseminated aspergillosis are appropriate in, but not limited to, a specific patient population, namely those status post solid organ or bone marrow transplant. This was an unusual case of aggressively invasive aspergillosis with a considerable organism burden in a non-transplant patient. This patient was immunocompromised from the standpoint of having long-standing respiratory disease, necessitating inhaled corticosteroids and eventually tracheostomy. Her cavitory lung lesions initially raised concern for tuberculosis, rather than disseminated aspergillosis, given her residence in a long-term care facility. The source of the fungal infection was unclear. This case illustrates the importance for an expanded differential in an immunocompromised patient.

P13 Sudden Cardiac Death in the Young: A Case-Based Discussion

S.C. Thomas¹, S. Strauch Rivers², J. Dierksen¹, L. Chrostowski², C. Dominguez¹

¹University of South Florida, Tampa, Florida, USA; ²Hillsborough County Medical Examiner, Tampa, Florida, USA

Sudden cardiac death in the young (SCDY) accounts for approximately 1-2% of all sudden deaths within the United States. The most common etiologies implicated include cardiomyopathy, coronary artery anomaly, obstructive coronary disease, myocarditis, valvular disease, channelopathy and aortic disease leading to dissection or rupture. Sudden cardiac death can be defined as an out-of-hospital death caused by any cardiac condition that occurs within one hour of symptom onset, however other definitions based on longer time frames and circumstances exist. We present three cases of SCDY, occurring within the past year at our institution. The first case involves a 21-year old young woman, admitted to the hospital for peripheral edema and abdominal pain. She suffered a seizure while showering, with subsequent cardiorespiratory arrest. Her medical history was significant for a recently treated *Helicobacter pylori* infection three weeks prior. Autopsy revealed pale, firm myocardium with amyloid deposition seen microscopically. The second case was a 3-year old boy, with a 1-day history of nausea, vomiting and abdominal pain who had a cardiac arrest following a seizure-like episode. Autopsy showed an enlarged heart, incidental intestinal intussusception, and negative viral studies. Microscopically, the heart had a diffuse lymphocytic infiltrate, consistent with myocarditis. The last case depicts a 2-year old previously healthy boy noted to stop breathing while sleeping at night. His medical

history was significant only for nebulizer usage when sick. Significant autopsy findings revealed pearly white endocardial lining within the left ventricle, extending to the aortic valve, with no associated outflow obstructions or other congenital abnormalities identified. Endocardial fibroelastosis, diffuse type was diagnosed following microscopic analysis. The diagnostic process of these infrequently seen cardiac-related deaths in the young may initially present with difficulty. Cardiac amyloidosis is scarcely reported in the young without a known inherited disorder or hematologic malignancy. Our patient's associated *H. pylori* infection may have contributed, as it is a well-known chronic inflammatory process. Endocardial fibroelastosis can be seen in a variety of congenital and acquired cardiac-related conditions, which creates a diagnostic predicament when no discrete underlying cause is found, as in our case. Lymphocytic myocarditis, although uncommon, is not rare and is usually associated with a viral agent; however no identifiable viral agent has been discovered in our case thus far. Each case, our thought process and the steps leading toward our understanding of the causes of death will be discussed.

P14 Healed Fracture of Superior Horn of Thyroid Cartilage in Autoerotic Asphyxia: An Indication of Prior Activity? A Case Report Utilizing 3D Scanning and Printing of the Larynx

M. Eckhardt¹, K.J. Moore², K. Shah³, M. Bois³, M.J. Joseph³, P.T. Lin³
¹Northshore University Health System, Evanston, Illinois, USA; ²Mayo Clinic Health System, Owatonna, Owatonna, Minnesota, USA; ³Mayo Clinic, Division of Anatomic Pathology, Rochester, Minnesota, USA

We report a case of autoerotic asphyxia in an adult man with no known prior history of autoerotic activity. However, the presence of a healed fracture of the superior horn of the thyroid cartilage is suggestive of prior autoerotic asphyxia activity. 3D scanning technology coupled with 3D printing of the larynx was used to permanently document the laryngeal findings.

The decedent is a 45 year-old man who was found on the floor of his bedroom with a belt ligature around the neck. The belt was thought to have been suspended from the door frame. A nearby towel and barbell weight may have been components of an "escape mechanism". Another rope ligature was loosely wrapped around the decedent's wrists, scrotum and penis. Nearby items include a cell phone, computer with monitor and a mirror. There was no history of depression or suicidal ideation.

Autopsy was notable for the presence of fixed lividity of the lower extremities in a "stocking-pattern" and an incomplete ligature furrow around the neck. There were no conjunctival or facial petechial hemorrhages, hemorrhages of the strap muscles of the neck, or recent laryngeal or hyoid fractures. However, there was a healed fracture of the right superior horn of the thyroid cartilage.

Autoerotic asphyxia is a means of sexual gratification in which the person employs a mechanism to induce hypoxia and heighten arousal during solo sexual activity. Death occurs in this setting when there is loss of consciousness, thus preventing the person from ceasing the asphyxia. In many cases there is an escape mechanism that should allow the asphyxia to stop after loss of consciousness and for whatever reason this fails.

The majority of autoerotic asphyxia deaths occur in young males. The scene is usually a private location and commonly has an element of fetishism (ex. pornography, bondage, cross-dressing). Autopsy findings are nonspecific and similar to classic asphyxia deaths including petechiae and visceral congestion. Thyroid cartilage fracture and vertebral fractures can occur but are less common.

3D scanning and printing technologies are advancing rapidly and have numerous potential uses in forensic pathology, such as the creation of 3D

images that can be manipulated on a computer screen or physical models that can be handled in court to facilitate understanding of complex anatomical specimens. This technology also allows permanent documentation of specimens in their original state, prior to dissection and histologic sampling, allowing other experts to perform independent evaluations.

P15 Fat Embolism Syndrome in a Patient with Duchenne Muscular Dystrophy Following Minor Trauma: A Case Report

T.J. Danielsen, J. Barnard

Southwestern Institute of Forensic Sciences (University of Texas-Southwestern), Dallas, Texas, USA

Introduction:

Duchenne muscular dystrophy (DMD) is an X-linked recessive disorder caused by a mutation encoding the dystrophin protein on the short arm of the X chromosome. Dystrophin is an integral structural protein required for skeletal muscle contraction. DMD affects approximately 1 in 5000 live male births and results in progressive skeletal muscle degeneration and fatty replacement. Fat embolism syndrome (FES) is the systemic manifestation of fat droplets impairing microcirculatory blood flow and often results in pulmonary and neurological symptoms. Although typically occurring in the setting of a long bone fracture, orthopedic surgery, or a cosmetic procedure, such as liposuction, FES has also been documented in patients with DMD following only minor trauma. Patients with DMD are particularly vulnerable to traumatic injuries, ranging from minor trauma to bone fracture, due to their progressive weakness and invariable immobility. Due to the fatty replacement of skeletal muscle in these patients, soft tissue trauma can potentially cause FES.

Case Report:

We present the case of an 18-year-old male with a clinical history of DMD who experienced a short fall from a broken wheelchair lift. He fell approximately two feet and sustained minor trauma to his posterior trunk that was characterized as focal redness. He presented to the hospital neurologically altered and in respiratory distress shortly thereafter. His condition worsened and he was transferred to the intensive care unit (ICU). He continued to deteriorate and he was pronounced dead hours following the fall. The presentation and clinical course raised the suspicion of FES. At autopsy, the gross examination showed no contusions or significant injury over the posterior trunk. The autopsy also revealed diffuse and extensive fatty replacement of the skeletal musculature and biventricular dilation of the heart. Microscopic examination provided confirmation of fat emboli in the lungs, kidneys, brain, and heart.

P16 Fatal Achalasia: A Case of Sudden Death and a Review of the Literature

A.M. Laib¹, I. Scordi-Bello²

¹University of Cincinnati Medical Center, Cincinnati, Ohio, USA; ²The Office of Chief Medical Examiner of New York City, New York, New York, USA

In forensic pathology, esophageal disease is rarely determined to be the cause of sudden death at autopsy. When encountered, the most common fatal esophageal conditions include hemorrhagic lesions such as esophageal varices, infectious ulcers, and perforating Barrett's esophagus. Achalasia is a rare esophageal dysmotility disorder with impaired peristalsis and incomplete relaxation of the lower esophageal sphincter, which can result in the development of megaesophagus (width >7-8cm). While there have been over 40 reported cases of acute respiratory distress as a complication of megaesophagus, only a small number of those cases experienced cardiac or respiratory arrest, usually with a non-fatal outcome due to successful resuscitation.

We report the case of a 41-year-old male with no known history of esophageal disease who was found deceased by his wife after spending

the night asleep on the sofa. He had occasional heartburn but reported no discomfort or distress prior to falling asleep. He had consumed alcoholic beverages but was not felt to be intoxicated. At autopsy, the face was plethoric but there was no evidence of petechiae. The esophagus contained a large bolus of partially-masticated food and was markedly dilated, with a maximum width of 17cm, tapering to a narrowed gastroesophageal junction measuring 2cm. The stomach contained approximately 1000cc of partially digested food. There was no evidence of vomitus or food particles within the upper or lower airways. The trachea and surrounding thoracic structures were significantly compressed by the megaesophagus. White frothy foam was found within the trachea and bronchi, and the lungs were markedly congested and edematous. Microscopic examination revealed chronic inflammation and muscular hypertrophy of the esophagus. Cause of death was determined to be complications of achalasia. Manner of death was natural.

Achalasia occurs in <10 per 100,000 individuals in the United States, has an unknown etiology and appears to result from denervation of smooth muscle with degeneration of the vagus nerve and ganglion cells. Achalasia can have an indolent asymptomatic course, but most often presents with symptoms of dysphagia, dyspepsia, regurgitation and weight loss. Respiratory compromise is a rarely reported complication. Literature review reveals five reported cases of fatal outcomes attributed to achalasia, and only two reported cases with no significant contributing factors such as aspiration or ischemic heart disease. Excluding aspiration and ulceration/perforation, possible mechanisms of death with megaesophagus include: arrhythmias secondary to valsava maneuver; compression of the trachea, cardiovascular structures or vagal nerve; or a combination of these factors.

P17 Opioid Associated Deaths in South Carolina: A Retrospective Review

D.C. Butler, N.I. Batalis

Medical University of South Carolina, Charleston, South Carolina, USA

Objective: Rising rates of opioid abuse in the United States have generated an overdose epidemic. Particularly in the last few years, many offices across the country have seen a shift from prescription opioid overdoses to heroin, illicitly produced fentanyl, and now various fentanyl analog related deaths. Given this national trend, a retrospective review was performed to better characterize the incidence of heroin, fentanyl, and fentanyl analog associated deaths in South Carolina.

Methods: Autopsy records from the Medical University of South Carolina's forensic pathology practice, which serves roughly a third of the state, were reviewed from 2013-2016 to identify cases in which heroin, fentanyl, and/or fentanyl analogs were detected. These cases were then queried to determine the following: drug concentration; presence of any other drugs; whether natural disease was considered as a contributing factor; the manner of death; and if heroin, fentanyl, and/or fentanyl analogs were determined to be the cause of death.

Results: A total of 3,350 autopsy reports were reviewed. In 2013, the incidence of both heroin and fentanyl was relatively rare (2.2% and 1.5%, respectively), but increased somewhat steadily throughout the ensuing years. Between 2013 and 2016, the incidence of fentanyl climbed from 1.5% to 5.1% and appears to be rising, while heroin rose from 2.2% to 4.5% and appears to have leveled off. Combined, heroin and fentanyl accounted for 2.6% of total deaths in 2013 but increased to 7.6% in 2016, with more substantial increases in 2014 and 2015. With rare exception, when heroin was detected it was attributed as the cause of death or as a contributory cause of death. The same was not true for fentanyl, particularly in 2013. However, the concurrent presence of fentanyl and fentanyl being attributed as a cause of death rose from 30% in 2013 to 48-75% between 2014 and 2016. Indications of therapeutic fentanyl use have also steadily decreased from 90% in 2013 to 37% in 2016. Fentanyl

analogues were rarely encountered, although a dramatic increase of 11 cases was seen in 2016, including two cases of the novel analogue acrylfentanyl.

Conclusion: Between 2013 and 2016, opioid related deaths have steadily increased in South Carolina, including a major rise in fentanyl associated death, though this increase in incidence seems to lag behind larger jurisdictions such as those found in the Midwest and Northeast.

P18 Migraine, Methamphetamine and Myocardial Infarction Highlight Potential Bias in a Case of Thrombotic Microangiopathy

M.R. Lawless¹, E. Linde²

¹University of Nebraska Medical Center, Omaha, Nebraska, USA;

²Physicians Laboratory, Omaha, Nebraska, USA

Thrombotic microangiopathy (TMA) is a pathologic finding seen in several hereditary and acquired conditions, including thrombotic thrombocytopenic purpura (TTP) and hemolytic uremic syndrome, which result in microangiopathic hemolytic anemia and thrombocytopenia. The clinical presentation of TMA can range from nonspecific fatigue and headache, to fever, renal failure, stroke and purpura.

We report a fatal case of a TMA in a 31-year-old woman with a history of hypertension, which was presented to the Coroner's service as a possible methamphetamine overdose. Initially, she presented to a local hospital with headache, fatigue, and weakness. She was managed conservatively for a migraine headache and released upon symptom resolution. Three days later, she was found unresponsive at her residence by her boyfriend and was transported to a local hospital. No pill bottles or illicit substances were found near her. Naloxone administration failed to improve her symptoms. Physical examination revealed agonal breathing and punctate ecchymosis of the left upper extremity. Admission labs demonstrated an elevated creatinine, troponin, and markedly elevated CHF peptide, as well as mildly prolonged prothrombin time and partial thromboplastin time. Further workup was precluded when her pulse was lost during chest x-ray. Resuscitation efforts were unsuccessful. A complete blood count was not performed at either admission.

At autopsy, a large transmural myocardial infarction (MI) involving the posterior left ventricle was grossly identified despite widely patent coronary arteries. Microscopic examination identified additional multifocal areas of infarction without a specific distribution that were hours to weeks old. Numerous occlusive thrombi were seen within the cardiac microvasculature. Histologic features of TMA in the background of acute kidney injury were also seen within the section of the kidney. Postmortem toxicology was non-contributory. While TTP is suspected, a definitive etiology of her TMA cannot be established due to a lack of clinical history and confirmatory testing.

This case highlights an uncommon presentation (MI) of an uncommon disease (TMA). Moreover, this case demonstrates that medical and social histories may inappropriately bias practitioners and forensic pathologists in their decision making and death investigation. In this regard, non-specific findings did not prompt additional laboratory investigation, and an MI without coronary disease with a history of possible methamphetamine use suggested a drug-related death. Overall, this case reminds professionals to remain vigilant in both clinical assessment and death investigation.

P19 Case Report: Postmortem Hypopyon associated with Neisseria meningitidis Meningitis

W.A. Ennis, T. Luckasevic, K. Williams

Allegheny County Medical Examiner's Office, Pittsburgh, Pennsylvania, USA

A hypopyon is an accumulation of leukocytic exudate in the anterior chamber of the eye. It may be visualized without the aid of an ophthalmoscope as a white, dependent fluid collection anterior to the iris. Rarely, hypopyon has been found to be associated with Meningococcal Meningitis in the living. We describe a case in which bilateral hypopyon is

observed in a decedent with purulent meningitis, pericardial effusion, and lobar pneumonia. The decedent was found with early decomposition changes in a left lateral position. The left lateral aspects of the irides were partially obscured by pus. Leptomeningeal and lung cultures, but not pericardial fluid, were positive for *Neisseria meningitidis* group B. Recognizing hypopyon as potentially associated with *Neisseria meningitidis* infection may prevent exposure to autopsy staff.

P20 Homicide Due to Positional Asphyxia

C. Dominguez¹, A. Perkins¹, A. Duque², V. Bravo²

¹University of South Florida, Tampa, Florida, USA; ²National Institute of Legal Medicine and Forensic Science, Medellin, Colombia

Homicide via positional asphyxia is rarely described in the forensic literature. The mechanism of death by positional asphyxia is due to the restriction of the individual's normal respiratory movements. This causes a reduction in tissue oxygenation of the internal organs, most importantly of the heart and brain. While negative findings are common in other types of asphyxia, gross evidence is frequently noted in victims of these homicides.

We present a case of a 27-year-old male found folded and bound in a suitcase in Medellin, Colombia, after being reported missing for two days. Transparent tape was used to cover the decedent's face and to bind his hands and feet. On external examination, the decedent had congested facies, multiple petechiae, conjunctival hemorrhages, a hematoma within the right periorbital region, and ecchymoses on the wrists and legs. The internal examination revealed cerebral congestion along with pressure striae. Histological findings included pulmonary edema, marked vascular ectasia, and focal hemorrhages in the gastric mucosa and submucosa without inflammatory infiltrates or necrosis. The blood alcohol level and toxicology screen of the urine for narcotic drugs and depressants of the central nervous system were both negative.

Although not exclusive to positional asphyxia, these autopsy findings may represent distinctive patterns characteristic of this unique and uncommon type of death.

P21 Abduction, Interrogation, and Violence: A Series of Torture Cases from Medellin, Colombia

C. Dominguez¹, E. Baardsen¹, A. Perkins¹, M.E. Botero², E. Parrado², V. Bravo²

¹University of South Florida, Tampa, Florida, USA; ²National Institute of Legal Medicine and Forensic Science, Medellin, Colombia

Medellin, Colombia, located in the Aburrá Valley, is the second largest city in Colombia, with an estimated population of 2.44 million. It was once known as the most dangerous city in the world following an urban war initiated by drug cartels in the late 1980s. After the deaths of key cartel figures, crime rates, although still relatively high, gradually declined throughout the 1990s. Between 2003 and 2006, urban militias and paramilitary groups were demobilized by the Colombian government. Despite the 95% decrease in annual homicides since the late 1980s, the average homicide rate remains 2.5 times higher than the average in all other Colombian cities and 20 times that of the United States. In 2009, there was an average of nine homicides per day. Although now less commonly seen in the Medellin medical examiner's office, cases of torture continue to constitute a percentage of these homicides.

Torture is defined as the deliberate infliction of severe physical and/or psychological harm on an individual by a perpetrator who acts on behalf of a group or individual. Torture can include a variety of forms including falanga, prolonged suspension, electric shock injuries, repeated blunt force impacts, and sexual assault. Often torture is performed to obtain information, coerce a confession, force collaboration, discipline individuals, and/or to spread terror in the community. We present four cases in which the decedent died as the result of torture: a 27-year-old man found covered with blankets in a taxi with a plastic bag tied around

his head, strangled with immobilization signs of the hands and feet; a 26-year-old man found handcuffed in an apartment with chop wounds to the head, thorax and extremities; a 27-year-old man thrown from a moving vehicle with his feet bound by zip ties and head covered in plastic wrap; and a 30-year-old man found in a ditch, naked with ligatures at his neck and hands and signs of sexual assault. These cases demonstrate some of the peculiar scenes, various manners in which injuries are inflicted, and the characteristic autopsy findings commonly seen in these types of homicides. The aim of this work is to increase the forensic pathologist's understanding of the causes and mechanisms of torture deaths, highlight key components necessary to the autopsy report, and improve the medical documentation of torture.

P22 Intentional and Forced Lethal Ingestion: A Comparison of Two Acute Cyanide Poisoning Cases in Colombia

C. Dominguez¹, S. Thomas¹, S. Grewe¹, M.E. Botero², E. Parrado², V. Bravo²

¹University of South Florida, Tampa, Florida, USA; ²National Institute of Legal Medicine and Forensic Science, Medellin, Colombia

Cyanide is a lethal toxin that can rapidly cause death after an exposure. Exposure to cyanide can occur from multiple sources including cigarettes, diet, pesticides, medications such as sodium nitroprusside, and occupational exposures such as mining, rubber manufacturing, and metal working. The most common source of cyanide exposure is fires because it can be given off during combustion. This toxin can be absorbed through the skin, gastrointestinal tract, and lungs. It works by inhibiting cellular aerobic metabolism by interfering with oxidative phosphorylation causing tissue hypoxia. Cyanide poisoning is uncommon, and can be accidental or it can be intentional as a means of suicide or homicide. Autopsy findings of acute and chronic cyanide ingestion are often variable and nonspecific, highlighting the importance of an initial suspicion since routine cyanide testing is not commonly performed at autopsy. Given the rarity of this diagnosis, we present two cases from Colombia in which cyanide ingestion proved to have a fatal outcome.

In the first case a 44-year-old man, was found dead by coworkers at his office, where he reportedly was last seen crushing unknown white pills. Autopsy findings showed cherry red liver mortis, pulmonary edema, conjunctival petechiae and markedly congested, dull gastrointestinal mucosa. The gastric content consisted of black, dark fluid with a characteristic "bitter almond" odor. A rapid cyanide test was positive and additional studies were confirmatory. The manner of death was ruled a suicide.

The second case involves a 25-year-old man last seen with a woman near a lake. During the scene investigation, the man was found deceased near a bottle containing clear liquid. The autopsy revealed cherry red livor mortis, pulmonary edema and eroded, severely congested gastric mucosa. A rapid cyanide test on the stomach contents and bottle found at the scene was positive, with concordant confirmatory testing. A thorough case investigation revealed the woman forced the decedent to drink the bottled liquid. The manner of death was ruled a homicide.

Homicidal, forced ingestion of cyanide has been rarely reported, which illustrates the importance of a thorough case investigation. Deriving a manner of death may largely depend on circumstances not physically present at a death scene. In Colombia, cyanide is a major component of jewelry cleaning solutions, which are easily accessible to the public. It is important for pathologists to keep cyanide poisoning in the differential for both homicides and suicides, with an awareness of chemical products that harbor it.

P23 Vascular Projectile Embolization

J. Chao¹, J.J. Barnard², J. deJong¹, J.A. Prahlow¹

¹Western Michigan University Homer Stryker MD School of Medicine, Kalamazoo, Michigan, USA; ²University of Texas-Southwestern, Dallas, Texas, USA

Deaths related to firearms are common within the United States, with most cases having conspicuous projectile wounds found at autopsy. Individual gunshot wounds may be perforating or penetrating. In most cases with penetrating wounds, projectiles are relatively easily found via radiography and by following the pathway on internal examination. When a projectile is not detected in the expected region, intravascular embolization of the projectile should be suspected. The authors present three unusual cases of intravascular projectile embolization.

Case 1: The charred remains of a 10-year-old male were found within a burning trailer. Multiple shotgun slug fragments were identified within the child's head, confirming that the child had been killed prior to the fire. A single slug fragment was identified within the neck region on x-ray. At autopsy, this fragment was found within an intact jugular vein.

Case 2: A 16-year-old male sustained a gunshot wound of the back. He was alert and oriented, but was taken to the Emergency Department for evaluation. A chest x-ray was negative, but a bullet was identified in his lower trunk region on pelvic/abdominal x-ray. An exploratory laparotomy was undertaken, but was negative. Clinicians presumed that the bullet had remained behind the visceral organs, in the lower back/buttock region. He was discharged to home. Approximately 1-month later, he suddenly collapsed at home. Despite resuscitation attempts, he was pronounced dead. At autopsy, a massive hemothorax was found to have originated from a large subpleural, periaortic hematoma, related to a gunshot defect of the aorta. The projectile was found within the left internal iliac artery.

Case 3: The decomposing body of a 21-year-old male was found face down in water in a drainage ditch. He had sustained multiple gunshot wounds in a drug-related confrontation. At autopsy, a gunshot wound of the central chest traversed the heart before ending within the inferior vena cava. The bullet was not easily identifiable. Further examination revealed that the small-caliber bullet had embolized in a retrograde direction in to a tributary of a hepatic vein, within the liver.

Intravascular bullet/projectile embolization is well-described within the clinical and forensic literature. Embolization may be arterial or venous, as well as antegrade versus retrograde. Typically, such emboli involve small caliber bullets or shot pellets. The authors present 3 unusual cases of projectile emboli at autopsy, one involving shotgun slug fragment embolization, one where death was delayed, and one with retrograde embolization into the liver.

P24 The Autopsy: An Assessment of Utility at One Institution

C.R. Miller, R.D. Johnston, B.H. Blake, J.F. Aronson

The University of Texas Medical Branch, Galveston, Texas, USA

INTRODUCTION

We are investigating the ability of the autopsy at our institution to elucidate previously unrecognized major or minor diagnoses. Autopsy rates in hospitals have decreased from 40-60% of all hospital deaths before 1970 to 5% in the 21st century, in spite of the fact that hospital autopsies frequently reveal errors made in suspected cause of death and errors made which could have affected the patient's clinical outcome.

MATERIALS AND METHODS

At our institution, we perform approximately 300 autopsies per year. A representative sampling of 68 of these 300 cases from 2016-2017 was examined via a worksheet (adapted from Dr. Alex Williamson's version, Hofstra School of Medicine) completed by the attending physician and resident who performed each case.

RESULTS

Approximately a quarter (23.5%; n = 16) of our cases are in-hospital deaths. The remainder are categorized as Texas Department of Corrections (TDC) outside-hospital deaths, medical examiner (ME) cases, and private autopsies. Of these 68 total queried cases, 76.5% (52/68) were categorized as having the diagnosis established by autopsy (with 62.5% (10/16) in hospital cases and 80.7% (42/52) in non-hospital cases), and 83.8% (57/68) were categorized as having major clinical diagnoses

confirmed by autopsy (87.5% (14/16) in hospital cases and 82.7% (43/52) in non-hospital cases). In 26.5% (18/68) of all cases, one or more major unsuspected diagnoses were identified at autopsy (43.8% (7/16) in hospital cases and 21.1% (11/52) in non-hospital cases). In 52.9% (36/68) of all cases, autopsy established the cause of death, and in 47.1% (32/68) of cases the autopsy confirmed the clinically suspected cause of death. These categories are broken down to 62.5% (10/16) and 56.3% (9/16) in hospital cases, respectively, and 50.0 (26/52) and 44.2 (23/52) in non-hospital cases, respectively. The differences in rates of discrepant findings between in-hospital and non-hospital cases was not significant across the board.

CONCLUSION

Conclusions regarding differences between in-hospital and non-hospital deaths are limited by low sample numbers for this ongoing study. Regardless, overall percentages of cases where major diagnoses (including the cause of death) were established at autopsy were high. The autopsy is vital in identifying clinicopathologic discrepancies, and the significance of identifying these discrepancies can have far reaching effects on patient care and management. The reporting of these ante- and post-mortem diagnostic discrepancies will help our institution (and hopefully others) reduce future medical errors and improve patient safety, thus "closing the quality loop".

P25 Death Following Bilateral Spontaneous Renal Artery Dissection Associated With Fibromuscular Dysplasia: Case Report and Review of the Literature

A.L. Lukefahr, B. Parks

The University of Arizona, Tucson, Arizona, USA

Spontaneous renal artery dissection (SRAD) is a rare entity, usually occurring in men in the fourth to sixth decade of life. Conditions associated with the development of SRAD include fibromuscular dysplasia, connective tissue disorders, severe hypertension, and extreme physical exertion. Bilateral dissection is seen in 10-15% of cases of SRAD. Here we report a case of a 20-year-old man who developed bilateral renal artery dissection associated with a left kidney infarct. Past medical history was significant for premature birth (34 weeks gestation), left renal malrotation, elevated left hemidiaphragm, and stomach volvulus status-post repair. Following presentation to a local emergency department for left flank pain, he was noted to have partial occlusions of the proximal and distal left renal artery branches associated with infarcts of the left kidney. Following administration of Lovenox for presumed renal arterial thrombus, he became unresponsive and developed anemia (hemoglobin 3.3 g/dL), hypotension, and a distended abdomen. Following surgical intervention to evacuate a retroperitoneal hematoma, he developed asystole. Autopsy identified hemorrhage of an unidentified retroperitoneal vascular source. Gross examination revealed what appeared to be bilateral renal artery thromboses; however, microscopic evaluation of the vasculature revealed fibromuscular dysplasia, not further classifiable, involving both renal arteries and infrarenal aorta, with medial dissection and pseudo-aneurysm formation involving both renal arteries. Cause of death was attributed to hemorrhage, likely secondary to clinical anticoagulation. In addition, a literature search was performed on the Medline-PubMed and Web of Science databases using the keywords bilateral, renal, artery, and dissection. An overview of the results is discussed, with an emphasis on the demographics and suspected etiologies of reported cases. This case highlights the importance of careful microscopic analysis of renal arteries at autopsy in the case of suspected renal artery thrombus or dissection. Failure of the forensic pathologist to recognize the presence of fibromuscular dysplasia may have significant implications for determining cause and manner of death (given that blunt abdominal trauma is also a cause for renal artery dissection) and for surviving family members, who may have also inherited a condition which carries a high risk for arterial dissections.

P26 Correlation or Causation? The Role of Benzodiazepines in Combined Drug Deaths with Opioids

B.C. Hoelscher, C.C. Stacy, D.J. Duff

University of Missouri School of Medicine, Columbia, Missouri, USA

This study reviews the literature to examine the evidence for a causative role of benzodiazepines in combined drug deaths with opioids. Despite an increase in the number of deaths in which opioids and benzodiazepines are both detected by postmortem toxicology, questions still remain regarding this combination and whether benzodiazepines actually contribute to death in many of these cases. In multiple drug overdoses involving opioids and benzodiazepines, it may be difficult to determine if death is caused by the opioid(s), the benzodiazepine(s), or a combination. Opioids are strong respiratory depressants, whereas benzodiazepines are weaker respiratory depressants. Deaths caused solely by benzodiazepines are rare. It is said that the two drug classes have a synergistic respiratory depressant effect, but the exact mechanism has not been determined. In 2016, the FDA began requiring boxed warning labels on opioids and benzodiazepines indicating serious risks from combined use based on a review of data showing increased emergency department visits as well as overdose deaths in which both classes of drugs are detected. There is abundant literature describing an increase in the number of deaths in which opioids and benzodiazepines are involved. But has the causative role of benzodiazepines been proven, or could this just be a correlation because opioid users also tend to use benzodiazepines? It is recommended to list the generic name of each drug thought to be a causative factor in the death on the death certificate, but the criteria for making this determination are not clear. In certifying drug deaths in these types of cases, some pathologists list every respiratory depressant drug detected, whereas others consider the blood levels of individual drugs, sometimes excluding benzodiazepines found at therapeutic levels. The available literature regarding specific lethal concentrations in these combined intoxications is scarce. One might expect for opioid concentrations to be lower in combined intoxication deaths also involving benzodiazepines compared to opioids alone, but this is not consistently demonstrated in the literature.

P27 A New Speedball: Methamphetamine and Tapentadol

C.R. Cunningham, C.C. Stacy, D.J. Duff

University of Missouri School of Medicine, Columbia, Missouri, USA

Tapentadol is a centrally acting μ -opioid receptor agonist and norepinephrine reuptake inhibitor that is used for moderate to severe pain. In the literature, there are few reports of fatal intoxications involving tapentadol. We report a case of a fatality due to the combined toxicity of methamphetamine and tapentadol. The patient was a 51 year old female with a medical history of hypertension, diabetes mellitus, and coronary artery disease. An autopsy revealed pulmonary congestion (combined lung weight 980 g), chronic hepatitis with bridging fibrosis, a 4.6 cm adrenal cortical adenoma, left ventricular hypertrophy with a heart weight of 390 g, and severe coronary artery atherosclerosis with up to 80% stenosis of the right coronary artery. Postmortem blood was positive for methamphetamine (2.2 mg/L), tapentadol (1.1 mg/L), diazepam (0.057 mg/L) and nordiazepam (0.025 mg/L). The cause of death was determined to be methamphetamine and tapentadol intoxication with arteriosclerotic and hypertensive heart disease and diabetes mellitus as contributing factors.

P28 Homicides Disguised as Staged Suicides

S.P. Prahlow¹, S.D. Cohle², J.A. Prahlow³

¹Florida State University, Tallahassee, Florida, USA; ²Kent County Medical Examiners Office, Grand Rapids, Michigan, USA; ³Western Michigan University Homer Stryker MD School of Medicine, Kalamazoo, Michigan, USA

Deaths related to homicidal and suicidal gunshot wounds are common in the United States. In most instances, investigation allows for relatively

easy differentiation between homicides and suicides. Occasionally, however, such differentiation proves to be difficult, with the manner of death (MOD) in some cases ultimately being certified as "undetermined." A number of investigative and autopsy findings help to differentiate a suicidal gunshot wound case from a homicidal case. This report describes multiple deaths related to contact gunshot wounds of the head where initial investigation suggested that the deaths represented suicides; however, based on scene and autopsy findings, along with subsequent investigative information, each case was appropriately ruled as a homicide.

Case 1: An 18-year-old male was found dead on the floor of his secured apartment, with a small-caliber, semi-automatic handgun near his body, and a blanket partially covering his hands and face. His sister had come to check on him after hearing rumors that he was dead. A letter written to his girlfriend was found elsewhere in the apartment. In it, the decedent asked her for forgiveness. Subsequent body examination revealed that the decedent's hands were clasped together, in a "folded hands" position. There was a penetrating contact gunshot wound of the right temple, with the bullet path traversing the right temporoparietal and left temporal cerebrum. Subsequent police investigation revealed that the decedent had been involved with dealing drugs, and another dealer shot him in the head while he was resting on the floor.

Case 2: A 40-year-old woman was found dead in bed by her husband after he heard a gunshot. Initial investigation suggested that the case represented a suicide. The woman had suffered from depression since being kicked in the head by a horse approximately 14 months previously. Autopsy revealed two contact perforating gunshot wounds of the head. Blood spatter evidence on the husband's clothing suggested that the husband was in the vicinity of his wife at the time of gunfire. In addition, a letter written by the woman was discovered which contradicted the horse kick claim, accusing the husband of having assaulted her. The husband was subsequently charged and convicted of murder.

The cases are presented, along with a discussion regarding important aspects of the investigation and autopsy which led to the proper MOD certification of each death.

P29 Opiates and the Possible Link to Suicide

A.L. Lytle

Plymouth State University Office of Chief Medical Examiner, Concord NH, Plymouth, New Hampshire, USA

Purpose: This research examines toxicology findings for opiates/opioids in individuals with the manner of death ruled as suicide in New Hampshire to test the hypothesis that a significant number of these individuals were opiate/opioid dependent.

Methods: Toxicology reports on all suicide deaths were examined for opiates/opioids from January 1, 2014 through December 31, 2016. Each case report for individuals positive for opiates/opioids was examined for evidence of abuse and dependence. The criteria for dependence was determined by reporting family member or physician.

Results: There were 711 suicides in New Hampshire from January 1, 2014 through December 31, 2016. Of these, 176 (25%) had opiates/opioids present in their toxicology. Of these, 127 (72 %) had historical evidence of opiate/opioid dependence reported. These findings prove to be statistically significant when a standard t-test was performed ($p < 0.05$).

Conclusion: Few studies have attempted to determine a relationship between suicide and opiate/opioid abuse and dependence. The results of this research validate a need for more studies in order to correlate a possible link between the effects of opiate/opioid abuse and suicide.

P30 A Dry heat? ... It's OK We Have Shower to Shower® Bath Powder to Conceal the Decomposition Odors and Expedite the Mummification Process

H.L. Reinhard, A.S. Spencer, W.K. Ross

Penn State Milton S. Hershey Medical Center, Hershey, Pennsylvania, USA

Mummification is the result of extreme postmortem desiccation. Dehydration of the body tissues inhibits bacterial decay and prevents putrefaction of the skin and internal organs. Mummification is most commonly seen in warm, arid, and windy conditions. Throughout the centuries, numerous chemicals and other factors such as lime, lye, salt, heavy metals and bat guano have been shown to contribute to the mummification process and long-term preservation. To date, mummification via the components found in bath powder such as cornstarch, talc, and sodium bicarbonate has not been well described in the literature.

We report the case of a mummified 51-year-old female who died of acute promethazine toxicity and remained in an inhabited apartment for approximately one month post mortem. The decedent was found lying in bed covered with a blanket in a stage of mummification. Shower to Shower® bath powder was used by her roommate to conceal the decomposition odors and fluids and assist the mummification process. The bath powder used was composed of Zea Mays cornstarch, talc, sodium bicarbonate, tricalcium phosphate, fragrance, and maltodextrin. Postmortem examination revealed generalized marbling and extensive drying throughout the entire body particularly of the hands and the feet with contraction of the nose and lips. No offensive odor was appreciated. White powder was identified around the nose, ears, in and around the oral cavity, and within the trachea. Decomposition within the body cavity was present but limited, given the one month postmortem interval.

This case demonstrates the pathological and compositional changes found following mummification with cornstarch, talc, and sodium bicarbonate after one month postmortem. It is hypothesized that the corn starch binds the glycerol associated with adipocere formation and ultimately results in desiccation of the tissues. Documentation of these changes will allow for future recognition of the specific mummification process and better estimation of the postmortem interval.

P31 Fatality While Bear Hunting: A Homicide or an Accident?

A. Spagnolia, W.L. Kemp, M. Sens

University of North Dakota School of Medicine and Health Sciences, Grand Forks, North Dakota, USA

Introduction: when a hunter intentionally fires a weapon and the projectile strikes another human, the manner of death is often certified as homicide, as the intent of the individual firing the weapon is often unknown and the possibility of a hunting "accident" actually representing a concealed intentional homicide must always be considered. However, in some circumstances, such as a documented ricochet, the manner of death may be certified as accident. Other circumstances may also merit an accidental manner of death.

Materials and methods: the decedent was a 39-year-old male who was hunting with a friend when one of the two men shot a bear, which subsequently entered a brushy area. The two men waited, assuming to allow the wounded animal to die, and then entered the brush after it. The bear was only wounded and proceeded to attack the two men. While the decedent was being mauled, his partner shot and killed the bear. The decedent was brought in for autopsy to determine his cause of death. In the left thigh were numerous puncture wounds, consistent with the bear's teeth, none having injured a major artery; however, on the lateral surface of the left arm was an entrance-type gunshot wound with an irregular, up to 4.0 cm wide, marginal abrasion. The projectile had perforated both pleural cavities and was recovered near the right humeral head. Perforation of the pulmonary artery, the aorta, and other

vasculature led to a measured total blood loss of 3300 mL. An autopsy of the bear by a veterinarian revealed a perforating gunshot wound. In addition, on the projectile recovered from the decedent, both human and bear blood was identified.

Discussion: according to the National Association of Medical Examiner's Guide for Manner of Death Classification, if a hunter intentionally fires a weapon and kills a human, the manner of death may be classified as homicide; however, if a weapon is discharged, and the projectile strikes an object, ricochets and kills a human, the manner of death may be classified as accident. In the death reported, the scenario does not fit either of the above situations; however, given that 1) the decedent's friend fired a projectile with an intent to hit the bear that was mauling his partner and 2) that the projectile perforating the bear and entering his partner was unintended, the manner of death was certified as accident.

P32 Islet Cell Hyperplasia: A Potential Marker for Androgenic Steroid Use in Bodybuilders

*J. Weinand, W.L. Kemp, M. Sens
University of North Dakota School of Medicine and Health Sciences,
Grand Forks, North Dakota, USA*

Introduction: the use of androgenic steroids has been associated with certain pathologic changes, most commonly hypertrophy and fibrosis of the heart. Although islet cell hyperplasia of the pancreas has not apparently been well-described in bodybuilders using androgenic steroids, it has been described in a group of patients who were prescribed androgenic steroids for the treatment of aplastic anemia occurring in association with Fanconi's anemia.

Methods and Results: a 39-year-old male stepped in front of a train and sustained multiple blunt force injuries. At autopsy, he was noted to be very muscular and was found to be a professional bodybuilder at a local gym. As per office protocol, histologic examination of the organs was performed and the section of pancreas revealed marked islet cell hyperplasia. Using ImageJ, the area of the islets in photomicrographs of the decedent and seven control specimens from other autopsies was determined. The area of 16 islets sampled from the decedent ranged from 8302 μm^2 to 668,594 μm^2 , with a mean of 175,591 μm^2 . In the seven control cases from 3-10 islets were photographically sampled per decedent, with a range of area from 3885 μm^2 to 296,044 μm^2 , and a mean of 33,532 μm^2 (comment: one individual had two islets of >200,000 μm^2 in area).

Discussion: while the effects of androgenic steroids on the body are described in the literature, its effects on the heart are most often the focus. A PubMed search using the terms, "bodybuilder" and "islet cell hyperplasia" revealed no apparent articles addressing this histologic finding in association with illicit use of androgens. However, hypertrophy and hyperplasia of the pancreatic islets has been described in patients with aplastic anemia treated with androgenic steroids. Islet cell hyperplasia has also been described in patients with insulinomas, gastrinomas, high circulating levels of gastrin, and chronic pancreatitis. Nesidioblastosis, a cause of diffuse islet cell hyperplasia in children, is very rare in adults. An islet size of greater than 250 μm in diameter (approximately 49,000 μm^2 in area) is considered hyperplastic, and if carefully screened for, reportedly up to 10% of adults can have islet cell hyperplasia. Based upon the report of islet cell hyperplasia associated with androgenic steroid therapy in patients with aplastic anemia, this case report, illustrating islet cell hyperplasia in a bodybuilder, suggests that islet cell hyperplasia may be a marker indicating the use of androgenic steroids.

P33 Acute Subdural Hemorrhage Associated with Both Metastatic Adenocarcinoma of the Dura and Minor Head Trauma: A Case Report and Review of the Literature

*J. Julson, W.L. Kemp, M. Sens
University of North Dakota School of Medicine and Health Sciences,
Grand Forks, North Dakota, USA*

Introduction: reportedly, 8-9% of individuals with metastatic neoplasms will have dural metastases identified at autopsy; however, between 1904-2003, only 198 cases of dural metastases were reported in the literature. The mechanism for the metastases may be 1) hematogenous spread, 2) direct invasion from metastases in the cranium, or 3) rarely, through direct extension from a cerebral metastasis. Tumors of the prostate, breast or lung often extend into the dura directly from bony metastases. Occasionally, dural metastases are associated with a subdural hemorrhage, with only about 55 cases reported in the literature. Head trauma also causes subdural hemorrhages. This case report describes an acute subdural hemorrhage occurring in association with both recent minor head trauma and dural metastatic adenocarcinoma.

Materials and methods: while incarcerated, a 44-year-old male with a history of diabetes mellitus and hepatitis C was witnessed to strike his head hard against the floor. Although he was active in the interim, three days later he was found unresponsive in his cell and transported to the hospital where a CT scan revealed a surgically un-manageable acute subdural hemorrhage. He subsequently died and an autopsy was performed. The bridge of his nose had a 2.0 cm crusted abrasion and scene investigation revealed scattered smears of blood and blood soaked towels, with medical personnel estimating a blood loss of 500 mL. Autopsy revealed an acute subdural hemorrhage grossly and metastatic adenocarcinoma in the dura mater, pituitary gland, lungs and lymph nodes microscopically. No primary source for the neoplasm was identified.

Discussion: the mechanisms proposed for the development of a subdural hemorrhage in the background of dural metastases are rupture of blood vessels that were formed by neo-vascularization of the hemorrhage, obstruction of dural venous vessels leading to dilation and rupture, or, a pre-existing subdural hemorrhage may serve as a medium for the deposition of blood-borne metastases. In addition to 1) the presentation of a condition rarely reported in the medical literature (i.e., dural metastases associated with a subdural hemorrhage) and 2) the first apparent report of a subdural hemorrhage in an individual with both dural metastases and well-documented recent minor head trauma, this report illustrates that histologic examination of the dura mater and a subdural hemorrhage can, in addition to help determine the age of the subdural hemorrhage, also potentially help identify an underlying causative or contributory etiology for the subdural hemorrhage.

P34 An Unusual Case of Sudden Death Due To Subarachnoid Hemorrhage

*S.M. Maines, S. Crook, K. Shah
University of Kentucky, Lexington, Kentucky, USA*

The concept of "cognitive bias" has become a hot topic in the forensic science community in recent years. What some call bias, pathologists consider an essential part of the job. Forensic pathologists are physicians who must correlate anatomic findings with clinical history and scene investigation to arrive at a complete and accurate cause and manner of death. We present a case that highlights the intersection of art and science that defines the field of forensic pathology and necessitates its practice by a physician.

A previously healthy 56 year old Asian male who presented to the hospital with easy bruising, mucosal bleeding, and melena was found to be severely pancytopenic with bone marrow findings consistent with aplastic

anemia. Parvovirus PCR was positive; other causes were ruled out. The patient completed two doses of a 5-day IVIG treatment plan before being found on the floor near his hospital bed. A head CT showed subarachnoid hemorrhage, cerebral edema, and transtentorial cerebellar tonsillar herniation. At autopsy, there was no evidence of injury to the scalp or calvarium. Intracranial findings were consistent with CT results.

Parvovirus B19 is a common infectious disease that is known to induce aplastic crisis in patients with hemolytic anemia. In healthy subjects, the virus typically causes the symptoms described of Fifth's disease and occasionally a mild, transient pancytopenia. Only rare case reports have described severe aplastic anemia in otherwise healthy individuals. While most subarachnoid hemorrhages are a result of a ruptured berry aneurysm or trauma, this unusual case highlights the importance for medical examiners to maintain a broad differential diagnosis and obtain thorough clinical and social history. Without these considerations, the more rare underlying causes may be missed, affecting families, epidemiologic statistics, and potentially legal proceedings. What qualifies forensic pathologists as physicians is their ability to integrate both physical findings and pertinent clinical and social history. In this case, we identify a clear example of the importance of that integration and its necessity for excellent job performance.

P35 Get Rich or Die Trying: A Case of Traumatic (Compression) Asphyxia

C.T. Allard, S.L. Stauffer

University of Iowa Hospitals and Clinics, Iowa City, Iowa, USA

With the creation of the Mining Safety and Health Administration (MSHA), mining related fatalities have fallen to record lows with only 26 total deaths reported in 2015. Of these very rare deaths, approximately 31% were in the stone, sand, and gravel mine sector with asphyxia, strangulation, and drowning accounting for the majority of deaths.

We present a case of a 52-year-old man found deceased at a limestone mine where he was employed. Per investigative reports, while at work the decedent ventured into a closed and unstable area of the mine searching for crystals (that he likely intended to sell) when a rockfall occurred and trapped him under approximately 500 tons of dirt and stone material. Several hours passed before his body was recovered via the use of a backhoe. Time of death was pronounced at 0330 the following morning. Autopsy examination revealed florid, confluent petechiae of the head (including the conjunctivae and oral mucosa), neck, upper chest, and axillae. There was also prominent congestion of the sclerae. Minor cutaneous blunt force injuries were present on the torso and extremities, and there were multiple right-sided rib fractures. There were no other significant internal injuries of the head, neck, or torso, and no earthen material was present in the airways.

Other injuries found at autopsy were an open fracture of the right tibia and fibula, palpable fractures of the right knee, dislocation of the left knee, palpable instability of the left ankle, and dry abrasions and gaping, open, non-hemorrhagic lacerations of the lower extremities. The appearance and locations of these extremity injuries suggested that they were produced postmortem during the recovery efforts, and were likely made by the backhoe.

In addition, several large clear crystals were found within the body bag and in the decedent's clothing pockets, along with a business card for a crystal selling establishment.

This constellation of findings is compatible with death due to traumatic (compression) asphyxia, with overlying postmortem injuries. This case not only highlights a rare circumstance of death that a forensic pathologist may encounter, but it also demonstrates the contrast between antemortem and postmortem injuries in an individual for which heavy machinery is used for body recovery.

P36 Large-Scale Computed Tomography Database with Associated Lifestyle and Health Data

S. Daneshvari Berry¹, H.J. Edgar²

¹University of Mississippi Medical Center, Madison, Mississippi, USA;

²University of New Mexico, Albuquerque, New Mexico, USA

Research is often constrained by a lack of appropriate data for hypothesis testing. For example, various gas collections can be present in a decedent, many of which could have profound forensic implications. How frequently gas embolism plays a role in the pathophysiology of death is not clearly understood. Additionally, gas collections are important indicators of decomposition, which can be modified by or partially obscure pre-existing injury or infection. How frequent are traumatic pneumothoraces and tension physiology in cases of multiple blunt force traumas? This and many other research questions require a large, diverse full-body Computed Tomography (CT) data set that currently does not exist.

The Office of the Medical Investigator (OMI) is a centralized medical examiner office for the state of New Mexico. Any individual who dies of unknown or suspicious causes is routed to the OMI. This includes not only deaths from homicide and suicide, but a large proportion of natural and accidental deaths as well. In 2010 35% of deaths in New Mexico were autopsied. The racial and ethnic diversity of the state is reflected in the OMI sample.

In 2010, the Center for Forensic Imaging at the OMI received a large National Institute of Justice grant to determine if the traditional autopsy could be supplemented or supplanted by CT. As a result, every decedent that underwent an autopsy also received a full-body, high resolution CT scan. After the grant ended, the OMI continued to scan every decedent. This has resulted in 11,000 scans with little associated data.

In order to make these CT images retrievable to researchers as well as to answer research questions, a Delphi method survey was conducted. This resulted in 59 metadata variables to associate with the images making them useful in forensics, anthropology, medicine, and dentistry. In 2016 the National Institute of Justice awarded a grant to construct a free access Decedent Database available to *bona fide* researchers. Lifestyle and health metadata will be collected from both the medical examiner's database as well as interviews with the next of kin. The metadata on all 11,000 decedents will be available online, and images will be sent on portable drives via postal mail. The database will have the potential to answer many currently unanswerable questions.

The database is currently under development and will be available to researchers by the end of 2018.

P37 Severe Lung Injury Associated with A/H1N1pdm09 Infection in the Post-pandemic Season

K. Hayashi¹, N. Nakajima², S. Iwatate³, K. Asakura¹, A. Hamamatsu¹

¹Tokyo Medical Examiner's Office, Tokyo, Japan; ²Department of Pathology, National Institute of Infectious Diseases, Tokyo, Japan;

³School of Health Science, Kyorin University, Tokyo, Japan

Background: The A/H1N1pdm09 virus (A/H1N1pdm09) was first reported as a novel influenza virus in Mexico in March 2009, and it rapidly spread worldwide from human to human. In the pandemic season (from June 2009 to August 2010), several fatal cases were complicated with viral pneumonia, which subsequently developed into acute respiratory distress syndrome (ARDS), leading to patient death due to respiratory failure. A/H1N1pdm09 continues to circulate as a seasonal influenza virus in the post-pandemic period. Seasonal influenza-associated pneumonia is generally secondary bacterial pneumonia, and pathologically, it rarely develops into primary viral pneumonia. The number of the cases has decreased in the post-pandemic season. However, between the winter of 2015 and the spring of 2016, 14 cases were positive for A/H1N1pdm09 virus and more than half of the cases in Tokyo Medical Examiner's Office had ARDS. We would like to know if the cause of ARDS was linked to the

host or the virus. For example, does A/H1N1pdm09 have high alveolar epithelial infectivity?

Methods: To elucidate the pathogenic mechanism of A/H1N1pdm09 infection-associated lung injury and ARDS in the post-pandemic season, we examined 34 A/H1N1pdm09 positive autopsy cases from 2009 to 2016 and examined lung tissues using molecular, biological, and pathological methods.

Results: Among 34 cases (23 males and 11 females, mean age 46 years), nearly 41% were psychiatric patients and 38% were obese individuals (BMI > 30). Thirteen cases (38%) demonstrated diffuse alveolar damage. Only a few A/H1N1pdm09 antigen-positive cells were detected in lung sections, some of which were alveolar epithelial cells, and the copy number of A/H1N1pdm09 RNA was low. In all cases, the receptor binding site sequence of hemagglutinin in A/H1N1pdm09 had a preference for alpha-2,6 linked sialic acids, suggesting low infectivity in alveolar epithelial cells.

Discussion/Conclusions: Even in post-pandemic seasons, the A/H1N1pdm09 virus has more potential to induce severe lung injury than other influenza viruses. Furthermore, an overactive immune response is likely in psychiatric or obese host.

P38 LifeLink of Georgia's ® Coroner Referral Program

C.M. Gammill, C. Borderieux

LifeLink of Georgia, Norcross, Georgia, USA

In 154 of 159 counties in Georgia, the responsibility for death investigations falls under the jurisdiction of the elected Coroner. In most of those counties, the Georgia Bureau of Investigation Medical Examiner provides autopsy and other forensic services to aid in their investigation. There are approximately 400 Coroner or Deputy Coroners in Georgia. There is no requirement that Coroners have any medical or death investigation training prior to being elected as Coroner. Georgia law requires hospitals to have agreements with an Organ Procurement Organization (OPO), a tissue bank, and an eye bank, requiring cooperation between those groups. However, participation of Coroners is not mandated. The law does state that a medical examiner and procurement organization shall cooperate to maximize the opportunity to recover anatomical gifts.

In 2012, the Coroner and Medical Examiner Liaisons at LifeLink of Georgia® began to look for ways to increase opportunities for tissue recoveries. Having relationships with medical examiners, which included direct referrals, we found many potential donors were ruled ineligible due to lack of timely notifications, and decedents were often not seen by a medical examiner or hospital, but had direct funeral home disposition after Coroner involvement. Based on this information, the Coroner Referral Program began in 2013.

Implementation of the Program began with training for LifeLink of Georgia® staff who may have contact with coroners, to include communications personnel, Family Care Coordinators, Medical Screeners, Recovery Technicians, and Quality Review Coordinators. The training included discussions of the Coroners authority and responsibilities, and how we could assist them during their death investigation.

Training for the Coroners regarding the Coroner Referral Program was centered on providing information regarding the benefits of organ and tissue donation to the families of organ and tissue donors, and benefits of organ and tissue donation to the broader community. We included donor families discussing their experiences and how donating helped them through their grieving process. LifeLink of Georgia® has produced videos of Coroners who lost family members who were waiting on lifesaving organs, and Coroners and donor families who were involved in making

referrals. We also provided training about referral processes, including information collection, timeliness, and the referral call.

After the first year of training in 2013, Coroners had made 71 referrals. In 2014, referrals increased to 203, 2015 saw 322 referrals, and in 2016, 255 referrals came from Coroners. Coroners from 69 counties have made referrals.

P39 Dehiscence and Exsanguination of a Healing Surgical Chest Incision Mimicking Traumatic Injury in a Non-Decomposed Person

J. McLemore¹, S. Sweede²

¹Wake Forest School of Medicine, Winston Salem, North Carolina, USA;

²Buncombe County, Asheville, North Carolina, USA

A man in his 6th decade with numerous co-morbidities including substance/alcohol abuse, diabetes, and generalized atherosclerosis, was found in his secured residence, prone on his bed. The mattress had been soaked through with his blood. Initial inspection of his body by the county medical examiner revealed an open defect on the midline of his upper chest, worrisome for a firearm or sharp force injury. Further visualization of the wound was suboptimal because of the decedent's chest hair and blood. The medical examiner was reluctant to clean or shave around the defect for fear of contaminating potential evidence in a homicide. No firearms were found in the apartment, and no knives were near the body. The decedent's medical history was significant for coronary artery by-pass graft surgery and mitral valve replacement three months prior to death. He had seen his primary care provider about 1 week prior to being found dead although no mention of the condition of his surgical site was found in the medical records. Because initial examination of the body at the scene was concerning for a possible homicide, an autopsy was conducted. After shaving and cleaning of the chest at autopsy, findings revealed a 3/4 inch round defect, at the superior edge of a poorly healing surgical incision. Reflecting the tissue of the chest revealed a sternum that had been pulling apart with adjacent small soft tissue abscesses, loose sutures and disrupted sternotomy wires. The pericardial sac was fibrotic but intact; no major vessels were disrupted. The source of the bleeding was not definitively found; however, the left internal mammary artery (IMA) graft, which had been documented in the surgical records as being grafted to the left anterior descending coronary artery, was lost in the inflamed substernal soft tissue. Disruption of the IMA graft was the presumed source of the bleeding. A point-of-care urine drug screen was positive for cocaine. Inspection of his medications at his residence indicated that he had not taken his antibiotic that was prescribed after his surgery. Risk factors for postoperative dehiscence of sternotomy surgical sites include but are not limited to malnutrition, tobacco, alcohol and drug addictions. Dehiscence of surgical wounds has been known to mimic antemortem trauma in decomposed bodies; however, this same mimic in non-decomposed bodies has not been previously reported.

P40 Controversial Conclusions: Manner Of Death Determination In Fatal Train Collisions

C. Pryor¹, A.L. Falzon², C.H. Revercomb¹, K. Rogers³

¹Southern Regional Medical Examiner's Office, Woodbine, New Jersey, USA;

²State Medical Examiner, Trenton, New Jersey, USA;

³Office of the State Medical Examiner, Trenton, New Jersey, USA

In traumatic fatalities resulting from a train collision, the cause of death is often evident to the forensic pathologist, through a review of the significant injuries sustained. Determination of the manner of death, however, can prove difficult. Fatal pedestrian collisions become controversial, particularly when the strike was not witnessed and when no previous suicidal ideation or behaviors are documented. Ramifications of the manner of death ruling are far reaching, impacting criminal investigation, allocation of insurance benefits as well as the family grieving process. Behavior preceding the incident, presence of a suicide note, previous ideations/attempts, and recent stressors are all important considerations

in the pathologists' manner of death determination. Toxicology results are also important as they can be indicative of a level of incapacitation as opposed to rational intent. Available investigative data for all traumatic train related fatalities in the state of New Jersey from January 1, 2011 through December 31, 2015 were reviewed. The 142 traumatic train-related fatalities included 134 pedestrians and 8 individuals who were inside a motor vehicle that was struck by a train, including 5 drivers and 3 passengers. At least one train vs. motor vehicle incident resulted in multiple fatalities. The manners of death included suicide (n=91), accident (n=45) and undetermined (n=6). A demographic review highlighted patterns among gender, race, marital status and age. The highest incidence of fatal train interactions was in the age group of 18-29 year olds, 25% of the incidents. The decedents were majority male, with 114 fatalities, of which, 63% were ruled suicide, 32% accident, and 5% undetermined. The 28 female decedents included 68% suicides and 32% accidents. In all six cases ruled undetermined, there were no notes or reported prior indications of suicidal intent. Toxicology findings in five of the six cases indicated recent use of alcohol, non-prescribed drugs, or both. Cases where the determined manner of death was suicide were, in some cases, met with familial remonstrance. In at least one of these cases, familial opposition prompted amendment of the manner of death from suicide to accident.

P41 Drug Immunoassay Testing of Vitreous Fluid as a Surrogate for Urine Testing

L. Tomos, S. Presnell

Medical University of South Carolina, Charleston, South Carolina, USA
Standard immunoassay testing kits are fast and relatively inexpensive screens for drugs of abuse. Status DS® is a one-step assay that provides results in as little as five minutes. The manufacturer's validation testing shows a 97-99% correlation to gas chromatography-mass spectrometry (GC/MS). The test menu includes:

- Tricyclic Antidepressants (TCA)
- Opiates (OPI)
- Methadone (MTD)
- Phencyclidine (PCP)
- Amphetamine (AMP)
- Barbiturates (BAR)
- Methamphetamine (MET)
- Benzodiazepines (BZO)
- Marijuana (THC)
- Cocaine (COC)

Positive results may help guide the death investigation and negative screens may allow completion of cause of death statements in cases where there is sufficient anatomical disease. However, not all decedents have urine at the time of postmortem examination. Use of vitreous fluid as a surrogate is technically limited by viscosity of the fluid and suitability as a sample.

Study:

Hyaluronidase is an enzyme that digests hyaluronic acid, decreasing vitreous viscosity. Sonication applies sound energy to agitate particles in a sample and disrupt biological material. A prospective study was designed to screen untreated, hyaluronidase treated vitreous fluid (HVF), and sonicated vitreous fluid (SVF) in autopsy cases where the cause of death was suspected to be associated with drug use. To qualify for the study, urine and vitreous fluid had to be available for collection. The results were then compared to the blood and urine drug concentrations analyzed at reference laboratories.

Results:

The following drugs were detected in urine at the time of autopsy: OPI, AMP, MET, BZO, THC, COC, MTD, and TCA. Urine results correlated well with the presence of drugs in blood; false positive opiate results correlated with the presence of fentanyl or derivatives. In comparison,

OPI, MET, BZO, MTD and COC were confirmed in HVF. Untreated vitreous and HVF failed to identify THC (5 cases), AMP (3 cases), BZO (5 cases), OPI (4 cases), MET (1 case), TCA (1 case). Vitreous fluid and HVF had comparable results, although hyaluronidase treatment evidenced opiates in 3 cases, and benzodiazepines and methadone in 1 case each. Sonication had no benefit, and some positive samples turned negative after sonication.

Conclusions:

Vitreous fluid is not a good surrogate for immunoassay testing. Hyaluronidase treated vitreous fluid may provide the next best alternative fluid for testing when urine is not available. Sonication is not recommended, and is also more technically difficult.

P42 3,4-Methylenedioxyamphetamine (MDMA, Ecstasy) Intoxication in a Young Adult with Giant Coronary Aneurysms from Kawasaki Disease

R. Eigsti, F. Dennis, N. Marcus

University of Iowa Hospitals and Clinics, Iowa City, Iowa, USA

Kawasaki disease is an acute vasculitis of unknown etiology that usually occurs in children less than 5 years old. The disease commonly presents as an acute febrile syndrome with conjunctivitis, polymorphous skin rash, cervical lymphadenopathy, oral mucositis, and skin desquamation. Coronary artery aneurysms due to arteritis are the most common cardiac complication and develop within 8 to 12 days of disease onset. Aneurysms develop in 5% of treated patients and 20% of untreated patients. Over time, these aneurysms may spontaneously regress, remain the same size, expand, or rupture. Chronic aneurysms are associated with an increased risk of developing luminal thrombosis and myocardial injury. Coronary angiogram and intravascular ultrasound are used to characterize the aneurysms. Patients are often followed with serial echocardiography.

We present a case of an 18-year-old male with a past medical history of Kawasaki disease complicated by giant aneurysms of the right and left coronary arteries. Serial echocardiographic studies and treadmill EKG stress tests as recent as 1.5 years before death revealed excellent cardiac function with no evidence of dyskinesia and a normal cardiovascular response to exercise. The decedent sustained a witnessed collapse after ingesting MDMA and ethanol. He was transported to the emergency department and pronounced dead after unsuccessful resuscitative efforts.

Autopsy revealed large aneurysms of all three main epicardial coronary arteries. The maximum arterial diameter was 2.0 cm. The aneurysmal areas had extensive foci of severe stenosis by fibrocalcific plaques, with areas of pinpoint luminal narrowing. These findings were highly consistent with the history of Kawasaki disease. The heart also had left ventricular hypertrophy and mild bi-atrial and biventricular dilatation. Microscopic examination revealed variable myocyte hypertrophy ranging from mild to severe. These findings are related to the coronary artery disease. There were remote microinfarcts in the anterior and posterior left ventricle and a recent, healing microinfarct was in the posterior left ventricle.

This case illustrates the residual, lasting effects of cardiac disease due to Kawasaki disease in the setting of illicit stimulant use. MDMA is an amphetamine derivative and produces sympathetic activation. Drug induced sympathetic activation can cause cardiovascular effects including tachycardia, vasoconstriction, blood pressure alterations, dysrhythmias, and coronary artery spasm. It is likely that Kawasaki disease-related structural abnormalities of the heart yielded.

P43 Unsafe Sleep Environments: A Florida Case Series Illustrating the Dangers of Bed Sharing, Soft Bedding, and Prone Positioning

E.M. Baardsen¹, A.R. Perkins¹, S.R. Rivers², K. Devers²

¹University of South Florida-Morsani College of Medicine, Tampa, Florida, USA; ²Hillsborough County Medical Examiner's Office, Tampa, Florida, USA

Sudden unexpected infant death (SUID) is defined as the death of an infant (less than 1 year of age) that is sudden, unexpected, and without an obvious cause prior to investigation. The Centers for Disease Control and Prevention (CDC) reported that approximately 3,700 sudden unexpected infant deaths occurred in the United States in 2015. These deaths were divided into three commonly reported types: sudden infant death syndrome (SIDS), unknown cause, and accidental suffocation and strangulation in bed. Possible causes of the latter include suffocation by soft bedding, overlay by caregivers, wedging/entrapment, and strangulation. Bed sharing and overlay represent the greatest risk to infants up to four months old. Infants between four and twelve months of age are capable of rolling, putting them at increased risk of suffocation/strangulation and wedging/entrapment. It can be difficult to distinguish SIDS from suffocation/strangulation because the event is often unwitnessed and livor patterns can alter after prolonged medical attempts of resuscitation. We present a series of 18 cases from Hillsborough County, Florida, that occurred between 2014 and 2016 that demonstrate a variety of dangerous sleep environments that ultimately resulted in the sudden unexpected accidental death of children less than one year of age. These cases reflect various unsafe practices, including prone positioning, the use of soft bedding, and bed sharing. Several of the cases depict a combination of these practices. When approaching cases of sudden unexpected infant death, it is crucial to examine the scene thoroughly, consider details provided by caregiver reenactments when available, and thoroughly examine the child for characteristic signs and markings, before making the final determination that the death was the result of accidental suffocation and strangulation in bed.

P44 A Review of 5 Unusual Gunshot Wound Suicides Reflects the Importance of Proper Death Investigation in Determining Manner of Death.

J.M. Wright, M. Kessler

Office Of The Chief Medical Examiner, Commonwealth Of Virginia, Northern District, Manassas, Virginia, Usa

Our office has investigated multiple instances of suicides involving multiple gunshot wounds. We discuss five cases examined between November 2016- April 2017. All cases were initially reported as a single gunshot wound by law enforcement or a medical professional. However, in all cases autopsy findings revealed multiple gunshot wounds and it was essential to correlate findings with scene and police investigation. These cases highlight the importance of proper scene investigation performed by trained professionals in death investigation. Case one, reported by hospital staff, was a 61-year-old male with a gunshot wound to the right temple with soot and stippling and a gunshot graze wound located on the forehead with stippling. Police observed three bullet holes located to a closet door and door trim. The second case, reported by police, was a 75-year-old male found in his vehicle with a handgun. The decedent had a contact gunshot wound to the posterior head and a gunshot wound to the chin which did not injure any vital structures. The third case, reported by police, was a 66-year-old male found to have gunshot wounds to the head, upper and lower abdomen, right hand and forearm. The fourth case, reported by police, was a 78-year-old male with an extensive medical history. The decedent had a near contact gunshot wound to the upper abdomen and an intraoral gunshot wound. The last case, reported by police, was a 26-year-old male who had an intraoral gunshot wound. This case involved, two adjacent bullet holes located in the wall behind the decedent's head, two spent casings and one gunshot wound path. Two

out of the five cases involved a clinical diagnosis of depression or anxiety. One case showed recent ideations with no diagnosis of depression or anxiety however, a history of paranoia and obsessive-compulsive tendencies were appreciated. Two of the five cases left a suicide note. Toxicology was performed on three out of five cases, which resulted in one positive for Ketamine, one with negative results and one currently pending. In conclusion, correlation of scene investigation, autopsy findings, review of records and toxicology results are critical to determine proper manner of death. In addition, these cases illustrate the importance of scene investigation performed not only by law enforcement but by a properly trained death investigator and also reflect the importance of an autopsy performed by a certified forensic pathologist.

P45 Evidence at Scene Investigation in Drug-Related Deaths Varies by Neighborhood and Discovering Party.

C. Liverman¹, E. Moffatt²

¹University of California San Francisco, San Francisco, California, USA;

²Office of the Chief Medical Examiner, City and County of San Francisco, San Francisco, California, USA

Drug-related accidental deaths comprise an increasing proportion of forensic autopsy cases in many jurisdictions. In many such cases, physical findings at autopsy are minimal, and evidence from the scene investigation is critical for formulating a differential diagnosis and determining the need for toxicology studies. Few studies in the literature have examined the factors that influence the evidence found at drug overdose scenes. To approach this question, we queried the database of the City and County of San Francisco Office of the Chief Medical Examiner for all cases of drug-related accidental death during the years 2015 and 2016. A total of 322 cases were analyzed, after exclusion of cases without scene investigations (hospital deaths). For each case, investigator history was reviewed for evidence of drug use at the scene, including paraphernalia, as well as drug type and the party discovering the body. Additional data from the autopsy record were recorded, including location and final cause of death.

Overall, scene investigation revealed the presence of drugs in 48% of drug-related deaths and evidence of drug use in 72% of cases. The proportion of cases with drug evidence varied by neighborhood, with evidence present in 81% of cases in the area of greatest drug death density (San Francisco's Tenderloin district) compared to 65% of cases outside this area ($p < 0.01$, Fisher's exact test). No significant difference in presence of drugs was found between neighborhoods. When the data were analyzed according to party finding the body, drugs were present in 43% of cases discovered by family or friends of the decedent, 46% of cases found by a stranger and 80% of cases found by law enforcement/EMS. ($p = 0.07$, police v. acquaintances, Fisher's exact test). For cases outside the Tenderloin district, a similar relationship was seen, with drugs more likely to be discovered in cases found by police/EMS compared to those discovered by either acquaintances or strangers ($p < 0.02$, Fisher's exact test).

The findings show that sensitivity of scene investigation in drug-related deaths varies by neighborhood, with a greater likelihood of discovering drug evidence in neighborhoods with endemic drug use than in areas with higher socioeconomic status. Secondly, scenes in which the police or EMS are first to the scene are more likely to have drugs present, suggesting that drugs are removed from the scene by acquaintances or strangers prior to investigation in some cases, particularly in higher socioeconomic status areas.

P46 Characterization of Gabapentin-Related Deaths in West Virginia

M.A. Abate¹, G.S. Smith², Z. Dai², A.R. Mock³, J.C. Kraner³, J.A. Kaplan³, S. Falsafi⁴

¹West Virginia University School of Pharmacy, Morgantown, West Virginia, USA; ²West Virginia University, Morgantown, West Virginia, USA; ³State of West Virginia, Charleston, West Virginia, USA; ⁴Current: Tufts Health Plan, Watertown, Massachusetts, USA

Gabapentin has been identified in many West Virginia (WV) deaths, and increases in gabapentin misuse and abuse have been reported in recent literature. However relatively little information is known regarding gabapentin and its role in drug-related deaths. Our forensic drug database (FDD) was used to analyze information from all WV drug-related deaths, with complete data currently present for 2005 – 2014 and about 10 months each for 2015 and 2016. Decedent data include death certificate information, toxicology findings, medical history, and key autopsy findings. Of 7,356 total drug-related deaths, gabapentin was identified as a contributing cause in 398 cases (5.4%) (manner accidental in 89.5%). However, 46.0% (183) of all gabapentin deaths occurred during 2015-16, which represents 12.8% of all drug deaths during this period (N=1428). Significant differences between gabapentin (G) and non-gabapentin-related (NG) deaths include: 1) slightly older mean G age (45 G vs. 41 NG), 2), greater percentage of females in G deaths (48.5% G vs. 33% NG), 3) greater mean number of drugs involved (4.7 G vs. 2.7 NG), 4) greater number of deaths with at least 1 concurrent opioid present (89% G vs. 79% NG), 5) greater number of deaths with at least 1 concurrent benzodiazepine present (70% G vs. 49% NG), and 6) less alcohol involvement (11% G vs. 25% NG). Significant differences were also found in the concurrent drugs present in G and NG deaths. During 2005-14, alprazolam, oxycodone, hydrocodone, and diazepam were among the five drugs most frequently identified in both G and NG deaths, along with clonazepam (G deaths) and ethanol (NG deaths). The top five drugs present in G deaths during 2015-16 were the same as 2005-14 (although frequencies varied). However, fentanyl and heroin were the most frequently identified concurrent drugs in NG deaths during 2015-16 (~32% of cases each). Significantly greater percentages of G decedents had a documented history (medical, other records) of drug and/or alcohol abuse as well as existing cardiovascular, psychiatric, pulmonary, or hepatic disorders compared to NG decedents. Analysis of gabapentin blood concentrations found that 40% were above the usual therapeutic maximum (20 mcg/ml), and a potential therapeutic indication for use was identified in only 28% of cases. Gabapentin overuse/abuse may contribute to many drug-related deaths with significant differences found compared to those deaths not involving gabapentin. However, gabapentin's contribution to toxicity relative to the other detected drugs in these deaths remains uncertain.

P47 Autopsy Case of Nephronophthisis and Fat Overload Syndrome

R. Baldzizhar, P. Katzman

University of Rochester Medical Center, Strong Memorial Hospital, Rochester, New York, USA

Background

Nephronophthisis is an autosomal recessive, genetically heterogenic renal disease with identified mutations in a number of genes that encode proteins involved in the function of primary cilia. The infantile form is characterized by mutations in the NPHP2 gene, which leads to end stage renal disease. Extrarenal manifestations may include bone anomalies, hepatosplenomegaly and portal fibrosis, situs inversus, septal cardiac defects.

Methods

Patient was a 22 month old female with a past medical history of failure to thrive, chronic kidney disease, nephrogenic diabetes insipidus, G-tube dependence, and chronic liver disease of unclear etiology. Two liver

biopsies were most consistent with acute hepatitis and a renal biopsy showed chronic tubulointerstitial nephritis, secondary focal segmental glomerulosclerosis, proliferative arteriosclerosis, and microscopic renal dysplasia. She was re-admitted with acute worsening of hyperbilirubinemia and transaminitis with electrolyte disturbance. On day 10 of her hospital stay patient inadvertently received IV lipid infusion over 2 hours rather than the typical 20 hours and subsequently developed respiratory distress, increasing abdominal ascites, and bleeding from mucous membranes and intravenous lines sites. Patient was resuscitated with blood products and became more alert with improved respiratory status. Later she had sudden decompensation, received cardiopulmonary resuscitation, more blood products, electrolyte replacement, and abdominal paracentesis. Unfortunately the patient was unable to be resuscitated and died.

Results

Autopsy gross findings included anasarca, multiple small abdominal and parietal petechial hemorrhages. Serosanguineous fluid was found in the pleural cavities and abdominal cavity. Microscopic findings confirmed diagnosis of macronodular liver cirrhosis accompanied by marked cholestasis and bile duct proliferation with intervening areas of parenchymal hemorrhagic necrosis. Pancreas showed acute pancreatitis. Kidneys had bilateral patchy chronic interstitial nephritis with interstitial fibrosis and cortical necrosis with atrophic tubules with dilatation, variably thickened basement membranes, and calcifications, and immature glomeruli.

Conclusion

This case represents an interesting combination of a rare inherited disease and a rare potentially fatal treatment complication. By whole exome sequencing this patient had a novel (non-inherited) STAT3 mutation that was not described in patients with nephronophthisis. The fat overload syndrome described after rapid infusion of lipids can also be accompanied by hepatosplenomegaly, respiratory distress, and spontaneous hemorrhage associated with anemia, leukopenia, thrombocytopenia and coagulopathy. It is not clear in this case to what extent the two diseases overlapped to cause the patient's death. However, given this patient's pre-existing nephronophthisis with declining status, the fat overload syndrome may have been the factor leading to death.

P48 Nonterrorist-Related Suicide Due to Explosion: A Case Report and Review of the Literature

S.M. Crook¹, S. Maines¹, L. Lippincott²

¹University of Kentucky, Lexington, Kentucky, USA; ²Central Kentucky Medical Examiner Office, Frankfort, Kentucky, USA

Historically, explosion-related deaths were primarily accidental (particularly within the workplace) or homicidal in nature. In the late 20th century, terrorist acts in the form of "suicide bombings" became notable and frequent occurrences reported in the media. A rare, but important, subset of explosion-related deaths occur in the form of nonterrorist suicides and require special attention. We report the case of a 49 year old male who was found deceased in his bathroom with massive craniofacial injuries. Neighbors stated he had been acting paranoid recently and was seen shooting a gun outside his home earlier that day. At the scene, an air rifle was found at the victim's feet and wires were found in his hands and on the bathroom floor. According to scene investigators, the wires were consistent with those used to detonate blasting caps. No explosive devices were found at the scene or in the house. Radiographs of the body revealed very rare radiopaque foreign particulate matter in the head. At autopsy, extensive injuries to the mid craniofacial region were identified and included comminuted fractures of the facial bones and basilar skull, lacerations of bilateral frontal cerebral lobes, and subdural and subarachnoid hemorrhages. A tooth and small fragment of irregular copper-colored metal were recovered from the lacerated frontal lobe tissue. Contusions and abrasions of the upper extremities were the only

other injuries noted. Toxicologic analysis of postmortem blood was positive for methamphetamine, alprazolam, and hydrocodone. The cause of death was determined to be blunt force injuries sustained from a self-inflicted blasting cap explosion.

Nonterrorist-related suicides by explosives are rare. This case highlights the importance of a comprehensive scene investigation and thorough postmortem examination in explosion-related deaths. In this case, the explosive itself was destroyed, leaving a paucity of physical evidence of the device both at the scene and within the body. Therefore, it is important for medical examiners to have a working knowledge of the variety of explosive devices used and to recognize injury patterns consistent with explosion-related deaths. In addition, it is imperative to rule out other causes of death that may be masked by an explosion, such as gunshot and stab wounds. We will discuss the types of explosives used and the injury patterns seen as it relates to manner of death.

P49 Persistent Left Superior Vena Cava as Part of a Wound Path in a Fatal Stabbing

S.L. Stauffer¹, L.W. Jackson²

¹University of Iowa Hospitals and Clinics, Iowa City, Iowa, USA;

²Hennepin County Medical Examiner's Office, Minneapolis, Minnesota, USA

Persistent left superior vena cava (PLSVC) is a rare but often asymptomatic venous anomaly in the thorax, with case reports and reviews indicating its presence in 0.4% of the general population. A right superior vena cava is also identified in approximately 90% of these cases. An isolated PLSVC (i.e. present in the absence of a right superior vena cava) is rarer still, present in only 0.04% of the population, and can be associated with increased susceptibility for arrhythmias.

We present a case of a pregnant 23-year-old woman who died due to multiple sharp force injuries inflicted by another individual. Agonal breathing and the pregnancy were noted by first responders at the incident scene, therefore the woman was transported via ambulance to a local hospital. A left thoracotomy was performed in the emergency department simultaneous with an emergent caesarian section. The operating physician identified an actively bleeding large caliber blood vessel adjacent to the heart (believed at the time to be the left pulmonary artery) and sutured the defect. Despite the emergent surgical intervention, both the woman and baby died shortly thereafter.

The autopsy examination revealed many incisions and stab wounds on the mother's face, neck, torso, and extremities. Internally, an emergently placed suture was noted in an anomalous large caliber left-sided thoracic vessel. Further examination of the cardiopulmonary vasculature revealed that this sutured vessel was a PLSVC that drained directly into a markedly dilated coronary sinus. There was absence of a right superior vena cava. The PLSVC was a component of the fatal wound path of a stab wound of the mother's chest, that perforated the left shoulder, left upper lung lobe, pericardium, left superior vena cava, and penetrated the left atrium. While PLSVC is generally considered to be an anatomic variant with little clinical consequence when the right superior vena cava is preserved, its occurrence with concomitant absence of a right superior vena cava may lead to susceptibility for arrhythmias. Though any injury to major cardiac vessels poses a threat to survival, the presence of a PLSVC in this decedent was particularly significant as it was injured during the stabbing and presented an unexpected challenge to the treating surgical team during resuscitative efforts. Our report underlines the importance of careful examination of the anatomy involved in a wound path, as well as awareness by the treating physicians and pathologists of anatomic variants that may be encountered.

P50 Suicide By Fire: A Case Report And Review Of The Literature

P.D. Pittman¹, M. Aurelius²

¹Duke University Hospital, Durham, North Carolina, USA; ²Office of the Chief Medical Examiner, Raleigh, North Carolina, USA

Suicide by fire, self-burning, or self-combustion is a highly aggressive and dramatic method of suicide, that entails pouring flammable materials onto oneself and igniting it with the intention of severely hurting or killing oneself. Historically, this act has had powerful cultural meaning and political impact across the world, most notably in eastern, African and Asian countries, where this act accounts for more than 70% of all suicides. In westernized countries, such as the United States, successful completion of suicide by fire is exceedingly rare, accounting for approximately 1% of all reported suicides. This low rate of success is often attributed to increased sophistication and treatment of severe burns, thus leading to less successful attempts and a greater length of survival with marked morbidity. Those at greatest risk for suicide by self-burning are individuals between the ages of 30 and 59, and those with a past medical history of substance abuse/dependence disorders and/or a psychiatric disorder such as psychosis or major depressive disorder. Additionally, victims of suicide by burning are significantly more likely to be female when compared to all victims of suicide by all methods. Forensically, it is critical to meticulously differentiate manner of death for any suspected case of suicide by self-burning from accidental burns and homicide, as evidence and witness accounts may be limited.

This is a case of a 53 year old white female with a lengthy medical history of bipolar disorder, depression and domestic violence who was found deceased and fully charred in her residence after it was entirely engulfed by flames. According to witnesses the decedent had been acting erratically the day of the fire, had been burning candles in her bedroom, and was using social media to make suicidal threats and post cryptic messages stating "fire is the gateway to the underworld". A complete forensic autopsy was performed, and formalin fixed paraffin embedded sections were submitted for histologic examination. Herein we will focus on the medical findings, autopsy findings and death investigation that favor this case to be a suicide by self-burning. This case emphasizes the importance of death scene investigation-including investigating social media sites when looking for intent-toxicological evaluation.

P51 Turner Syndrome is Another Risk Factor for Aortic Dissection

A. Edgecombe

Office of the Chief Medical Examiner, Calgary, Canada

A 34-year-old female was at church when she developed chest pain, diaphoresis, nausea and vomiting. She attended the Emergency Room where blood work and chest x-ray demonstrated non-specific findings. An ECG showed prolonged QT. She was later discovered unresponsive in the waiting room. Her medical history was significant for Turner syndrome, obesity and hypertension. An echocardiogram performed one month prior showed a mildly dilated and hypertrophied left ventricle. At autopsy, she had a height of 156 cm and weighed 137 kg with a body mass index of 56.3 kg/m². There was a DeBakey type I aortic dissection with hemopericardium and bilateral hemothoraces. Hypertensive heart disease was also noted with cardiomegaly (520 g) and concentric left ventricle hypertrophy.

Turner syndrome occurs sporadically in 1/2000 live female births when there is a partially or completely missing X chromosome. Clinical features include short stature, high arched palate, short webbed neck, broad chest with widely spaced nipples, lymphedema of the hands and feet, skeletal malformations and premature ovarian failure. Abnormal cardiovascular development is seen in 50% of cases including bicuspid aortic valve, aortic coarctation, aortic dilatation, atrial and ventricular septal defects and pulmonary venous abnormalities. There is a 100 to 200-fold increased risk

of aortic dissection. The median age of dissection is 30-35 years, but it is described in those less than 20 years. Most who develop aortic dissection have aortic valve disease, coarctation and/or hypertension. Pregnancy increases the risk. The underlying genetic or vascular abnormality is not known. Those with Turner syndrome also have increased risk of premature hypertension and coronary artery disease. Other associated features include renal anomalies (horseshoe kidney), ocular disease, hearing loss, osteoporosis, fractures, diabetes, Hashimoto's thyroiditis and Celiac disease.

In the presented case, a clinical diagnosis of aortic dissection was not considered. Many teachings/textbooks neglect to include Turner syndrome as a risk factor for aortic dissection. Physicians should be aware of the vastly increased risk of cardiovascular disease with Turner syndrome, especially aortic dissection.

P52 Toxicology Reports – Do They Stand On Their Own, Or Fall Flat On Their Asp?

L. Labay, R. Middleberg, M. Rieders

NMS Labs, Willow Grove, Pennsylvania, USA

Forensic toxicological testing is an integral component of death investigation. Simplistically, specimens are collected at autopsy and transported to the laboratory for analysis; upon completion of work, a report detailing the findings is issued. As important as laboratories are in the death investigation process, however, the procedures that relate to the administrative and quality assurance practices that happen "behind the scenes" remain largely unknown by those using the services. In fact, many are unaware of the role they play in the ultimate utility of toxicological analyses and findings. The factors that influence toxicological findings, and ultimately interpretation of results, can be classified as pre-analytical and analytical factors. Pre-analytical factors run the gamut from sample collection techniques to proper preservatives in collection vessels to specimen storage. Analytical factors are generally related to the laboratory and include accreditation, proficiency testing participation, analyst training and qualification, specimen storage and discard, and security of data and records retention. The purpose of this submission is to underscore, discuss and demystify both pre-analytical and analytical processes that can drastically affect specimen integrity and utility, analyses and interpretation of findings. A comprehensive checklist will be provided as a handout which can be used to ensure that no important aspect related to toxicological testing is overlooked.

P53 Death of a Student Related to Occupational Exposure of Fentanyl

L. Labay¹, C. Catanese², J. Gropper³

¹NMS Labs, Willow Grove, Pennsylvania, USA; ²Westchester County Medical Center, Westchester, New York, USA; ³Gropper Law Group PLLC, New York, USA

Fentanyl is a potent synthetic opioid that is used as a surgical anesthetic and to alleviate symptoms associated with chronic or postoperative pain. The drug exhibits similar pharmacological and toxicological actions including analgesia, euphoria, respiratory depression and physiological dependence as other opiate-related drugs. Therapeutic misuse and abuse of fentanyl is extremely dangerous because of the low concentrations necessary to induce respiratory depression. During various periods of time, clusters of fentanyl-related deaths have been reported and more recently deaths have been attributed to illicitly manufactured fentanyl or its analogues.

A case is reported of a 22-year old male pharmacy student who died in hospital one-week after being occupationally exposed to fentanyl while working at a compounding pharmacy. On the fourth day of his internship he was found collapsed approximately 10 minutes after being last observed. He was unconscious and not breathing; resuscitative efforts were made. The medical diagnosis was acute anoxic brain injury with complex seizures. His family reported they observed flinching whenever

his toes were touched, balling up of the fists upon receiving injections, occasional tears and some eye movement beneath the eyelids. Significant pathology findings included pulmonary congestion and edema.

Toxicological testing of a blood sample collected at hospital admission showed the presence of fentanyl at 0.21 ng/mL. Cause of death was attributed to transdermal fentanyl exposure. Proper training, supervision and handling of any samples that may contain fentanyl or fentanyl analogue(s) is essential. In addition to the use of personal protective equipment it has now become necessary for co-workers to recognize the signs and symptoms associated with opioid overdose, have access to naloxone and possess the skills to administer it. The purpose of this presentation is to underscore the need to appropriately train all staff, especially those who are inexperienced with laboratory safety practices and may not appreciate the potency of fentanyl and other related substances.

P54 Intravaginal Stuffing of Methamphetamine Resulting in Accidental Overdose

D.C. Peterson¹, L.J. Haldiman¹, B.R. Pietak¹, C.C. Frazee², U. Garg²

¹Jackson County Medical Examiner's Office, Kansas City, Missouri, USA;

²Children's Mercy Hospitals and Clinics, Kansas City, Missouri, USA

"Body packing" and "body stuffing" are two well-known methods of concealing illicit drugs. Body packing is defined as the act of swallowing packets containing illegal drugs for the purpose of smuggling in contrast to body stuffing, which is the swallowing of relatively small amounts of loosely wrapped drug due to fear of arrest. Generally, the packaged drugs are orally ingested. Because body stuffing is usually hastily done when there is threat of arrest, the drugs may be poorly packaged leading to leakage and accidental overdose. Intravaginal body stuffing is infrequently seen but can have similar dire consequences if the drugs are poorly packaged. In fact, drugs absorbed through the vagina may lead to higher concentrations as they do not pass through the liver and undergo first pass metabolism.

The deceased was a 28-year-old female with a history of celiac disease, stage IV chronic kidney disease, and previous drug abuse, specifically methamphetamine. She was found dead in her secured residence. At autopsy, a clear ziplock-style plastic bag was recovered from her vagina containing approximately 12 mL of yellow-tinged liquid and clear crystal-type material. Toxicological analysis of blood from the ascending portion of the aorta revealed methamphetamine concentration of 50,000 ng/mL and amphetamine concentration of 2,800 ng/mL, greatly exceeding the toxic levels. In a series of 13 adult deaths attributed to methamphetamine overdose, the average postmortem blood methamphetamine concentration was just 1,000 ng/mL, fifty times less than that found in the deceased. It is important to point out that toxicological analysis in this case was performed on heart blood, and methamphetamine has been found to undergo postmortem redistribution. Methamphetamine heart/femoral blood concentration ratios averaged 2.1 (1.2 – 5.0) in a series of 20 deaths or 1.9 in a series of 5 cases (range 1.0 – 3.8). Intravaginal body stuffing is a rarely seen method of concealing illicit drugs. Accidental overdose secondary to poor packaging of the illicit drugs "stuffed" in the vaginal canal can occur. This case demonstrates vaginal drug absorption resulting in fatal concentrations of methamphetamine. It is not clear why the deceased in this case was body stuffing. However, scene investigation revealed partially packed bags in her apartment. She had recently spoken with her mother about possibly traveling several hours to visit a relative.

P55 Intimate and Familial Murder: Examining Trends in Domestic Violence Homicides in Oklahoma from 2010-2014

A.L. Wiens¹, A. LaMothe², R. Thrasher², J. Lanter¹

¹Oklahoma Office of the Chief Medical Examiner, Tulsa, Oklahoma, USA;

²Oklahoma State University, Tulsa, Oklahoma, USA

Domestic violence homicides have been subject to research for many decades; however, the literature is lacking thorough analysis of domestic violence in relationships other than those of intimate (dating/marital) partners which includes relationships such as parents, siblings, or roommates. This study focuses on trends and characteristics of domestic violence homicides that occurred in Oklahoma from January, 2010, through December, 2014. The electronic database of the Office of the Chief Medical Examiner was culled for data. During the 5-year timeframe examined, 1,318 cases were classified as homicide, and 368 cases (28%) met the designation of domestic violence homicide as defined by Title 22 of the Oklahoma State Statutes in the Protection from Domestic Abuse Act. Data collected for each case included demographics of the decedent and offender, relationship between decedent and offender, cause of death, and number of injuries to the decedent. Collected variables were statistically analyzed to test significant associations. Firearm injuries accounted for 48% of domestic violence homicides; blunt force trauma was the second most common cause of death at 23% of cases. Current dating/marital partners were the most common offenders (142 cases), followed by parent of the decedent (49 cases), child of the decedent (46 cases), and other family members (47 cases). Ages of decedents ranged from infancy (0 years) to 91 years old; 48% of decedents were male and 52% were female. Female decedents were more likely than male decedents to die of mechanisms such as asphyxia, drowning, thermal injuries, or combined mechanisms. The most common type of domestic violence homicide was between an offender and decedent of opposite genders who were of the same race. Male offenders were more likely than female offenders to be family members of the decedent. In contrast to published national data stating fathers are the most common offenders when the decedent is a child under age 5 years, our study found that female offenders were more likely than male offenders to kill their children. Greater than 10 injuries were most commonly seen when the offender was the ex-partner (dating and/or marital) of the decedent, the parent of the decedent, or the dating/marital partner of the decedent's parent. Our findings differ from national data in several areas, and this study illustrates the prevalence of family member domestic violence homicides despite their relative exclusion from published literature on domestic violence which tends to focus on intimate partner relationships.

P56 Suicide by Chop Saw

E.R. Amoresano¹, S. Shapiro²

¹University of Vermont Medical Center, Burlington, Vermont, USA;

²Vermont Office of the Chief Medical Examiner, Burlington, Vermont, USA

Suicide by power saw is exceedingly rare and there are only a few case reports in the forensic literature describing the use of band, circular, or chain saws. The use of chop saws in suicide, however, has not been described. Presented here are three cases of suicide committed using chop saws. All three of the decedents were men between the ages of 65 and 80 with a documented history of depression. While one case exhibits the injury pattern seen in the vast majority of power saw suicides, namely a single large cutting wound to the head or neck, the other two cases involve the complete amputation of an upper extremity - a finding reported in only one other power saw suicide case. The death investigation and pertinent autopsy findings are summarized and compared to the literature regarding suicide by other power saws.

P57 Hymen Absence in Prepubertal Girls and Chronic Sexual Abuse: Review of the Literature and a Case Report.

G. di vella¹, M. D'Amato², S.M. Curti³, F. Luparello³, E. Coppo⁴, A. Urbino⁴, C. Petetta³

¹Università degli Studi di Torino, Torino, Italy; ²S.C. Legal Medicine,

A.O.U. "Città della Salute e della Scienza", Turin (Italy), Torino, Italy;

³Department of Public Health and Pediatric Sciences, University of Turin,

Torino, Italy; ⁴Department of Pediatric Emergency, A.O.U. "Città della Salute e della Scienza", Turin, Torino, Italy

Absence of hymenal tissue is not a documented congenital anatomical variation. This finding in prepubertal females has been interpreted as a sure sign of blunt force or penetrating trauma. Because of the rarity of complete absence of the hymen, this presentation will present a review of the literature and describe a definitive case. A review of the literature on child abuse was conducted using the Medline electronic database with the following algorithm: ("Child Abuse"[MeSH]) AND "Hymen"[MeSH]. The search strategy yielded 73 potentially relevant articles. Searching for case reports on the absence or loss of hymenal tissue, none of the articles met the research criteria: 32 were excluded on the basis of the title, 26 after reading the abstract, and 10 after reading the entire article. Six of the abstracts or articles were not available for review. Among the 1792 cases observed in the "Ospedale Infantile Regina Margherita" (Turin) unit dedicated to the evaluation of suspected abused or mistreated children ("Bambi"), only one case was characterized with a complete absence of hymenal tissue. This data encompassed a time period from February 2002 to July 2016. A 5-years-old girl was hospitalized in the Child and Adolescent Psychiatry Unit due to episodes of chest pain, seizure activity, aphasia, hypotonia and no response to stimuli. During the last two years she had vaginal loss and hyperemia, abdominal pain, headache and cystitis. After her spontaneously talking about repeated touching by her "bad uncles," the little girl was examined by specialized unit staff. The genital area inspection was conducted in the supine and the knee-chest position with colposcopy. The medical examiner observed normal prepubertal external genitalia, no vulvar hyperemia and total absence of hymenal tissue. Despite the fact that, in most cases of suspected sexual abuse, the child has no physical signs, in a limited number of cases those signs are present. While the child's tale remains the most important evidence in case of suspected sexual abuse, physical findings resulting from sexual abuse, when present, are fundamental in the legal arenas. A defect in the posterior half of the hymen wider than a transection is consistent as a diagnostic sign of penetrating trauma and/or sexual contact, so this finding, combined by a corroborated story of the child, is interpretable as sexual abuse due to repeated introduction of blunt instruments into the vagina.

P58 Two Cases of Deaths by boiling in Japanese-style Bathtubs

S. Iwadate¹, K. Iwadate², K. Hayashi³

¹Kyorin university, Tokyo, Japan; ²Jikei University School of Medicine,

Tokyo, Japan; ³Tokyo Medical Examiner's Office, Tokyo, Japan

The so-called bathtub deaths are one of the most common manners of unexpected deaths among Japanese elderly persons. The annual number of fatalities is reported to be approximately 15,000. The cause of many such deaths is drowning resulting from the loss of consciousness while a person is soaking in a bathtub. In some cases, the person dies of stroke or heart attack immediately before falling under the water. In Japanese-style bathtubs without thermostatic controls, these death cases sometimes involve postmortem burn injuries due to the boiling water in the tub. However, death due to burns caused by boiling hot water in a bathtub is rare. We demonstrate two cases of bathtub deaths in which the persons were suspected to have been boiled alive, and compared these with a case of death due to the onset of subarachnoid hemorrhage while the person was soaking in a bathtub in which the body was boiled postmortem.

P59 When Spirituality Leads to Death: Case of Ascetic Fasting and Autopsy Findings

G. Di Vella¹, M. D'Amato², F. Lupariello¹, C. Petetta¹, S. Curti¹
¹Università degli Studi di Torino - Italy, Torino, Italy; ²AOU Città della Salute e della Scienza, Torino, Italy

A 62 year-old-male teacher, not suffering from chronic diseases, underwent periodically prolonged fasting to perform "purification cycles." The last of these fasts was initiated about three weeks before his death. His companion also fasted, but had ceased due to weakening. The teacher had endured more prolonged fasting in the past, so no one had been alarmed, despite his progressive, debilitating condition. However, this time, the man experienced a sudden respiratory crisis and loss of consciousness, and despite resuscitation attempts, he succumbed. Inside the house, the authorities found many notes posted on the doors and walls, with inscriptions in French invoking deities, probably of Christian inspiration. There were also writings regarding the fact that the man's body could reborn only if he had entrusted it to rituals performed by hands of women. The man had never been diagnosed with any psychiatric illness, despite the facts that neighbors were aware of his eating habits and he claimed to have paranormal powers in association with his partner. The external examination showed severe cachexia (weight 39.4 kg, height 178 cm, body mass index 12.43 kg/m²), diffuse muscle atrophy, thin skin, sunken eyes, sharp orbital margins and nose tip, sunken supraclavicular fossae and intercostal spaces, prominent ribs, and abdominal concavity extending from the costal margins to the iliac bones. The internal findings consisted of almost absent adipose tissue of the abdominal wall, reduced internal fat stores (omentum, mesentery, perirenal, subepicardial), and decreased weight of all organs with exception of the brain. The gastrointestinal tract was thin with translucent walls, and the stomach and small bowel were empty. The gallbladder was distended and filled with fluid bile. According to the literature, the macroscopic and histopathologic findings confirmed the prolonged fasting. The characteristics included brain edema, interstitial edema in heart tissue, heart myofibril fragmentation, congestion and steatosis in liver parenchyma, necrosis in gastric and intestinal mucosa, and reduced glycogen in the liver and muscle storage. Toxicological tests for the presence of alcohol and drugs in body fluids were negative. The medical examiner attributed the death to a sudden onset of a ventricular arrhythmia. In fact, according to the literature, anorexic patients show a prolongation of the Q-T interval which can result in a ventricular tachyarrhythmia. This risk becomes high when weight loss falls below 35% of the ideal, a finding in this subject's case.

P60 Pharmaceutical Tablet Excipients in a Placenta: Sign of Intravenous Abuse or Contamination?

D.K. Arboe¹, R.J. Miller¹, C. Niblo¹, J. Sawady², J.F. Tomaszefski²
¹Oklahoma Office of the Chief Medical Examiner, Eastern Division, Tulsa, Oklahoma, USA; ²MetroHealth Medical Center, Cleveland, Ohio, USA
Prescription drug abuse is a rising trend due in part to their relative ease of procurement. Injection of crushed tablets is used to increase the intoxication effect with a more immediate onset. In addition to the active ingredient(s), tablets contain a variety of excipients such as croscopovidone, talc, starch and microcrystalline cellulose. Associated pulmonary complications of injected tablets include dyspnea, hypoxemia, and pulmonary hypertension due to the filtration of the particles by the smaller vasculature of the lungs. The appearance of these foreign bodies has been well-documented in the lungs and less so in other organs due to the size of the excipient and the associated inability to exit pulmonary circulation. To our knowledge, placental tissue with tablet excipients has not been described in the literature.
We present a placenta from a case of intrauterine fetal demise that fell under the jurisdiction of the Oklahoma Office of the Chief Medical Examiner due to maternal incarceration and drug use. Additional maternal

history included advanced maternal age (36 years old), multiparity, and previous abortions. The fetus was determined to be nonviable at 14 weeks gestational age and was delivered vaginally via induction at 17 weeks gestation age. Histologically, the first trimester placenta showed foreign bodies morphologically consistent with croscopovidone (a disintegrant) and microcrystalline cellulose (a disintegrant and diluent) concentrated in what appeared to be vascular spaces without an associated cellular reaction. They were most prominent in the umbilical cord and membranes with additional rare foci in the chorionic plate and maternal sinusoids. Vascular immunohistochemical staining (CD 34) performed at MetroHealth Medical Center (Cleveland, OH) did not show an endothelial lining where the material was located. Among many theories relating to how tablet excipient foreign bodies became embedded within the placental tissue, the one primarily agreed upon is that placental surface contamination likely occurred during delivery from the presence of dissolved labor induction tablet(s) in the vaginal canal. Had the excipients been present in vascular spaces, the size of the particles would require the presence of a right to left vascular shunt that bypasses the lung vasculature. Given this mother had no known cardiac history, clinical knowledge of the placental findings would be paramount for her primary care physician(s). Given such clinical implications, etiologic consideration for histologically observed foreign bodies is not only important for forensic pathologists, but also for other surgical pathologists and our clinical colleagues.

P61 A 6-year-old Child Dead into a Locked Car: A Case Report

L. Andreello¹, S.D. Visonà², M. Pinorini³, E. Grata³, L. Morini², A.M. Osculati²
¹Medicolegal service of Canton Ticino - Switzerland, bellinzona, Switzerland; ²University of Pavia, Pavia, Italy; ³Istituto Alpino di Chimica e di Tossicologia, Olivone, Switzerland

The authors present a case of a 6-year-old girl who was accidentally entrapped inside a vehicle.
On 21st of July 2015 a 6-year-old, healthy girl was forgotten by her mother in their locked car, which was parked under the blazing sun with the windows all closed. The child was found dead in the car at 8 pm, after about five hours (the time she remained into the car is not precisely known). A crime scene investigation was carried out at 9 pm and then the rectal temperature was measured at 10pm, pointing out 107.6 degree F (42°C); the environmental temperature, into the car with the doors opened, was 82.82 degree F (29.9°C). The police investigations revealed that it was not possible to open the doors or the car windows from inside the car, as it was locked by remote key.
Postmortem TC did not point out any significant findings. A forensic autopsy was performed, followed by histologic examinations and toxicology. The internal examination revealed pleural and pericardial petechiae, massive generalized congestion and gastric material into the upper and lower airways. The histology confirmed the macroscopic findings; toxicology was negative for exogenous substances. A postmortem blood-gas analysis performed during the autopsy revealed a pO₂ of 6.85 kPa, a HbO₂ of 41.8%, satO₂ of 42.6%.
On the basis of the results of the autopsy, as well as the histology and the toxicological data, the cause of death was identified as an heat stroke. In the present case, the car became an oven as left in a sunny area at high temperatures. A car parked in direct sunlight can reach 131 degree F (55 °C) to 171degree F (77.1 °C) in 15 minutes.
The literature reported that in 2003, 42 children died, of heat stroke, as a result of being left inside a vehicle.
Leaving children unattended in or around vehicles is a serious problem. Leaving children in cars without knowing the consequences can be regarded as ignorance, but has to be considered child neglect in medico legal terms.

This report underlines the need to increase the public awareness that vehicles are lethal to children, as some vehicles cannot be opened from inside if locked by remote key. Every effort should be made to make compulsory by law the equipment of devices to detect a person into cars at the moment of the locking; such precaution can save children.

P62 Sudden Death in Pregnancy: A Fatal Case of Acute Chorioamnionitis

A.M. Wilson

University of Michigan, Ann Arbor, Michigan, USA

Maternal deaths, as defined by the World Health Organization (WHO) as "the death of a woman while pregnant or within 42 days of termination of pregnancy, irrespective of the duration and site of the pregnancy, from any cause related to or aggravated by the pregnancy or its management but not from accidental or incidental causes," are increasing in the United States. Maternal deaths may present to the Medical Examiner as sudden unexpected death. The differential diagnosis is broad and may include causes resulting from injury, violence or drug use. Natural conditions include cardiovascular disease, cardiomyopathy, pulmonary thromboemboli, hemorrhage, or infection. Although infection is not as frequent as it was decades ago, it remains an important factor in maternal morbidity and mortality. Acute chorioamnionitis is an extremely rare cause of sudden maternal death.

This is a case of 30-year-old Caucasian female who presented to the emergency department with complaints of severe abdominal pain and lower back pain. She was gravida 2, para 0 and at 32 weeks gestation. Prenatal history is unknown. She reported no significant prior medical history. She reported leaking fluid from her vagina for the prior 4 days associated with chills for at least 2 days. Upon arrival in the emergency department, she was tachycardic, febrile and had chills. Fetal heart rate monitoring showed non-reassuring fetal heart tones and she was taken for an emergent Cesarean section. A live-born infant was delivered without complications. Purulent fluid was noted in the uterus and cultures were taken. Immediately following delivery, she experienced refractory hypotension, pulseless electrical activity, cardiac arrest and death. A full autopsy was performed. The placenta was examined. The autopsy demonstrated post-surgical changes of the uterus and pelvis. The uterus showed myometritis and septic emboli. The visceral organs displayed diffuse intravascular thrombi. The placenta revealed tri-vessel necrotizing acute vasculitis/funisitis of the umbilical cord. Special stains were positive for bacteria. The placenta disc showed acute necrotizing chorioamnionitis and acute chorionic plate vasculitis with multifocal vascular thrombosis. The uterine cultures were positive for *Streptococcus anginosus*, a rare case of acute chorioamnionitis. Toxicology was noncontributory.

This case illustrates acute chorioamnionitis associated with disseminated intravascular coagulopathy (DIC) and hemodynamic collapse resulting in maternal death. This case is presented to promote recognition of the increasing rate of maternal deaths and acute chorioamnionitis as a cause of sudden maternal death, along with its associated autopsy and placental findings.

P63 A Suicide Involving Multiple Gunshot Wounds: Importance of Correlation of Thorough Scene Investigation and Autopsy Findings in Determining Manner of Death

P.P. Beckham, M. Kessler

Office of the Chief Medical Examiner - Northern District, Manassas, Virginia, USA

Single gunshot wound suicides are a common type of case in any medical examiner's office. We discuss a case in which the importance of scene investigation and correlation to autopsy findings are essential. Police initially reported the apparent suicide of a 67-year-old White male, found deceased in a recliner at home, from what appeared to be a single, perforating gunshot wound of the head. The decedent lived in hoarder

conditions and had been depressed over having to clean and sell his home. At autopsy, the decedent was found to have five gunshot wound paths to include a wound of the head, two of the abdomen, one of the right thumb, and one of the right forearm, each with distinctive patterns of close/contact range gun fire. The injuries of the abdomen and extremity would not have been initially fatal. Police re-evaluated the scene. A black .357 revolver was discovered on an adjacent couch with one spent casing, and was partially under a blanket, as if tossed. A silver .357 revolver with blood on it was at the decedent's hip. This revolver had two spent casings, and the cylinder was rotated in a direction counter to the rotational mechanism with one of the spent casings in the active chamber, thus indicating the gun was loaded one bullet at a time. A box of Remington .357 Magnum ammunition was located next to the decedent with blood on the inside and outside. From comparison of scene findings to autopsy findings, it is postulated that the decedent attempted to use the revolver found on the couch, shot himself once in the abdomen and when the result was a nonfatal, painful injury, he tossed it onto the couch. The decedent then loaded one round into the other revolver, as he is doing this it fired, creating the superficial wound paths of his upper abdomen, right thumb, and right forearm. Distinctive patterns of soot and stippling and precise locations of the wounds, made it probable that these three wound paths are the result of a single bullet trajectory. The decedent loaded another round, this time, inflicting a contact gunshot wound to the head, which after exiting, struck the ceiling and dropped plaster onto the final scene including onto the gun on the couch. This is a case in which a complete scene review and comparison of autopsy findings are vital in determining manner of death.

P64 All Tied Up: How a Good Death Investigation Turned a Possible Homicide into an Unusual Natural Death

A. Spencer, H. Reinhard, W.K. Ross

Penn State Hershey Medical Center, Hershey, Pennsylvania, USA

In the post-*Fifty Shades of Grey* era, paraphilias have increasingly become represented in the mainstream media. This, along with the infinite accessibility of the internet, creates an environment in which more people are exposed to these ever creative and, sometimes unusual, sexual practices. Then when the unexpected happens, these situations can pose very unique challenges for death investigators.

We present the case of a 69 year old male who was found deceased in his residence by police. All doors and windows were locked and undisturbed. The decedent's valuables were also undisturbed. The body was prone, laying across the bed in the bedroom. The body exhibited long blonde hair and was dressed in women's attire. The decedent appeared tightly and elaborately bound around the torso, but loosely around the legs and ankles and wrists behind the back. The decedent was blindfolded and gagged. A plastic pump apparatus and remote control were found in the hands. A serrated knife was found on the floor at the decedent's feet and 2 pairs of scissors were adjacent to the body. These scene findings were concerning for a possible homicidal or accidental death.

At autopsy, removal of the wig and clothes confirmed the decedent to be the male homeowner. Externally, the body showed signs of advanced decomposition. No injuries were identified. The oropharynx was unobstructed. The pump apparatus was inserted into the rectum and contained a vibrating toy that was connected to the remote. A pet collar was fastened around the genitals along with a condom containing another vibrating toy.

Internal examination revealed cardiomegaly, dilated cardiomyopathy, and atherosclerosis occluding the left anterior descending coronary artery by 40%. The remainder of the LAD's lumen was entirely occluded by an adherent blood clot.

The unique circumstances of this case made it crucial to rule out a homicidal or accidental death. Taken together, scene and autopsy findings ruled out these possibilities. The tight intricate bindings on the torso resulted from decompositional bloating and represented self-bondage.

The knife and scissors found with the body likely represented "fail safes" to escape the bindings if necessary. The blood clot in the LAD likely caused a devastating acute ischemic event, consistent with acute coronary syndrome and a natural cause of death. This case illustrates the importance of a thorough and collaborative death investigation. In the face of increasingly complex cases, both scene and autopsy findings are critical to a successful investigation.

P65 The Role of Mitragynine in Two Postmortem Investigations

M.A. Frank¹, D. Papsun², K. Graf², B. Logan²

¹Denver Office of the Medical Examiner, Denver, Colorado, USA; ²NMS Labs, Willow Grove, Pennsylvania, USA

Mitragynine, the primary active alkaloid of the plant Kratom, is increasingly seen in postmortem investigations; however, the role of mitragynine in death is far from understood. Mitragynine has divergent pharmacological activity with both stimulant and opioid effects at different doses, and has garnered attention as a natural alternative for pain management. The toxicity of mitragynine is debated in the scientific community, as advocates highlight its long history of use in Southeast Asia, while opponents denote increasing adverse events associated with its use in the West. Quantitative reports of mitragynine in biological specimens from forensic investigations in the literature are sparse; therefore, the intention of this report is to detail mitragynine findings in two fatalities from Colorado.

Case 1 is a 30-year-old male with a known history of substance abuse and recent onset of seizures, who was found deceased in a state of decomposition on the living room floor of his apartment. Drug paraphernalia was found at the scene, including a plastic baggie containing a green powdered substance, empty capsules, and a pill organizer containing capsules of green powder. Toxicology results confirmed mitragynine in postmortem iliofemoral blood (23 ng/mL). The cause of death was ruled as acute mitragynine intoxication, with nontraumatic seizures of undetermined etiology and cardiomegaly contributing; manner was accident.

Case 2 is a 28-year-old male found deceased lying in bed in his residence. Scene investigation revealed several recreational marijuana products, bags containing green powders inscribed "THAI" and "GREEN MAENG DA", and an unlabeled plastic bag containing a white powder. Autopsy findings include pulmonary and cerebral edema, urinary retention, and severe constipation. Toxicology results confirmed furanyl fentanyl (140 ng/mL) and mitragynine (1400 ng/mL) in postmortem iliofemoral blood. The cause of death was ruled as the combined toxic effects of furanyl fentanyl and mitragynine, with a manner of accident. Concentrations of novel substances such as mitragynine are largely undefined as to what constitutes a desired effect, therapeutic use, or toxicity. Case studies are needed for accurate interpretation of these findings in forensic investigations. Due to the current public debate regarding the safety profile of mitragynine, it is necessary to quantitate this substance in biological specimens, as well as put the finding into the appropriate context for the case. Determining the significance of mitragynine detected in postmortem investigations continues to challenge toxicologists and medical examiners, as these investigations are confounded by variables such as polysubstance abuse and underlying pathology.

P66 WITHDRAWN

P67 Causes of Mesenteric Ischemia at Autopsy: the Importance of Histologic Examination

N. Alemar Hernandez, K.M. Thomas, A. Rapkiewicz
NYU Langone Medical Center, New York, New York, USA

Background:

Acute mesenteric ischemia refers to the sudden reduction in intestinal blood flow. Acute mesenteric ischemia is a medical emergency that can be catastrophic and despite surgical intervention has a mortality rate of up to 47%.

The most common causes of mesenteric arterial occlusion are thrombosis and thromboembolism, but there are other etiologies such as atherosclerosis, hypotension, hypercoagulability, vessel compression and, less common, vasculitis. We herein report five autopsy cases with mesenteric ischemia.

Materials and Methods:

The New York University Langone Medical Center and the Bellevue Hospital computer databases were queried for all deaths relating to mesenteric ischemia from the period 2000-2017.

Results:

Mesenteric ischemia was identified as a contributing cause of death in 5 cases. The cohort includes men and women who range in age from 53 to 83 years. The immediate cause of death was septic shock (3), multiorgan failure due to cholesterol atheroembolism and pulmonary thromboembolism. All cases underwent a dissection of the mesenteric vasculature. The etiology of the mesenteric ischemia was considered arterial in origin in all five cases. All of the cases showed involvement of the large intestines, whereas only the arterial thrombosis and thromboembolism cases showed concomitant involvement of the small intestines. The cases with arterial thrombosis had continuous involvement of small bowel in the geographic distribution of the superior mesenteric artery. The case with atherosclerosis also had continuous involvement of bowel in the geographic distribution of the superior and inferior mesenteric arteries. The cases of vasculitis and arterial thromboembolism had multifocal involvement of the bowel in a non-vascular pattern.

Conclusion:

Acute mesenteric ischemia often results in fatal outcomes as the clinical presentation is often non-specific. Therefore, proper documentation and dissection in cases where mesenteric ischemia and infarction is suspected or discovered at the time of autopsy is imperative to determining the etiology. The mesenteric vasculature should be dissected followed by histologic sections. The supplementation of microscopic examination of the vasculature will reveal the uncommon causes of mesenteric ischemia.

Arterial thrombosis is most often due to atherosclerosis and tends to occur in areas of severe narrowing, the superior mesenteric artery at its origin, superimposed on an atherosclerotic plaque. The most common vasculitis associated with mesenteric ischemia is polyarteritis nodosa. Arterial thrombosis and atherosclerosis are usually associated with more extensive bowel involvement than atheroembolism, as well as involvement of watershed areas. Atheroembolism and vasculitis more commonly present with segmental or multifocal involvement of bowel.

P68 Cirrhosis and Emphysematous Change in a 12 Month-old male infant

D.S. Bumgarner, D. Borys

Loyola University Medical Center, Maywood, Illinois, USA

A preterm, male infant, born at 24 and 5/7 weeks gestation, with history of necrotizing enterocolitis and respiratory distress syndrome, expired at 1 year old of acute bronchopneumonia. The patient required mechanical ventilation and total parenteral nutrition for most of his life. The patient also had a history of elevated alkaline phosphatase, hypertriglyceridemia,

transaminitis, and hyperbilirubinemia. Autopsy was performed at the request of the parents. Gross findings included hepatomegaly and pulmonary congestion. Histologic examination revealed cirrhotic liver with prominent bile duct proliferation and plugging. Emphysematous change with hypertrophy of bronchiolar smooth muscle was identified in the lungs. Given the unusual hepatic and pulmonary findings in a 1 year old, the diagnosis of alpha1-antitrypsin (A1AT) deficiency was considered. Immunohistochemical stains for A1AT revealed extensive deposits of A1AT in the liver. Periodic acid-Schiff-diastase stain, however, revealed diastase-sensitive intrahepatic glycogen. The lungs displayed extensive A1AT staining. An A1AT deficiency presents with diastase-resistant intrahepatic glycogen deposits and markedly decreased A1AT staining in pulmonary sections. Given these findings, A1AT deficiency was ruled out. A search of the literature revealed that prolonged parenteral feeding may induce cirrhosis and hepatic/biliary derangements, including those seen in this patient. Prolonged ventilator dependence may also lead to emphysematous change and hypertrophy of bronchiolar smooth muscle. Thus, the unusual pulmonary and hepatic findings were consistent with prolonged parenteral feedings and mechanical ventilation. This case demonstrates A1AT deficiency may mimic the histologic changes seen in critically ill patients dependent on intravenous nutrition and mechanical ventilation.

P69 Not Another Drug Overdose

M.E. Pietrangelo¹, W. Kupsky²

¹Macomb County Medical Examiner's Office, Mount Clemens, Michigan, USA; ²Harper Hospital, Detroit, Michigan, USA

Introduction: Alexander disease is a rare, progressive, usually fatal neurologic disease in the leukodystrophy family, first described in 1949 by Dr. W. S. Alexander. Historically there were three forms based on age of onset. Currently two forms are described. Common to all types are abnormal aggregates of Rosenthal fibers in the brain and spinal cord, caused in 95% of cases by a mutation in astrocyte glial fibrillary protein (GFAP).

Methods: This is a case report of a 26 year old male found unresponsive in the shower by his father. After resuscitation he was found to have suffered anoxic brain injury. The working diagnosis of his treatment team was prolonged QT syndrome due to psychiatric medication. Of concern to the medical examiner's office was a recreational drug overdose, due to the frequency of overdoses occurring in his local demographic. He underwent autopsy.

Results: Autopsy was unremarkable except for cerebral and cerebellar edema with tonsillar and uncal notching consistent with anoxic brain injury. Toxicology was unremarkable. Microscopic sections of autopsy tissue were unremarkable except for the brain. Sections of the hippocampus, pons, medulla, cerebellum and proximal cervical spinal cord showed widespread Rosenthal fibers and eosinophilic granular bodies with gliosis, consistent with later onset Alexander disease.

Discussion: These unexpected findings demonstrate that seemingly routine cases may prove to be quite the opposite. This case emphasizes the importance of a complete death investigation including medical record review, a full autopsy, toxicology and microscopy to accurately determine the cause and manner of death.

P70 Hemopericardium Complicating Pacemaker Implantation

K. Obenson¹, R. Belliveau²

¹Saint John Regional Hospital, Saint John, Canada; ²Coroners Office-Department of Public Safety, New Brunswick, Saint John, Canada

Introduction: The implantation of pacemakers and cardioverter-defibrillators has become routine and most implantation procedures are completed uneventfully. Under exceptional circumstances the procedure may be complicated by a fatal outcome.

Case presentation: The decedent, a 77 year old male status-post stent placement for stenotic coronary artery disease, was admitted a day after

placement of an implantable cardioverter-defibrillator for syncope and heart block. His medical history was also significant for aortic valve stenosis with an ejection fraction of 56. He suffered a sudden cardiovascular collapse during a CT scan which showed an accumulation of blood in the pericardial sac.

Autopsy examination was significant for hemopericardium of 300 to 400 cc of both liquid and clotted blood. Pre-dissection conventional radiograph of the explanted heart confirmed pacemaker lead insertion into the right atrium and right ventricle. Stents were observed in the right coronary artery and left anterior descending coronary artery. There was no gross evidence of acute myocardial infarction or ventricular rupture. A small hemorrhagic focus measuring approximately 5 mm in diameter, was observed on the right ventricular border of the heart approximately 2 cm from the apex. Section through this area showed a transmural hemorrhagic needle track through which the lead partially protruded. The ventricular myocardium in this area was approximately 1 mm thick. The right atrial lead retained its placement position. There was substantial aortic valve stenosis and calcification. Cross section of the stented coronary arteries showed no thrombi. Histologic sections of the right ventricle confirmed gross impression of acute hemorrhage. No recent ischemic changes were observed in any of the other myocardial sections. There was no evidence of underlying cardiomyopathy. The implanted device was interrogated by the electrocardiology unit and the results reviewed with the cardiac electrophysiologist. No malfunction was detected. The immediate cause of death was classified as hemopericardium and cardiovascular collapse due to ventricular perforation complicating pacemaker insertion. Underlying contributory factors included ischemic coronary artery disease and aortic stenosis. Conclusion: Death due to pacemaker lead insertion is a rare but important consequence of the procedure and should not automatically be considered de facto evidence of medical negligence. The extremely thin right ventricular muscle wall likely increased the risk of perforation. This was the first known fatality in our center.

P71 Rapid Screening for Drugs of Abuse Using Different Bodily Fluids Using a Workplace Urinary Preliminary Screening Test

E. Moffatt, M. Hunter, A. Hart, H. Narula

San Francisco Office of the Chief Medical Examiner, San Francisco, California, USA

The Alere iCup™ is a urine toxicology point of care screen developed for workplace drug preliminary screening and screens for 14 classes of drugs, including morphine, oxycodone and propoxyphene. The test results are easily read by a horizontal line for "positive" and a blank are for "negative" within five minutes. The amount of urine needed is approximately 30 milliliters (but smaller amounts can be used).

The recommended fluid is urine. We have also used cerebral spinal fluid and serum with results corroborated with toxicology lab testing. In general, vitreous fluid is not of sufficient volume and pleural fluid can give variable results. We have tested approximately 40 cases so far with no frank contradictions between the "cup" result and our in-house toxicology results. Testing with more cases is ongoing.

In our experience, if the "cup test" is negative, then the actual toxicology testing done by our in house lab is also negative. Additionally, the urine can still be sent for GC-MS testing, by pouring it out of the test cup and into a red top and sending to the toxicology lab. Serum can be used, but obtaining enough serum (approximately 10 milliliters) by centrifugation can be time consuming. The Alere iCup™ also works on fluids which are early to mildly moderately decomposed; the cloudiness and red color of the urine does not seem to affect the test results.

Drawbacks of this screen include inability to test for fentanyl or ethanol. Also, some opiate deaths occur so quickly that the offending

drug is not yet in the urine (necessitating the use of another fluid such as cerebral spinal fluid for a trusted result). The strength of this test is to rapidly screen for several classes of drug with reliability of a negative result and more accurately inform the need for an autopsy and/or further toxicology testing.

P72 Drug-related Hypersensitivity Reactions and the Autopsy

N.J. Barna, A. Rapkiewicz

New York University Medical Center, New York, New York, USA

Background

Adverse drug reactions are important causes of morbidity and mortality with cutaneous eruptions being among the most common manifestations encountered in the United States. Drug-related hypersensitivity reactions are classified as a spectrum of disorders that encompass drug related eosinophilia with systemic symptoms (DRESS), toxic epidermal necrolysis (TEN) and Stevens-Johnson Syndrome (SJS). We herein report four deaths in the setting of drug-related hypersensitivity reactions.

Materials and Methods

The New York University Medical Center and Bellevue Hospital pathology database was queried for all deaths related to DRESS, TEN or SJS from the period of 2000 – 2017.

Results

DRESS or SJS were found as a contributing cause of death in 4 cases. The cohort included three females and one male with an age range of 50 – 65 years. An inciting medication was clinically identified in three cases with allopurinol implicated in three cases. Two cases had successful clinical abatement of skin findings and thus no macroscopic post-mortem skin changes were identified; however, all four cases had microscopic findings indicative of various stages of damage. Microscopic skin findings ranged from minimal interface vacuolar change in an example of resolving DRESS to patchy epidermal necrolysis in SJS. Complications of drug reactions and associated treatment seen in this series were often clinically unrecognized and included disseminated cytomegalovirus (CMV) infection, necrotizing eosinophilic myocarditis and fulminant liver necrosis.

Conclusion

Autopsies for cases of drug-related hypersensitivity reactions present a unique challenge in that a diverse array of complications may result in the setting of such disease. Gross skin findings should be fully documented with attention to body surface area involvement and areas of post-mortem artifact such as skin slippage must be avoided during sampling. Skin lesions of DRESS can be temporally heterogeneous; therefore, areas of both resolving and new eruptions should be sampled. Cases of DRESS may have greater mucous membrane involvement than is appreciated clinically while not qualifying as SJS/TEN. Viral reactivation may occur as a direct effect of drug hypersensitivity or in the setting of aggressive pre-mortem immunosuppressant administration; thus, there should be careful microscopic evaluation for viral pathology as well as a low threshold for ancillary testing. Liver failure is a common complication in drug-related hypersensitivity disorders and may be recognized in the pre-mortem period; however, autolysis may preclude definitive microscopic characterization of necrosis at autopsy.

P73 Type IV Glycogen Storage Disorder (Andersen Disease) in an 8 Week Old Infant

B.J. Murie, J. Newell

Penn State Hershey Medical Center, Hershey, Pennsylvania, USA

Glycogen storage disorders are a rare group of genetic conditions which affect the manner in which glycogen is structured and stored in various organs. Type IV Glycogen storage disorder (Andersen Disease) affects glycogen branching enzyme, which leads to alteration of the molecular structure of glycogen, resulting in poor utilization of energy stores and failure to thrive in infancy. This rare condition is generally life threatening,

as liver failure may ensue, and death often occurs within the first few years of life.

We report the case of an 8 week old male, born at 33 weeks gestation for decreased fetal movement and polyhydramnios, who suffered diminished cardiac function, atelectasis, and hypoxic encephalopathy during hospitalization. Prior to death, a muscle biopsy was performed which showed polyglucosan bodies consistent with a glycogen storage disorder, and was confirmed by genetic analysis which showed a mutation in the *GBE1* gene. He continued to require aggressive medical management, and the family chose to withdraw care, given the poor prognosis. Findings at autopsy showed a non-dysmorphic male infant with no gross pathologic abnormality seen in the organs. Microscopic examination of the tissues showed extensive involvement of multiple organs by intracellular polyglucosan bodies, compatible with Andersen Disease. Polyglucosan bodies are seen as spheroid pale blue predominantly cytoplasmic inclusions highlighted by Periodic Acid Schiff (PAS) staining. The organs involved included the heart, liver, and skeletal muscle.

Taken together, the genetic studies and autopsy findings confirmed the diagnosis of Andersen Disease, and the cause of death was believed to be complications associated with this disease process. This was a case in which more findings were seen microscopically than macroscopically, illustrating a possible diagnostic challenge. Although rare, such genetic disorders should be considered in the differential diagnosis in the death of infants.

P74 Dismemberment by Chainsaw: A Case Report

A.L. Wiens, A.K. Berg, C.J. Zambrano

Oklahoma Office of the Chief Medical Examiner, Tulsa, Oklahoma, USA

Postmortem efforts to conceal a homicide may include various scenarios such as clandestine burial, dumping the body into a waterway or off a roadway, burning of remains, or dismemberment. Dismemberment involves the use of a tool to divide or section the remains to aid in their transport, dispersal, and/or concealment. Over the past 42 years, the Oklahoma Office of the Chief Medical Examiner has investigated 16 dismemberment cases. Eleven of these cases displayed evidence of cut and/or saw marks; chop marks were noted in three cases; in one case, the method of dismemberment was undetermined. We present a unique case of dismemberment involving a chainsaw, the only such case in the state's series. Following dismemberment, the fragmented human remains were dumped at a city waste site where they were discovered approximately five weeks after disposal. The remains were differentially preserved, displaying a mixture of skeletonized and partially-skeletonized elements. Portions of the limbs were enclosed in a duffel bag and had identifiable tattoos which aided in tentative identification of the individual. Anthropological examination of the skeletal remains revealed very large false start kerf marks from the chainsaw, a unique bisection of the vertebral column in the sagittal plane, thermal modification, and evidence of two gunshot wounds. Positive identification was established by fingerprint comparison. The police investigation and suspect confessions support the findings of two gunshot wounds and postmortem dismemberment with a chainsaw. To this date, the instruments and site of dismemberment have not been located.

P75 Malignant Asphyxia Due to Laryngeal Adenosquamous Carcinoma: A Case Report

K.L. Palmer, M.D. Gosse, D.J. Pelletier, R.A. Robinson, S.L. Stauffer

University of Iowa Hospitals and Clinics, Iowa City, Iowa, USA

Adenosquamous carcinoma of the head and neck is a rare and aggressive epithelial neoplasm that has features of both adenocarcinoma and squamous cell carcinoma. Central airway obstruction leading to asphyxia and sudden death has been reported in a number of malignancies; however, no such cases due to laryngeal adenosquamous carcinoma have been reported. We present a case of a 57-year-old male

with a six month history of cough, shortness of breath, and hoarseness who presented to his doctor with a worsening cough. He was given an oral corticosteroid and a consultation with otolaryngology was scheduled for the following week to evaluate need for diagnostic laryngoscopy. The following morning the patient was found unresponsive in his home. Despite resuscitation efforts, the patient was pronounced dead shortly thereafter. At autopsy, a 6 x 5.5 x 3 cm laryngeal mass causing near complete airway obstruction was identified. The mass extensively involved the supraglottic and glottic regions bilaterally, as well as the left submandibular gland, pre-epiglottic space, and true and false vocal cords. Histologic examination of the tumor revealed widely invasive adenosquamous carcinoma. The cause of death was determined to be asphyxia due to internal airway obstruction by laryngeal adenosquamous carcinoma. Adenosquamous carcinoma is a rare malignancy displaying distinct areas of glandular and squamous differentiation, with at least 10% of each component required for the diagnosis. This tumor most commonly occurs in areas where adenocarcinoma is common, such as the lung, pancreas, stomach, intestines, and breast. Less commonly, it may arise in areas where squamous cell carcinoma is more commonly encountered, such as the uterine cervix and larynx. Fewer than 100 cases of laryngeal adenosquamous carcinoma have been reported in the literature. Airway obstruction secondary to malignancy may result from tumors that arise from the airway itself, direct invasion of the airway, external compression by a paratracheal tumor, or tumor fragmentation with airway impaction. Sudden death caused by malignant airway obstruction is a rare phenomenon, and this report highlights the importance of examination of the respiratory system for unrecognized malignancies.

This case demonstrates the appearance of a very rare benign condition that can lead to significant anatomic alteration of the airway and respiratory compromise in the setting of a mixed drug intoxication.

P76 Mixed Drug Intoxication In A Patient With Tracheobronchopathia Osteochondroplastica (TPO).

*N. Dhungana, R.L. Eigsti, R.A. Robinson, S.L. Stauffer
University of Iowa Hospitals and Clinics, Iowa City, Iowa, USA*

Tracheobronchopathia osteochondroplastica (TPO) is an extremely rare benign disorder characterized by growth of osteocartilaginous submucosal nodules that project into the tracheal lumen. This abnormal tissue growth is asymptomatic in most individuals, but in some it can produce non-specific symptoms such as chronic cough, hoarseness, dyspnea, and hemoptysis. In some individuals with moderate to severe disease, it can lead to airway stenosis and significant respiratory compromise requiring surgical resection and/ or placement of a tracheostomy.

We present a case of a 48-year-old woman with a past medical history of TPO status post tracheostomy placement, as well as Crohn's disease, depression, and a reported possible suicide attempt. The decedent was last known to be alive the evening before her death when she had sent text messages of apparent suicidal intent to her sister and her husband. She was found deceased in her bed by her husband approximately 6.5 hours afterword, with her tracheostomy tube attached to her neck via a strap, but the end of the tube outside of the stoma. Of note, the decedent had recently filled a prescription for hydrocodone and a pill count done at the scene revealed that 54 of the hydrocodone pills were unaccounted for. Autopsy examination revealed a stoma in the anterior midline neck with surrounding exophytic red granulation tissue formation and adjacent redundant skin and soft tissue. There was obstruction of the larynx (above the level of the tracheostomy) by submucosal osteocartilaginous nodules. Histological sections of the larynx showed heterotopic bone and cartilage formation. Postmortem toxicology examination of femoral blood was positive for opioids and benzodiazepines, including hydrocodone (135 ng/mL). The cause of death was attributed to mixed drug (alprazolam, hydrocodone) intoxication. Obstruction of the laryngeal airway by heterotopic ossification of the larynx (tracheobronchopathia osteochondroplastica) was noted to be a contributing significant condition, as it likely contributed to the degree of respiratory compromise in this decedent. The manner of death was classified as suicide.

NOTES

**National Association of Medical Examiners
2017 Annual Meeting – Author Index**

Abate, Marie A	P46	Covington, Theresa	9.4
Aiken, Sally S	2.1	Crandall, Laura	9.5
Alemar Hernandez, Noelia	P67	Criss, Benjamin E	P1
Allard, Corey T	P35	Cronin, Rose M	3.1
Amoresano, Elaine R	P56	Crook, Shannon	P34, P48
Anderson, Matthew P	3.13	Crosby, Alex E	1.4
Andrello, Luisa	P61	Crowns, Kendall V	8.1
Andrews, Joe	4.1	Cunningham, Chris R	P27
Andrews, Joseph A	P7	Curti, Serena	P57, P59
Arboe, David K	P60	Dai, Zheng	P46
Aronson, Judith F	P24	D'Amato, Monica	P57, P59
Asakura, Kumiko	P37	Daneshvari Berry, Shamsi	P36
Ashar, Kunjlata	6.5	Danielsen, Travis J	P15
Atherton, Daniel S	11.7	Dean, Dorothy E	P1
Aurelius, Michelle	P50	Deeken, Amy	3.2
Baardsen, Erika	3.12, P21, P43	deJong, Joyce	P23
Baldizhar, Raman	P47	Demetriades, Demetrios	1.2
Bao, Ruijun	10.1	Denmark, Adam M	2.4
Barna, Nicholas J	P72	Dennis, Firchau	P42
Barnard, Jeffrey	P15, P23	Devers, Kelly	P43
Batalis, Nicholas I	P17	Devinsky, Orrin	9.5
Bayleyegn, Tesfaye	11.6	Dhungana, Neha	P76
Beckham, Phinon P	P63	Di Vella, Giancarlo	P57, P59
Belenky, Michael	9.2	Diaz, Francisco J	P9
Bell, Michael	8.4	Dierksen, Jennifer	P13
Belliveau, Robert	P70	DiStasio, Marcello	3.13
Benjamin, Elizabeth	1.2	Dominguez, Carolina	3.12, P13, P20, P21, P22
Berg, Angela K	P74	Driscoll, Dustin	1.3
Berg, Jeremy D	P3	Duff, Deiter J	P26, P27
Blair, Janet M	1.4	Duque, Alexandra	P20
Blake, Brooke H	P24	Eason, Eric	P2
Blau, Dianna M	9.1	Eastridge, Brian J	1.2
Bois, Melanie	P14	Eckhardt, Michael	P2, P14
Borderieux, Cassie	P38	Edgar, Heather J	P36
Borys, Dariusz	P68	Edgecombe, Allison	P51
Botero, Maria E	P21, P22	Eigsti, Renee	P42, P76
Braun, Paula	4.7, 10.3, 11.3	Ennis, W. A	P19
Bravo, Viagnney	P20, P21, P22	Erck Lambert, Alexa	9.4, 9.7
Breiman, Robert	9.1	Ernst, Mary Fran	11.4
Brooks-Lim, Elizabeth	P7	Escobar Alvarenga, Kristin	3.7
Brown, Sharyn P	9.8	Falsafi, Simin	P46
Brown, Theodore T	3.11	Falzon, Andrew L	P40
Bumgarner, Derek S	P68	Faustin, Arline	9.5
Bush, Leah L	7.7	Fowler, Dave R	10.4
Butler, Daniel C	P17	Fowler, David	10.3
Camperlengo, Lena	9.4, 9.7, 9.8	Fowler, Katherine A	1.4
Caplan, Michael J	8.2	Frank, Meredith A	P65
Catanese, Charles	P53	Frazee, C C	P54
Chan-Hosokawa, Ayako	7.4	Fromknecht, Catharine Q	11.6
Chao, Jennifer	P23	Gammill, Charles M	P38
Christensen, Erik D	9.2	Garg, Uttam	P54
Chrostowski, Leszek	3.12, P4, P13	Gegg, Ron J	8.7
Clark, Steven C	11.4	Giffen, Mark A	3.4
Cochran, Elizabeth J	6.3	Gill, James R	3.5
Cohle, Stephen D	P28	Gilliland, MGF	3.9
Collins, Kim A	8.5, 8.6	Gordon, David	6.2
Colman, Skyler	7.5	Gosse, Matthew D	P75
Cone, Jensyn K	3.13	Graf, Kristopher	P65
Conway, Kyle S	3.11, P9	Grata, Elia	P61
Cook, Emilie V	3.10	Grewe, Stefanie	P22
Coppo, Elena	P57	Gropper, Joshua	P53
Corliss, Robert	4.3, P6	Gunther, Wendy M	11.2
Cottengim, Carri	9.4, 9.7, 9.8	Gupta, Avneesh	6.2

**National Association of Medical Examiners
2017 Annual Meeting – Author Index**

Haldiman, Lindsey J	P54	Lin, Charles	10.1
Halladay, Alycia K	6.4	Lin, Peter T	P14
Hamamatsu, Akihiko	P37	Linde, Erin	P18
Harcke, Howard T	8.3	Lippincott, Lauren	P48
Hare, Carolyn K	6.4	Liverman, Christopher	P45
Harrison, William T	P11	Logan, Barry	7.5, P65
Hart, Amy	P71	Love, Sara A	4.2
Hauck, Fern	9.4	Luckasevic, Todd	P19
Havrilla, Lauren A	3.5, P11	Lukefahr, Ashley L	P25
Hawes, Amy	3.3	Lupariello, Francesco	P57, P59
Hayashi, Kino	P37, P58	Lytle, Alyssa L	P29
Helenowski, Marta	3.7	MacLeod, Heather	10.2
Hilbrandt, Robert W	6.5	Maines, Sarah	P34, P48
Hobron, Kathrin "Rosie"	7.7	Marcus, Nashelsky	P42
Hodge, Sarah	11.6	Mazuchowski, Edward L	8.3
Hoelscher, Bryce C	P26	McCleskey, Brandi C	11.7
Howe, Julie	11.4	McDonald, Anna G	3.10
Howell, Kirstin E	3.7	McFadden, Kathryn	6.2
Hunter, Michael	P71	McGuone, Declan	9.5
Ibrahim, Syed	4.5	McLemore, Jerri	3.4, P39
Ishikawa, Martin K	P9	Medwick, Allan J	P8
Issa, Anindita	11.6	Mellen, Paul F	8.2
Iwadate, Kimiharu	P58	Meyers, Sarah	4.2
Iwadate, Sakurako	P58	Middleberg, Robert	P52
Iwatate, Sakurako	P37	Middleton, Owen	4.2
Jackson, Lorren W	P49	Mileusnic-Polchan, Darinka	9.6
Jares, Louis	8.5, 8.6	Miller, Catherine R	P24
Jasnosz, Katherine	P12	Miller, Ross J	7.3, P60
Jentzen, Jeffrey M	11.4	Milroy, Christopher M	2.2
Johnson, Bryan T	10.5	Mock, Allen R	P46
Johnston, Emily O	9.7	Moffatt, Ellen	7.8, P45, P71
Johnston, Robert D	P24	Montonera, Michelle	8.1
Joseph, Maleszewski J	P14	Moody, Mark	5.1
Julson, Janet	P33	Moore, Kellyanna J	P14
Kaplan, James A	P46	Morini, Luca	P61
Karch, Steven B	11.1	Morris-Hughes, Lori	7.7
Katzman, Philip	P47	Murie, Ben J	P73
Kemp, Walter L	P31, P32, P33	Murthy, Stacey	3.14
Kessler, Meghan	7.6, P44, P63	Na, Joo-Young	P10
Kim, Hyeong-Geon	P10	Nakajima, Noriko	P37
King, Theodore M	10.4	Narula, Harminder	P71
Kloss, Julie	4.2	Newell, Jordan	P73
Knight, Laura D	5.1	Niblo, Cheryl	P60
Knorr, Christopher	2.4	Noe, Rebecca	11.6
Kohler, Lisa	3.2	Noguchi, Thomas T	1.2
Koplan, Jeffrey	9.1	O'Connell, Brooke	9.5
Kraner, James C	P46	Obenson, Ken	2.5, P70
Krautscheid, Peter	10.3	Oh, Robert C	4.4
Kuntz, Joanne G	2.3	Oh, Se-Min	P10
Kupsky, William	P69	Oh, Yeon-Ho	P10
Labay, Laura	7.2, P52, P53	Ohanessian, Sara E	7.6
Laib, Annie M	P16	Oliver, William R	2.6
Lambert, Alexa E	9.8	Ordi, Jaume	9.1
LaMothe, Ashley	P55	Osculati, Antonio M	P61
Langlois, Neil	3.6	Palmer, Kendra L	P75
Lanter, Debra A	8.7	Pandey, Maneesha	7.1
Lanter, Joshua	P55	Papsun, Donna	7.5, P65
Lantz, Patrick E	3.10	Parai, Jacqueline L	2.2
Lawless, Megan R	P18	Park, Ji Hye	P10
Ledoux, Charles	7.4	Parks, Bruce	P25
Lee, Young Seok	P10	Parks, Sharyn	9.4
Lenfest, Stephen	3.14	Parks Brown, Sharyn	9.7
Lesnikova, Iana	3.9	Parrado, Erica	P21, P22
Lewis, Katharine K	10.3	Pasquale-Styles, Melissa A	10.1

**National Association of Medical Examiners
2017 Annual Meeting – Author Index**

Pelletier, Daniel J	P75	Stauffer, Stephanie L	P35, P49, P75, P76
Perch, Steve	3.2	Sterkel, Alana K	4.3
Perkins, Ashley R	3.12, P4, P20, P21, P43	Stoppacher, Robert	5.1
Pestaner, Joseph	9.2	Strauch Rivers, Selly	P13
Peterson, Diane C	P54	Sully, Claire J	3.6
Petetta, Caterina	P57, P59	Sweede, Sharon	P39
Petrosky, Emiko	1.4	Theroit, Danny	7.4
Pietak, B. R	P54	Thomas, Kristen M	P67
Pietrangelo, Mary E	P69	Thomas, Sarah	3.12, P13, P22
Pinckard, J. Keith	2.3, 11.3	Thompson, Katrina	4.3
Pinneri, Kathryn	4.5	Thrasher, Ron	P55
Pinorini, Maria Teresa	P61	Tiomak, Wieslawa	6.3
Pittman, Patricia D	P50	Tomashefski, Joseph F	P60
Poland, Stephanie	11.6	Topmiller, Robert G	P1
Pontoriero, Francesco	6.1	Tormos, Lee Marie	P41
Powers, Robert H	P1	Ulmer, Pamela S	9.2
Prahlow, Joseph A	P8, P23, P28	Urbino, Antonio	P57
Prahlow, Samuel P	P28	Uribe, Paul S	4.4
Presnell, S. Erin	P41	Visonà, Silvia D	P61
Pryor, Caroline	P40	Waite, Kristy	3.2
Rabah, Raja	P3	Walker, Stewart	3.6
Raghunathan, Pratima	9.1	Warner, Margaret	4.7, 10.3, 11.3
Rapkiewicz, Amy	P67, P72	Webb, Milad	P9
Redman, Sarah D	11.6	Weinand, Jared	P32
Reed, Stacey	P12	Weinberg, Mitchell L	4.1, 4.6
Regensburg, Margaret	10.1	Weinberg, Seth	4.1, 4.6
Reichard, Ross	9.5	Wiens, Andrea L	7.3, P55, P74
Reiner, mark	8.5, 8.6	Wilcoxon, Rebecca M	4.2
Reinhard, Heidi L	P30, P64	Will, Joshua S	4.4
Revercomb, Carolyn H	6.1, P40	William, Christopher	9.5
Richards, Virginia L	6.5	Williams, Karl	P19
Rieders, Michael	7.2, P52	Wilson, Allecia	6.2, P62
Rivers, Selly R	3.12, P4, P43	Winston, David C	3.1
Robinson, Gabriel R	11.2	Wisniewski, Thomas	9.5
Robinson, Robert A	P75, P76	Wood, Kimberly A	4.6
Rodriguez, William C	10.4	Wright, Claire	2.5
Rogers, Christopher	1.2	Wright, Jacquelyn M	P44
Rogers, Kathleen	P40	Xing, Wenxue	P5
Rose, Claire E	3.3	Yates, Bill	11.7
Ross, Anne	7.5	Yerdon, Charlotte	5.1
Ross, Wayne K	P30, P64	Zaferes, Andrea	5.1
Sathyavagiswaran, Lakshmanan	1.2	Zaki, Sherif R	9.1
Sawady, Joram	P60	Zambrano, Carlos J	P74
Schaeffer, Luther	1.1	Zoumbros, Nicholas	6.2
Schild, Michael H	P11		
Schmidt, Carl J	3.11		
Schumann, Cynthia M	6.4		
Schuppener, Leah M	P6		
Scordi-Bello, Irini	P16		
Sens, Mary Ann	P31, P32, P33		
Shah, Kabeer	P14		
Shah, Krishna	P34		
Shapiro, Steven	P56		
Shapiro-Mendoza, Carrie	9.4		
Smith, Gordon S	P46		
Snell, Kenneth	P3		
Snuderl, Matija	9.5		
Soriano, Benjamin	3.7		
Souccar, Sami	P5		
Spagnolia, Alessandra	P31		
Spencer, Amanda	P30, P64		
Spencer, Merianne R	4.7		
Sporn, Thomas A	P11		
Stacy, Carl C	P26, P27		

**SAVE THE
DATE!**

NAME 2018
Annual Meeting &
Exhibits

Hilton West Palm Beach
West Palm Beach, FL

October
12-16
2018

