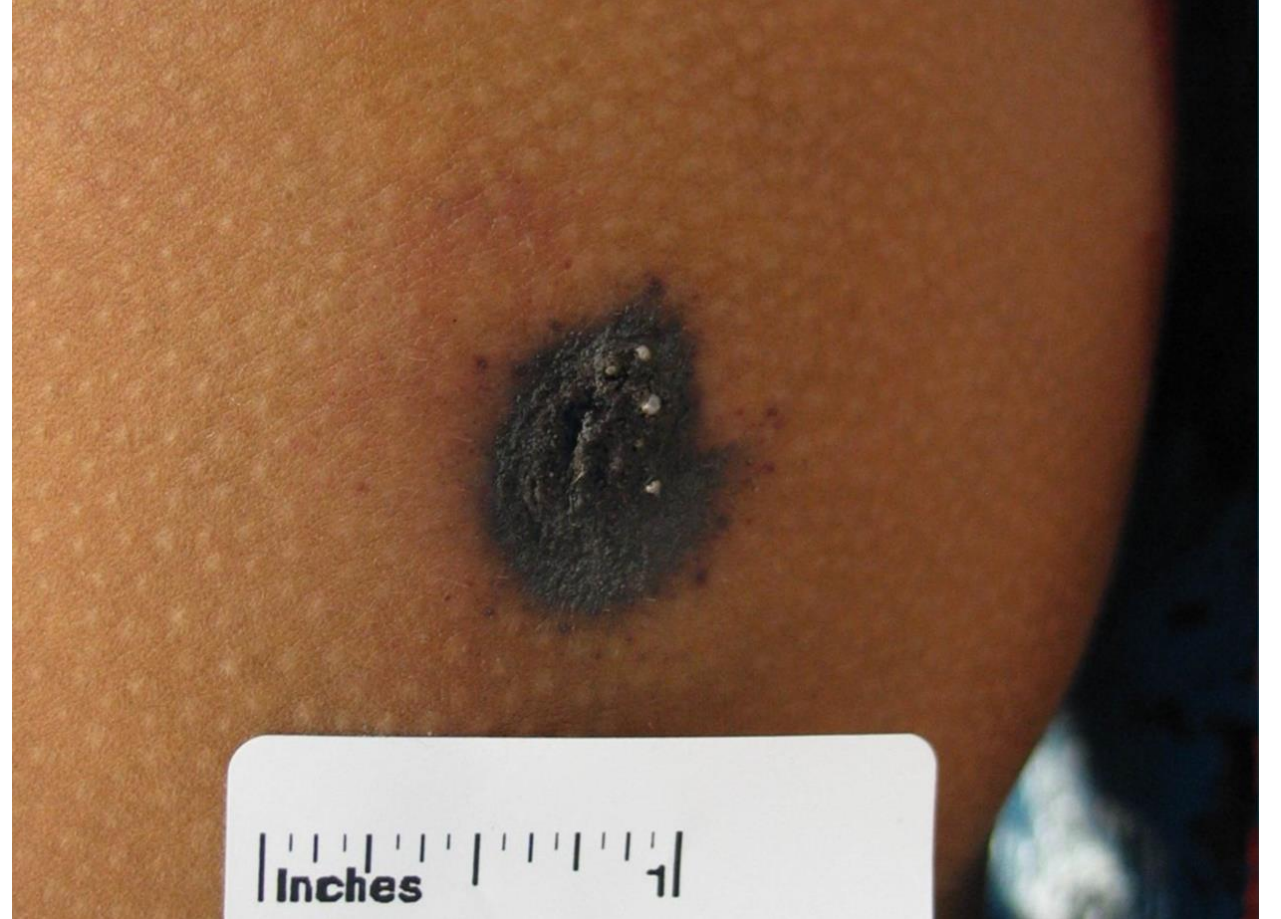
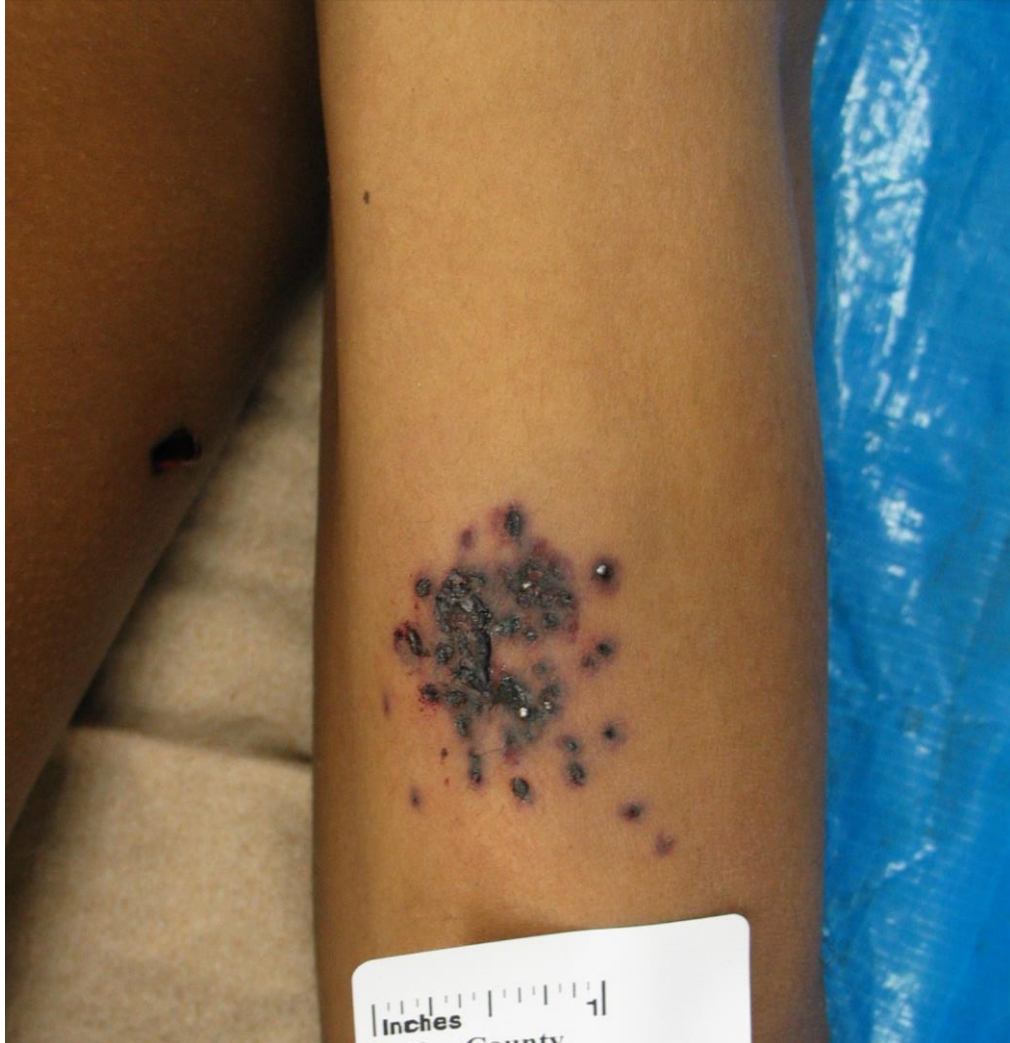


Case #29

NAME Educational Activities Committee



A 23-year-old male was found with multiple firearms injuries. The injuries shown are from the left upper extremity. These injuries are most consistent with:

- a. .410 gauge shotgun, birdshot
- b. .20 gauge shotgun, buckshot
- c. .12 gauge shotgun, birdshot
- d. 9mm handgun, Glaser round
- e. .38 handgun, snake shot

Answer: .38 handgun, snake shot (E)

The decedent was a 23-year-old male with multiple firearm injuries, several of which showed the tight clusters of shot depicted in the photos. Of note, there was no significant penetration of the shot beyond skin and subcutaneous tissue. There were also other classic gunshot entrance wounds (single round defects) identified on the decedent, one of which is barely seen on the lateral chest in the first image. It turned out that there was only one shooter and one weapon – a revolver containing both standard bullets and snake shot.

a. .410 gauge shotgun, birdshot (22.67% responses)

The injuries in the photos show a tight cluster of small birdshot without a central defect. In addition, one of the two photos shows a very small cluster (less than ½ inch wide) with focal soot and stippling. At this range, you would expect to see only a central defect caused by the tightly clustered shot and the wad. Such a tight cluster with no central defect or wad strike (and minimal projectile penetration) is more consistent with snake shot.

b. .20 gauge shotgun, buckshot (7.84% responses)

In addition to the lack of a central defect as noted above, the shot seen in the photos is too small to be buckshot, even from a smaller gauge shotgun.

c. .12 gauge shotgun, birdshot (19.7% responses)


Same explanation as the first choice.

d. 9mm handgun, Glaser round (10.81% responses)

A Glaser Safety Slug is a hollow point projectile containing a core of compressed #12 lead shot and capped by a polymer ball. The bullet penetrates the skin as a single projectile. After penetration, the shot emerges from the core bullet. Thus, you would not observe the individual shot on the skin as in this case, unless there was some sort of interposed target. Even if this occurred, the shot would not be this tightly clustered and the defects would be far more irregular.

e. .38 handgun, snake shot (CORRECT ANSWER, 38.98% responses)

Snake shot cartridges are small versions of shotgun cartridges designed to be fired from a handgun. Unlike the Glaser round, which is a single bullet containing the lead shot, these tiny pellets are encased in a hollow plastic capsule that shatters during firing. This ammunition is designed for snakes and rodents and has very little penetrating power.



Example of medium caliber snake shot ammunition.
(Photo provided by Southwestern Institute of Forensic Sciences)



Example of small caliber (.22) snake shot ammunition broken into components including the plastic cap, shot, and small cardboard wads. Photo provided by Dr. Reade Quinton, Mayo Clinic Rochester.

Reference:

Di Maio VJM. Gunshot Wounds: Practical Aspects of Firearms, Ballistics, and Forensic Techniques. Second ed. Chapter 10, Miscellaneous Weapons and Ammunition (Handgun shot cartridges). Page 301-302