

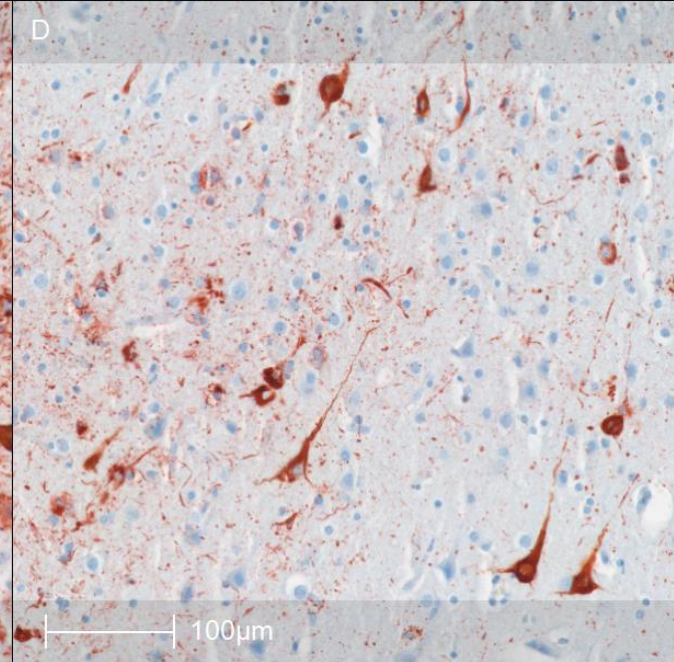
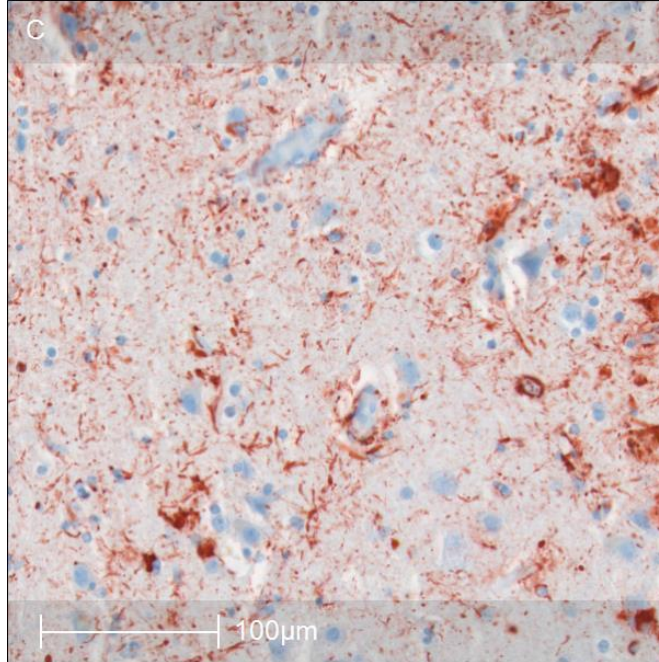
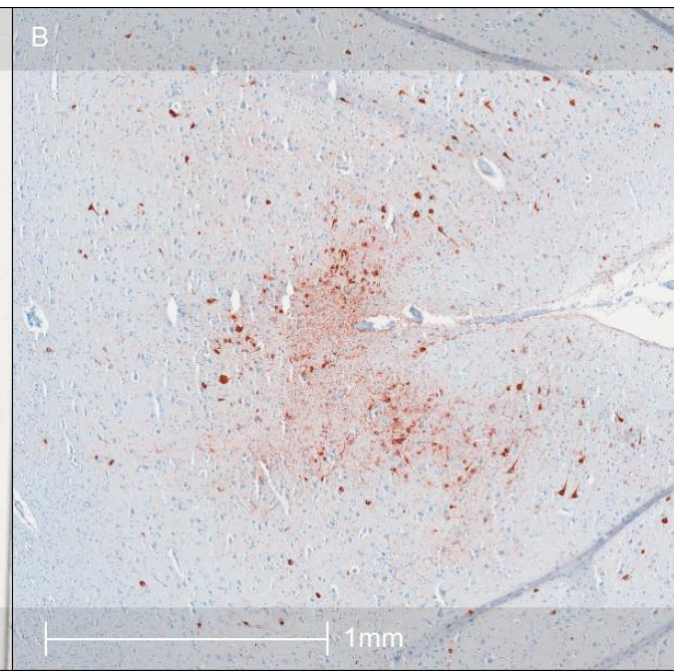
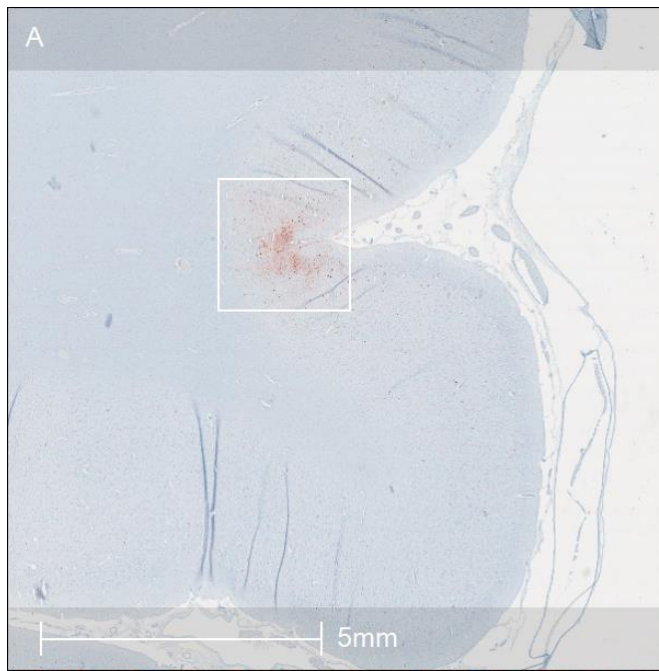


Case #17

NAME Educational Activities Committee

Case History:

A 55-year-old male was found hanging in his basement. Relevant past medical and lifestyle history included military service, tobacco use, depression, hypertension, alcohol use disorder, and parkinsonian symptoms including gait disturbances and motor impairment. Serum toxicology was positive for ethanol and cannabis. His brain had several remarkable gross findings including cortical atrophy and pallor of the substantia nigra (SN). Sections of his frontal cortex were stained for hyperphosphorylated tau protein (p-Tau) (Images below).



Case courtesy of Daniel Kirsch (Boston University)

What is the correct neuropathological diagnosis?

- A. Parkinson's disease
- B. Alzheimer's disease
- C. Chronic traumatic encephalopathy
- D. Corticobasal degeneration
- E. Progressive supranuclear palsy

A. Parkinson's disease (PD) (INCORRECT)

Parkinsonian movement disorder and mood disturbances are characteristic symptoms of PD. Loss of pigmented neurons and gliosis of the substantia nigra is seen in cases of PD. However, the histology above clearly shows a pathological process involving p-Tau, while PD is characterized by accumulation of alpha-synuclein in neurons (Lewy bodies) and neuronal processes (Lewy neurites)^{3,4}.

B. Alzheimer's disease (AD) (INCORRECT)

p-Tau deposition is observed in AD, as is global cortical atrophy. CTE tends to show cavum septum pellucidum, frontal lobe atrophy, temporal lobe diencephalon atrophy, mammillary body atrophy, and ventricular enlargement. AD has more diffuse atrophy and usually particularly profound atrophy of the medial temporal lobe. However, onset of symptoms typically occurs in those 65 y/o and older who do not have familial autosomal dominant form of AD. Histopathologically, CTE can be differentiated from AD by the pattern of cortical tau deposition. CTE preferentially affects perivascular parenchyma and cortical sulci, in a patchy distribution, which is demonstrated above^{2,5}. AD shows more diffuse distribution of p-Tau in the cortex (neurofibrillary tangles and glial cytoplasmic inclusions in astrocytes and oligodendrocytes) as well as amyloid beta accumulation (neuritic plaques).

Chronic traumatic encephalopathy (CTE) (CORRECT)

The histology above demonstrates the p-tau pathology of chronic traumatic encephalopathy (CTE). The diagnostic lesion of CTE is described by the current NINDS Consensus report as “p-tau aggregates in neurons, with or without thorn-shaped astrocytes, at the depths of a cortical sulcus around a small blood vessel, deep in the parenchyma, and not restricted to the subpial and superficial region of the sulcus”.¹ While similar to the diagnostic lesion described in the first NINDS Consensus report, this new definition requires the presence of neuronal p-tau specifically rather than neuronal or glial p-tau as previously stated².

The clinical and pathological features of this case are most consistent with a diagnosis of CTE. In addition to the description of the diagnostic lesion above, common gross findings include cortical atrophy, pallor of the SN and locus coeruleus (LC) , and septal abnormalities⁶⁻⁸.

D. Corticobasal degeneration (CBD) (INCORRECT)

CBD is a rare neurodegenerative disease characterized by 4 repeat (4R) tau deposition in various cell types and anatomical regions. It can present with Parkinsonian symptoms and cerebral cortical dysfunction. CBD often shows only focal cortical atrophy at autopsy. However, the hallmark finding of CBD is an astrocytic plaque, which is p-tau accumulation in the distal astrocyte processes and is not seen in CTE^{9,10}.

E. Progressive supranuclear palsy (PSP) (INCORRECT)

PSP is another 4R tauopathy that shares similarities with both CBD and CTE. Clinically, it is Parkinsonian disorder and presents with akinesia and rigidity, supranuclear gaze palsy, dysarthria, and dysphagia. Gross findings supportive of PSP include mild frontal atrophy, atrophy of the midbrain (particularly tectum), atrophy and gray discoloration of the subthalamic nucleus, and pallor of the SN. p-Tau pathology is most commonly seen in the brainstem and basal ganglia regions, and typically only affects the peri-Rolandic regions of the cortex. Histological hallmarks of PSP are globose neurofibrillary tangles (NFTs), tufted astrocytes (TAs), and neuropil threads. TAs are specific to PSP and are composed of proximal p-tau accumulation in astrocytes (as opposed to astrocytic plaques in CBD)^{10,11}.

References:

1. Bieniek, K. F. et al. The Second NINDS/NIBIB Consensus Meeting to Define Neuropathological Criteria for the Diagnosis of Chronic Traumatic Encephalopathy. *J. Neuropathol. Exp. Neurol.* 80, 210–219 (2021).
2. McKee, A. C. et al. The first NINDS/NIBIB consensus meeting to define neuropathological criteria for the diagnosis of chronic traumatic encephalopathy. *Acta Neuropathol. (Berl.)* 131, 75–86 (2016).
3. Dickson, D. W. et al. Neuropathological assessment of Parkinson's disease: refining the diagnostic criteria. *Lancet Neurol.* 8, 1150–1157 (2009).
4. Dugger, B. N., Tu, M., Murray, M. E. & Dickson, D. W. Disease specificity and pathologic progression of tau pathology in brainstem nuclei of Alzheimer's disease and progressive supranuclear palsy. *Neurosci. Lett.* 491, 122–126 (2011).
5. Lawlor, B. A., Ryan, T. M., Schmeidler, J., Mohs, R. C. & Davis, K. L. Clinical symptoms associated with age at onset in Alzheimer's disease. *Am. J. Psychiatry* (1994).
6. McKee, A. C. et al. The spectrum of disease in chronic traumatic encephalopathy. *Brain* 136, 43–64 (2013).
7. McKee, A. C., Stein, T. D., Kiernan, P. T. & Alvarez, V. E. The Neuropathology of Chronic Traumatic Encephalopathy. *Brain Pathol.* 25, 350–364 (2015).
8. Mez, J. et al. Assessing clinicopathological correlation in chronic traumatic encephalopathy: rationale and methods for the UNITE study. *Alzheimers Res. Ther.* 7, 62 (2015).
9. Armstrong, M. J. et al. Criteria for the diagnosis of corticobasal degeneration. *Neurology* 80, 496 (2013).
10. Dickson, D. W. Neuropathologic differentiation of progressive supranuclear palsy and corticobasal degeneration. *J. Neurol.* 246, 116–115 (1999).
11. Dickson, D. W., Rademakers, R. & Hutton, M. L. Progressive supranuclear palsy: pathology and genetics. *Brain Pathol. Zurich Switz.* 17, 74–82 (2007).