



Case #8

NAME Educational Activities Committee

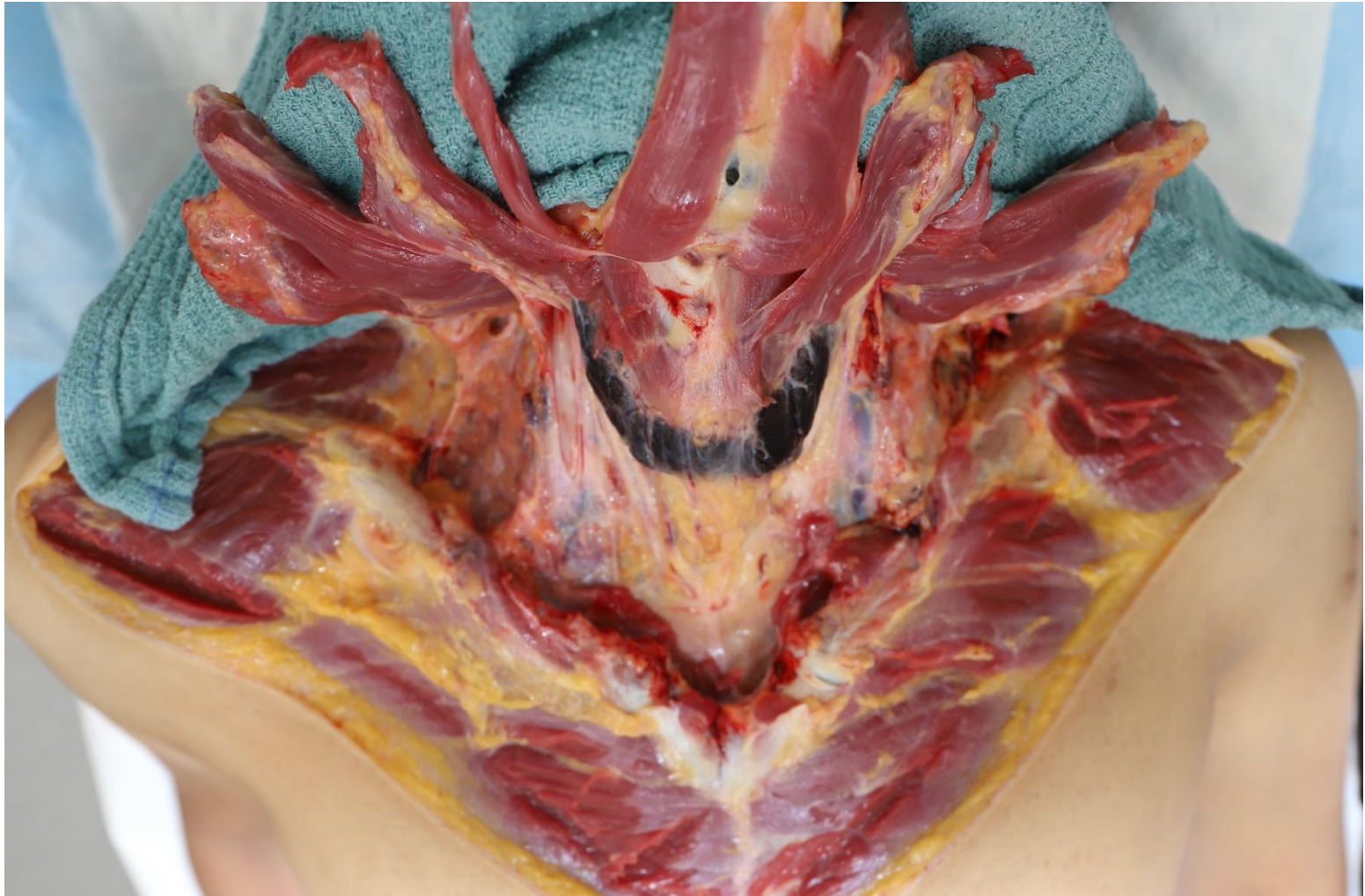

Photo courtesy of Abraham Philip, MD (Cobb County ME Office)

1. The decedent was found at home, partially suspended by a ligature around his neck. The image is of the anterior neck dissection. What is the underlying cause of this finding?

- Medication side effect
- Fracture of the thyroid cartilage
- Drying artifact
- Coagulopathy
- Natural variation

A. Medication side effect (Correct answer, 70.82% responses)

Thyroid pigmentation (black thyroid) is a well-recognized adverse effect of minocycline or other tetracycline therapy, which is generally used to treat many different types of bacterial infection, including acne. The mechanism appears to be related to interactions of minocycline with thyroid peroxidase (TPO), the key enzyme in thyroid hormone synthesis. Various body sites, most notably the skin, nails, bones, thyroid, mouth and eyes can be affected by minocycline-induced pigmentation. In general, pigmentation results from long term administration of minocycline at cumulative doses greater than 100 g, although cutaneous or oral mucosal pigmentation may appear, regardless of dose or duration of therapy. Ocular, thyroid and visceral pigmentation is relatively uncommon, with thyroid pigmentation reported in only about 150 cases in the literature, and usually develop only with high doses and long term minocycline use. Although pigmentation of the skin and oral mucosa is generally reversible when the drug is discontinued, the pigmentation is often permanent when other sites are involved.

B. Fracture of the thyroid cartilage (16.07% responses)

A fracture of the thyroid cartilage would be unexpected without hemorrhage of the strap muscles of the neck and usually requires complete suspension. Additionally, in cases of blunt force injury to the neck (such as hanging, in this case) the thyroid cartilage is most likely to fracture at the superior horn. Finally, thyroid cartilage fracture may show some focal or patchy hemorrhage, but this level of discoloration would be unexpected.

C. Drying artifact (2.3% responses)

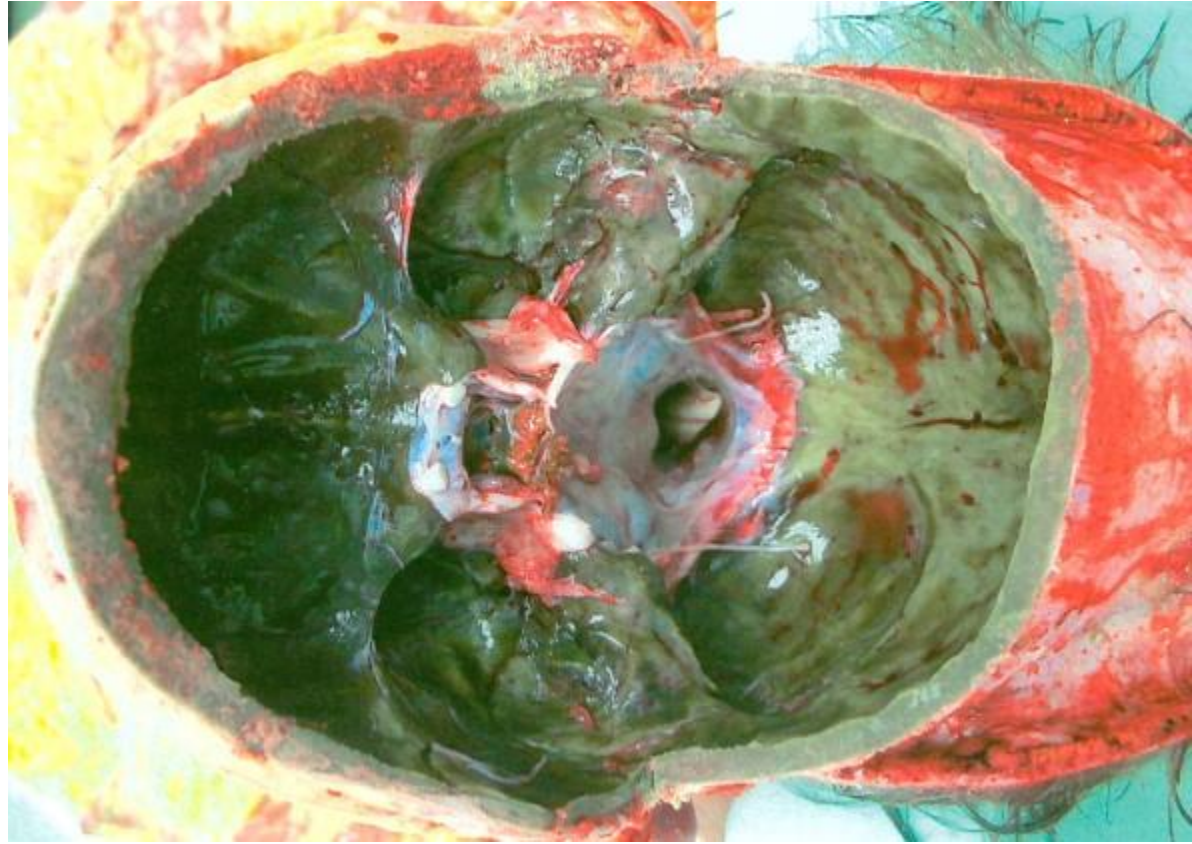
Drying artifacts associated with hanging cases are often superficial, limited to the epidermis and dermis. In these cases, the skin may become discolored dark brown and appear leathery. Tache noir may be seen in the eyes.

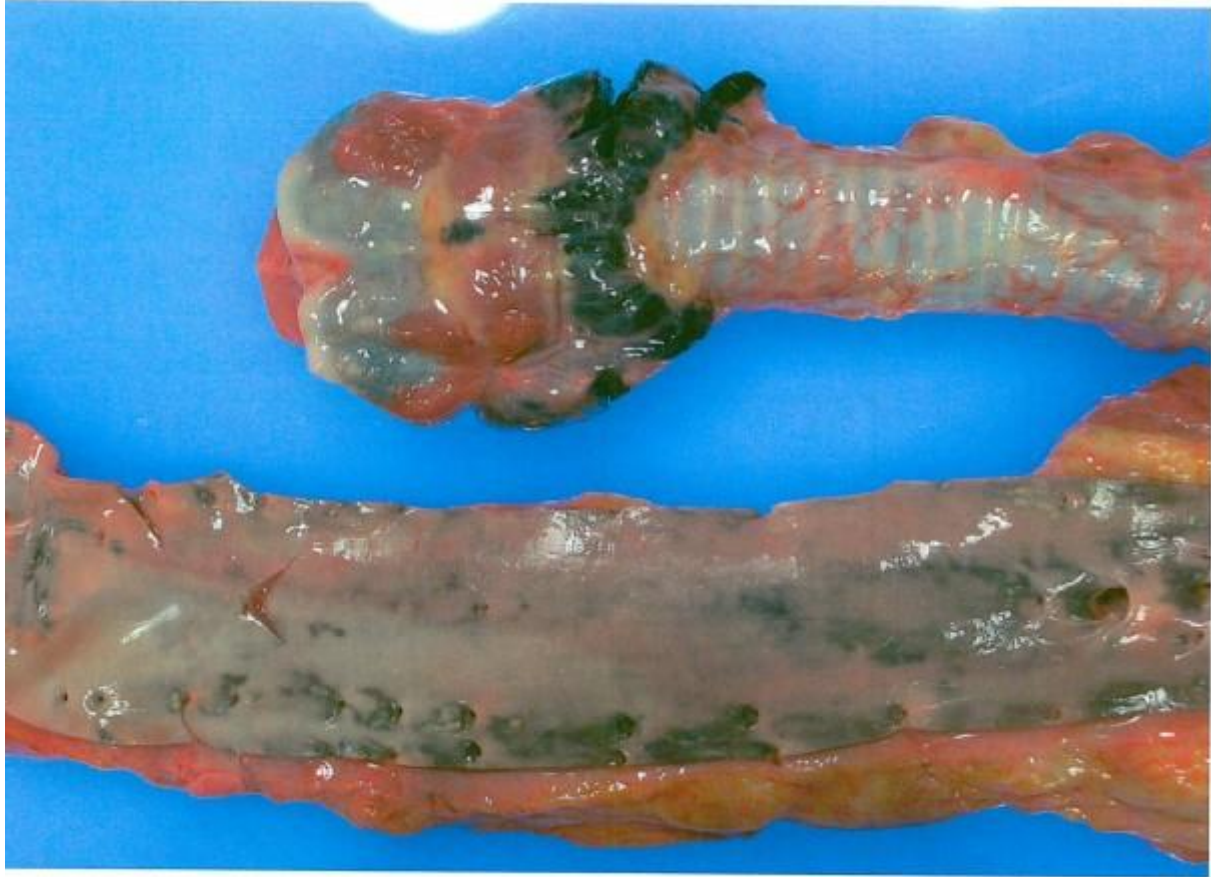D. Coagulopathy (6.23% responses)

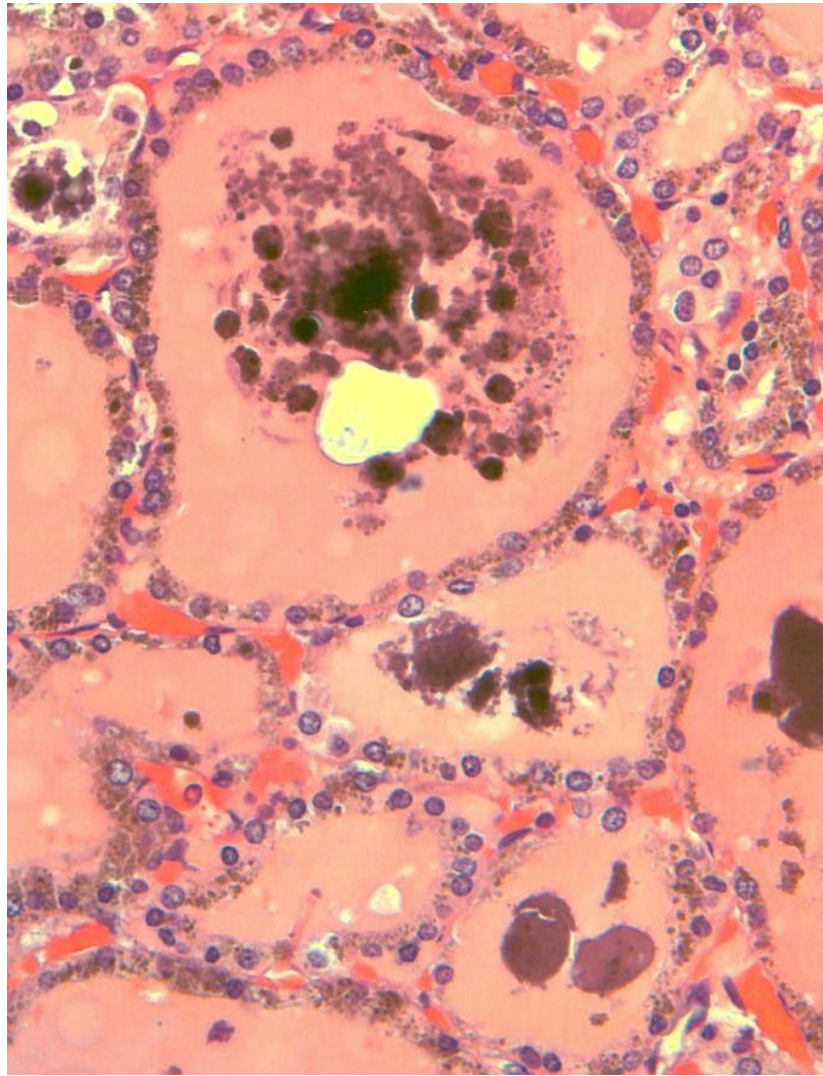
The red-black discoloration is limited to the thyroid and is well circumscribed. A coagulation disorder would likely result in focal or patchy hemorrhage of the strap muscles of the neck. Disorders of primary hemostasis, platelet dysfunction or platelet deficiency, are characterized by mucosal hemorrhage and petechiae. Disorders of secondary hemostasis are associated with deep tissue bleeds (hemarthrosis, hematomas), large ecchymosis, and intracavitary bleeding.

E. Natural variation (4.59% responses)

Most healthy thyroid tissue is described as beefy red or deep red. Black discoloration falls outside the spectrum of normal.







References

<https://link.springer.com/article/10.1007/s00414-020-02382-1/tables/1>

<https://www.ncbi.nlm.nih.gov/pmc/articles/PMC4345646/>

<https://link.springer.com/article/10.2165%2F00002018-199818060-00004> <https://pubmed.ncbi.nlm.nih.gov/9638388/>