



Case #7

NAME Educational Activities Committee

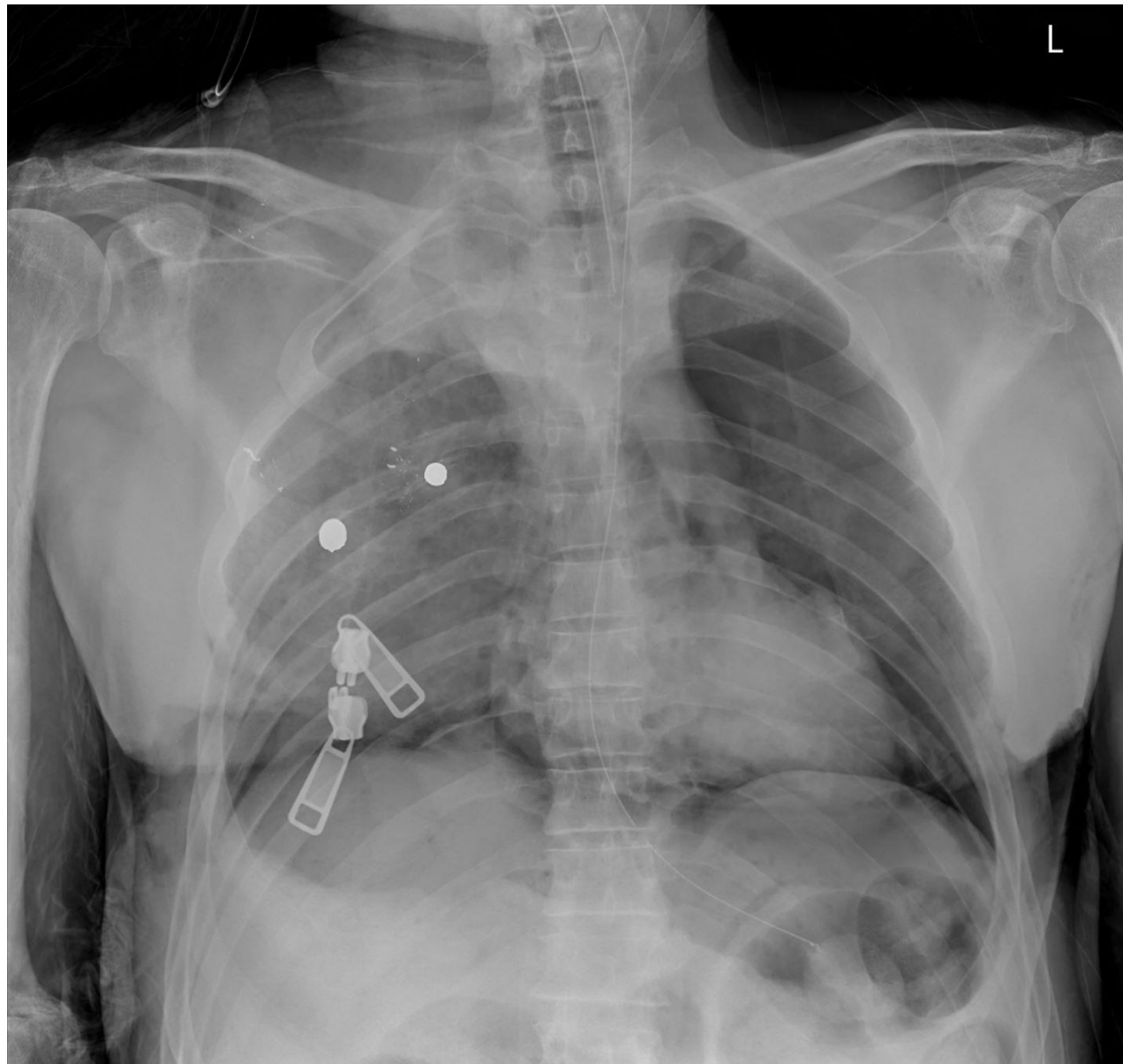


Photo courtesy of Jay Stahl-Herz, MD

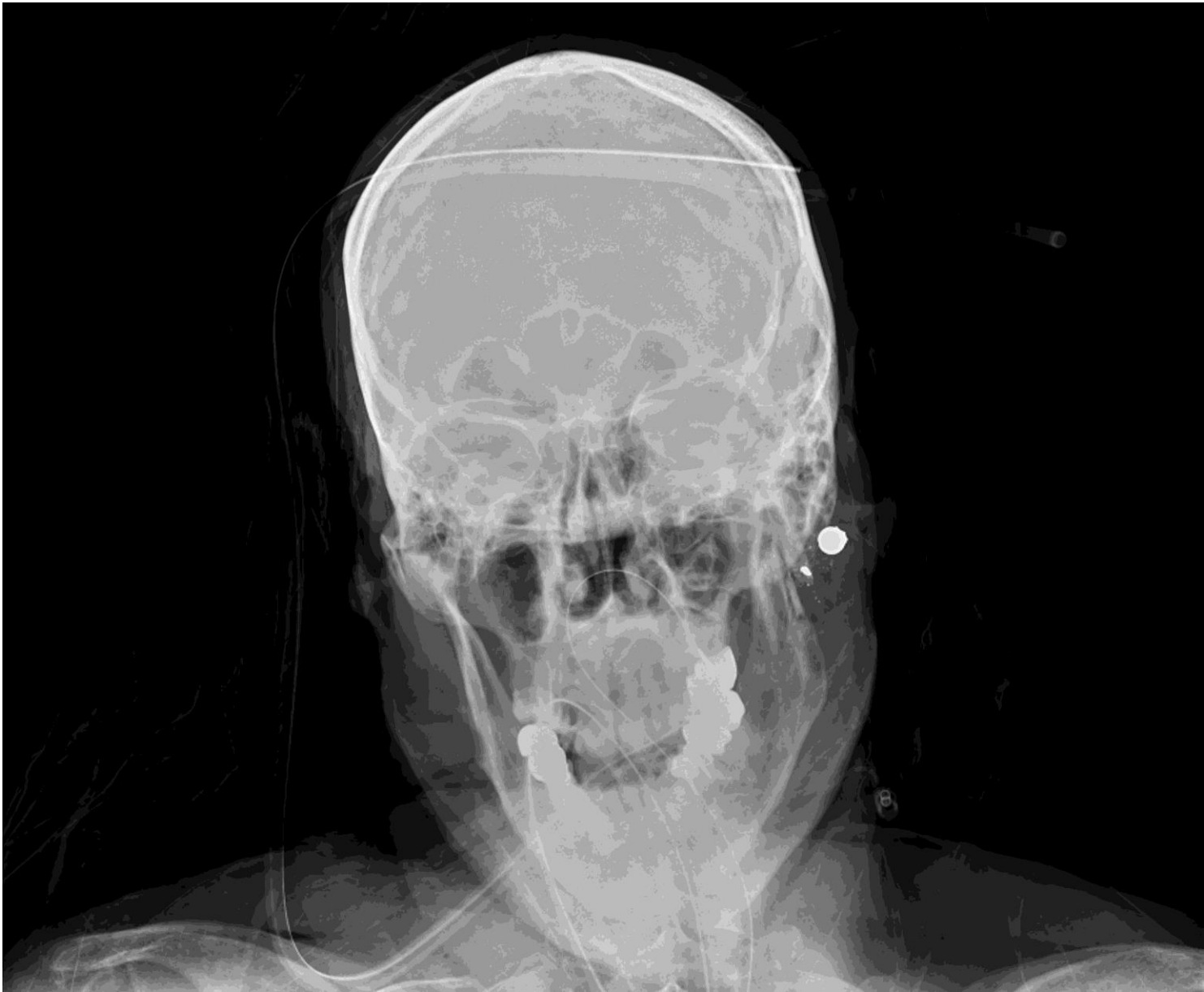

Photo courtesy of Jay Stahl-Herz, MD

1. Two men get into an altercation. One of the men produced a firearm and, according to witnesses, fired it once before fleeing the scene. The decedent fell to the ground and was subsequently taken to an ER where resuscitation efforts included a "clam-shell" thoracotomy. Postmortem x-rays are seen above. What explains the x-ray findings? (Comment - the zippers can be ignored and are from the body bag).

- Tandem bullets
- Sabot ammunition
- Shotgun ammunition
- Intermediate target
- Frangible ammunition



Flare gun

A. Tandem bullets (21.91% responses)

Tandem bullets occur when a bullet is lodged in a barrel and the gun is fired a second time. Both bullets may strike the person after the second discharge. There may only be a single entrance wound.

B. Sabot ammunition (7.1% responses)

Sabot ammunition is a type of rifle ammunition where a bullet is enclosed in a plastic sheath. The sheath typically falls off the rifle bullet after the projectile leaves the rifle barrel. The plastic sheath expands after leaving the barrel and may cause petal marks at the entrance wound if it strikes the body. The sabot would likely be radiolucent on x-rays.

C. Shotgun ammunition (Correct answer, 48.77% responses)

The x-rays show three distinct somewhat rounded retained projectiles. A .410 buckshot shot shell contains four 000 buckshot pellets. Three of the four pellets struck the decedent in this case. In addition to a modified flare gun, there are handguns capable of firing .410 shot shells. These include the Taurus Judge, Smith and Wesson Governor, MIL Thunder 5 and the Bond Arms Derringer.

D. Intermediate target (7.72% responses)

Intermediate targets may cause a projectile to fragment. The projectiles in these x-rays are round and similar in size. The decedent may subsequently be struck by multiple projectile fragments and other debris which may or may not be radiolucent depending on the type of intermediary targets. The entrance wounds usually appear atypical in nature.

E. Frangible ammunition (14.51% responses)

Frangible ammunition is designed to break apart upon impacting hard surfaces. This design prevents over-penetration and ricochets. There would be a single typical entrance wound with fragmentation of the projectile after entering the body. In classic frangible ammunition, the radiographic appearance on a postmortem x-ray could be more consistent with a "lead snowstorm" and usually would not appear as distinct retained projectiles. In other types such as RIP ammunition (see EAC question #2), the x-ray would show a base and multiple trocars.

Reference: DiMaio, Vincent "Gunshot Wounds" 3rd Edition, CRC Press, 2016