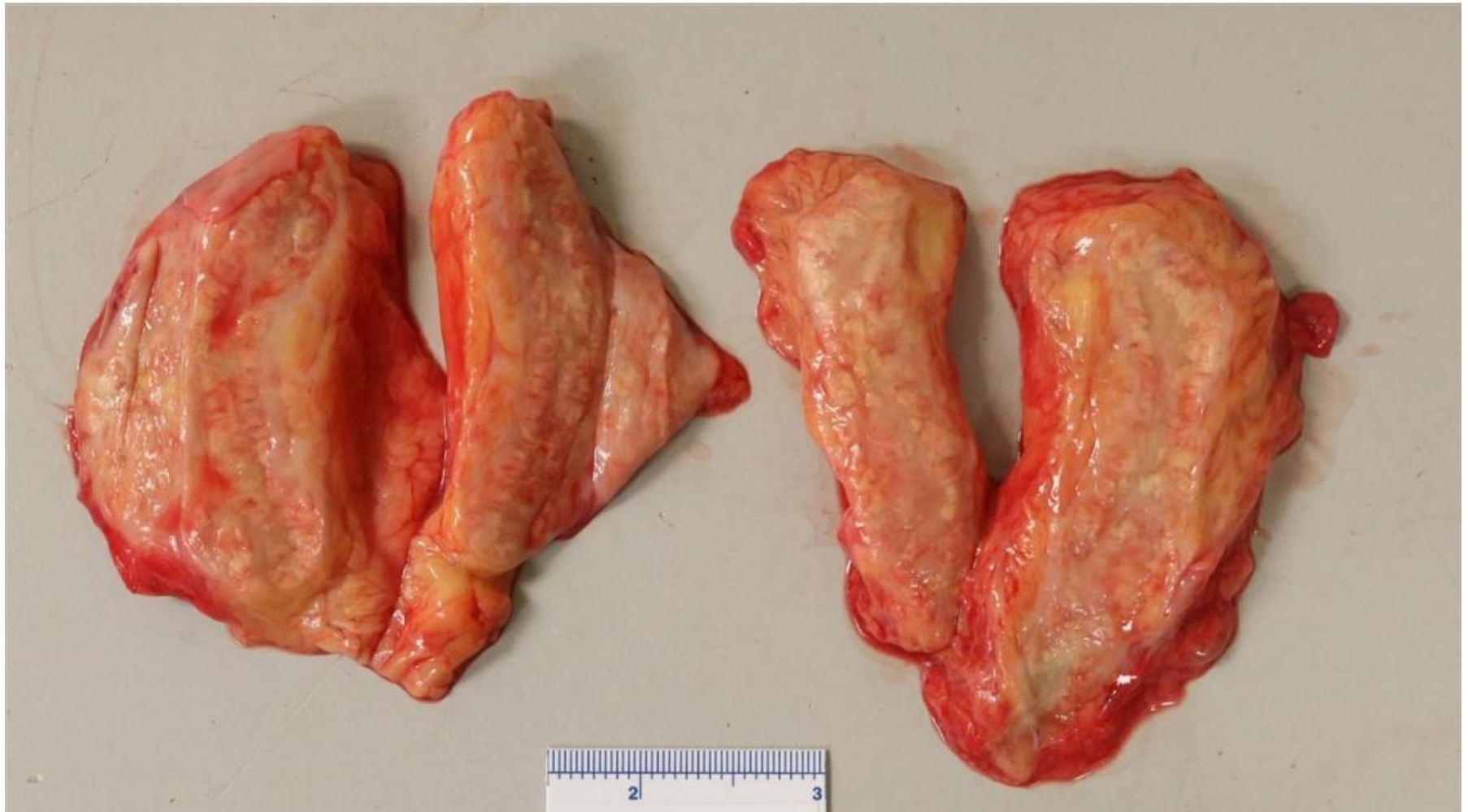

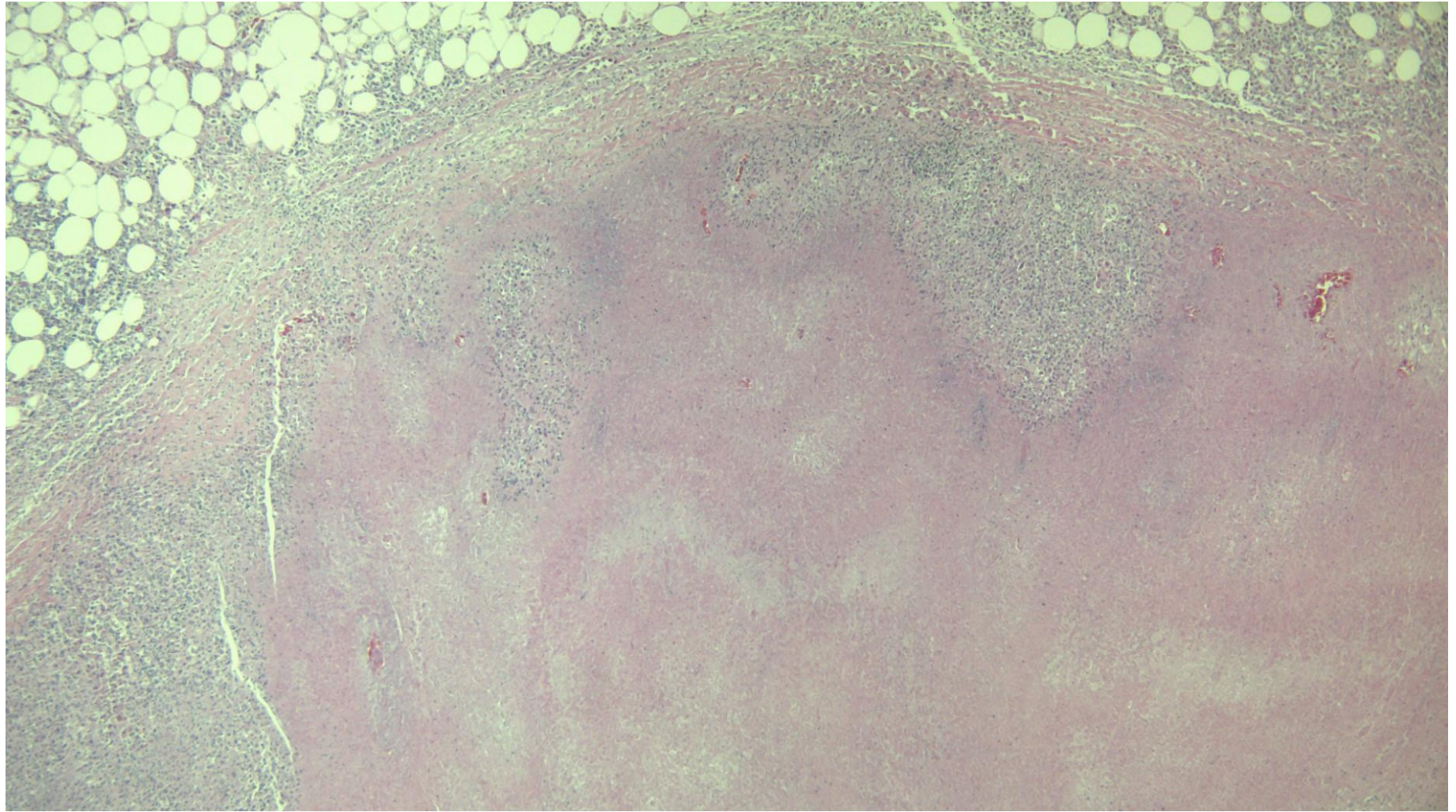


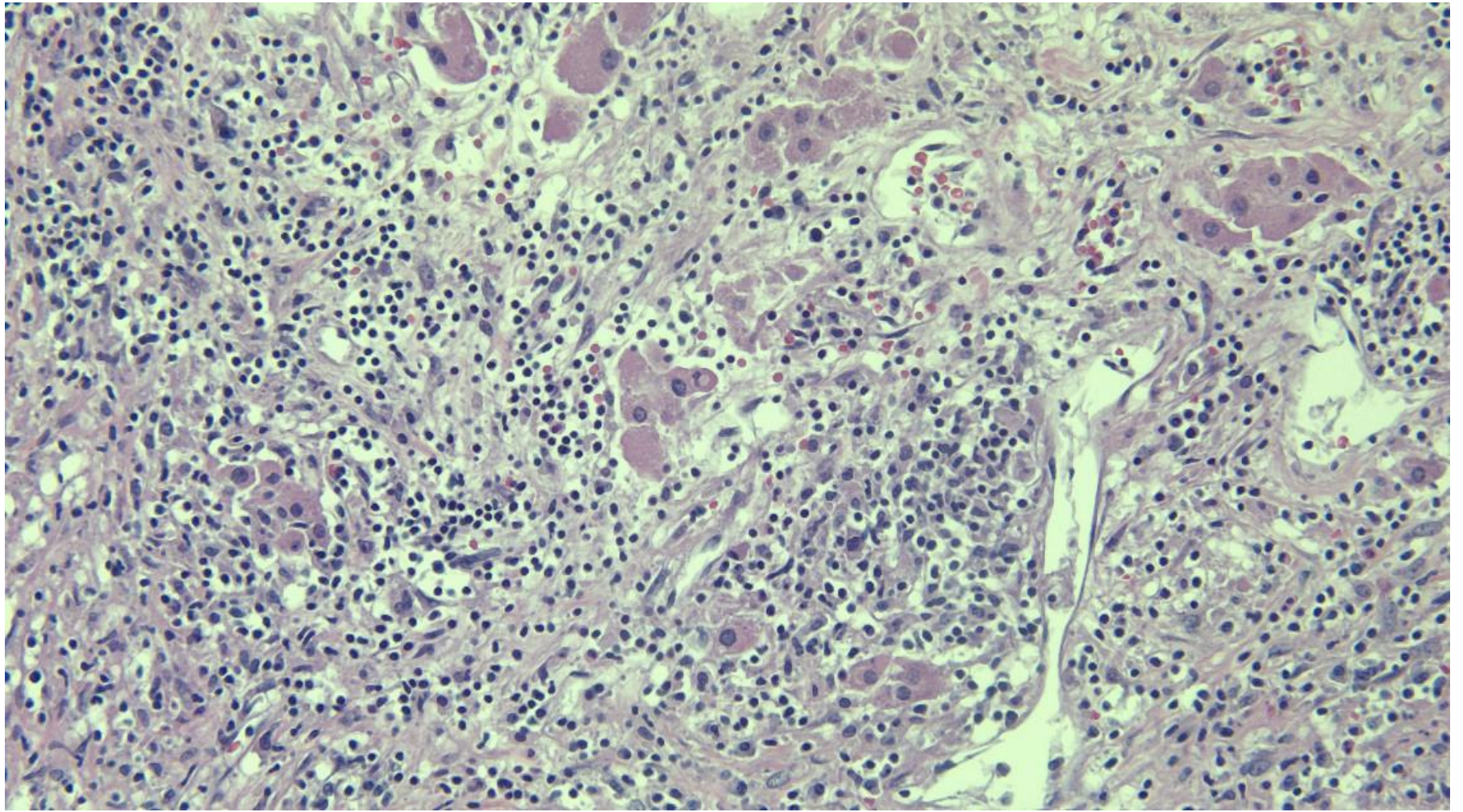
Case #22

NAME Educational Activities Committee



Case courtesy of Dr. Ross Zumwalt (Office of the Medical Investigator, University of New Mexico)





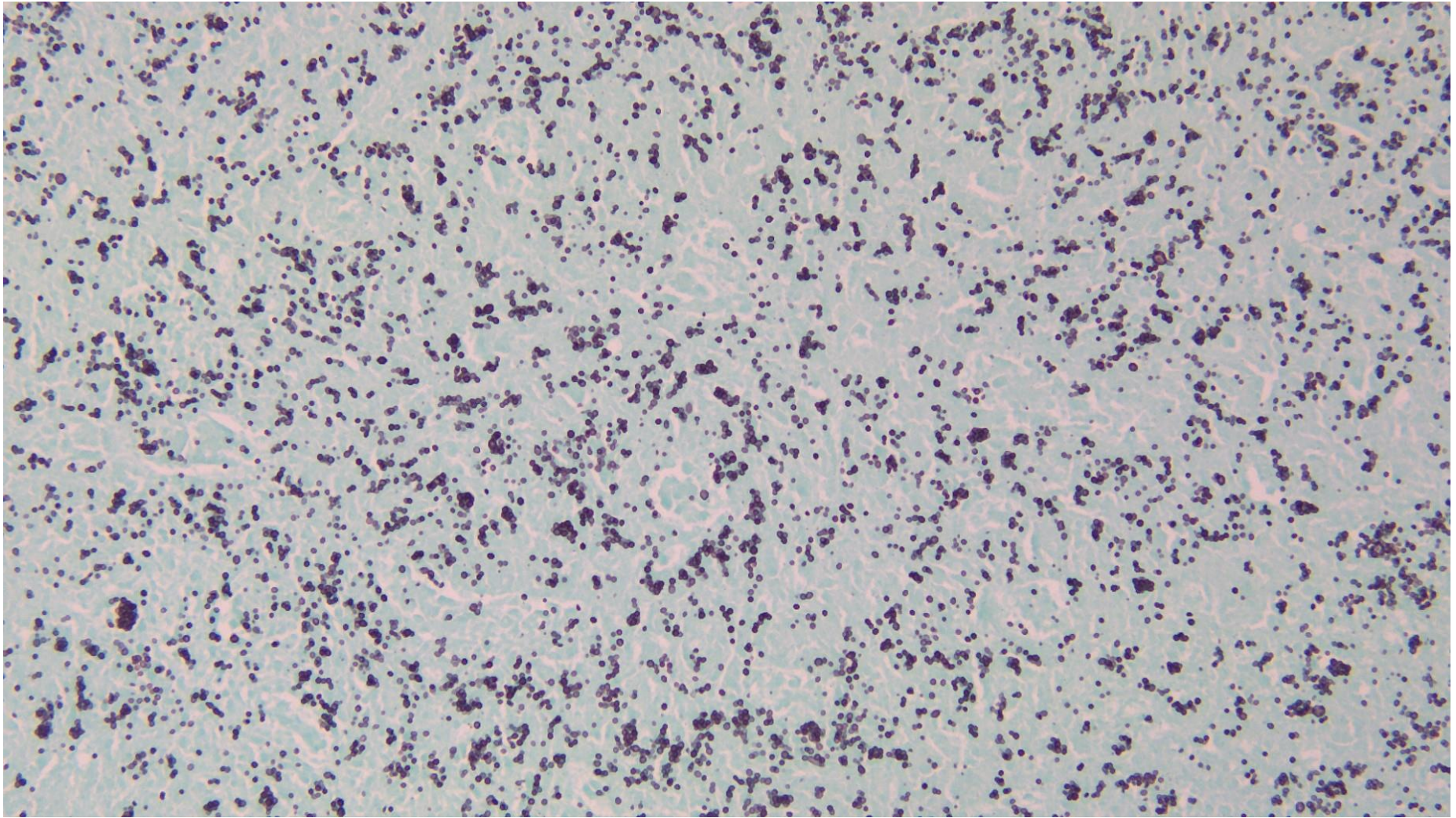
1. A 58-year-old woman collapsed suddenly in her kitchen. Paramedics arrived and found no signs of life and she was pronounced at the scene. According to her husband she had not been well for 3 or 4 days. She had nausea and vomiting and possibly had a low grade fever.

Her past medical history included hypertension, hypothyroidism and Crohn's disease. Seven years prior to her death she had a 15 cm distal ileal resection because of blockage from her Crohn's disease. Five years prior to death she had surgical removal of a microinvasive ductal carcinoma (Stage 1A) of her left breast followed by radiation but no chemotherapy. Her medications included amitriptyline (Elavil), adalimumab (Humira), thyroxin, and amlodipine.

The autopsy revealed cardiomegaly, moderate coronary artery stenosis, emphysema and bilaterally enlarged adrenal glands. The adrenals were firm and weighed 85 grams together. The cut section was tan with areas of yellow necrosis. Other organs appeared grossly and microscopically normal for age. There were two small calcified granulomas in the left lung and no evidence of active Crohn's disease in the small or large bowel.

The adrenal abnormality is due to:

- Metastatic sclerosing ductal carcinoma of the breast
- Schmidt syndrome (autoimmune polyendocrine syndrome, type 2)
- Tuberculosis
- Histoplasmosis
- Post COVID-19 autoimmune adrenal necrosis



GMS stain

Responses:

A. Metastatic sclerosing ductal carcinoma of the breast (15.79% of responses)

There was no evidence of metastatic disease. The microscopic sections showed fibrosis and necrosis of the adrenal glands with a few residual cortical adrenal cells. It would be unusual to have isolated bilateral adrenal metastases with no evidence of other metastatic disease.

B. Schmidt syndrome (47.72% of responses)

Autoimmune polyendocrine syndrome, type 2 (Schmidt syndrome) results in small and atrophic adrenal glands. Microscopically there is loss of cortical glands with fibrosis and a lymphocytic infiltrate. While a lymphocytic infiltrate can be appreciated in the high-power image, there is also extensive necrosis. Furthermore, the adrenal glands in this case were enlarged and not atrophic.

C. Tuberculosis (11.58% of responses)

Tuberculosis is a good consideration but the microscopic appearance is not typical for tuberculosis. Giant cells are a feature of tuberculosis but are not present in this case. Nonetheless, an acid fast stain was done and there were no acid fast bacilli.

D. Histoplasmosis (CORRECT ANSWER, 13.33% of responses)

Histoplasmosis capsulati is a fungus found in soil, especially in soil containing the excrement of birds. Histoplasmosis is a common visceral infection in the U.S. acquired by inhalation resulting in granulomatous inflammation in the lung. The infection is often asymptomatic resulting in one or more calcified pulmonary nodules. In some individuals the infection can become disseminated and the adrenals are a common target when this happens. Staining of the adrenal sections with Gomori's methenamine-silver (GMS) demonstrated the large number of yeast forms. With bilateral adrenal destruction, Addison's disease may occur. Isolated spread to the adrenal glands has been reported. Individuals on Humira, an immunosuppressant, are vulnerable to infections and recurrence of dormant fungal infections such as tuberculosis or histoplasmosis. It is not completely clear in this case whether the longstanding Humira therapy was instrumental in the degree of adrenal involvement in this case. It is also unknown in this case whether there was sufficient adrenal insufficiency to result in Addison's disease. There were isolated pockets of residual adrenal cortical cells identified on microscopic evaluation. Addison's disease usually does not present clinically until more than 90% of the adrenal cortex is destroyed. However, the postmortem vitreous humor analysis revealed hyponatremia and borderline hypochloremia, a feature of Addison's disease. Nausea and vomiting are also often associated with Addison's disease. Hyperkalemia, which would predispose to a cardiac arrhythmia, is also seen with Addison's disease. In summary the death in this case was most likely a cardiac arrhythmia. The underlying causes were coronary artery disease, chronic obstructive lung disease, longstanding hypertension and probably a contribution of Addison's disease.

E. Post COVID-19 autoimmune adrenal necrosis (11.58% responses)

This is something Dr. Zumwalt made up, but it sure sounds legitimate! Although COVID-19 infection can result in long term adverse conditions, adrenal necrosis has not been described thus far. In this case a postmortem nasal swab for COVID-19 was negative.

References:

1. Vyes S, Kalra N, Das RJ, Raduika S, Bhansail A, Khaudelwal N. Adrenal histoplasmosis: An unusual Cause of Adrenomegaly. Indian J Nephrol. 2011 21 (4) p 283-85.
2. Chandler FW, Watts JC. Histoplasmosis Capsulati, Chapter 109 in Pathology of Infectious Diseases, Conner DH editor, Appleton & Lange, Stamford , Connecticut, 1997.