

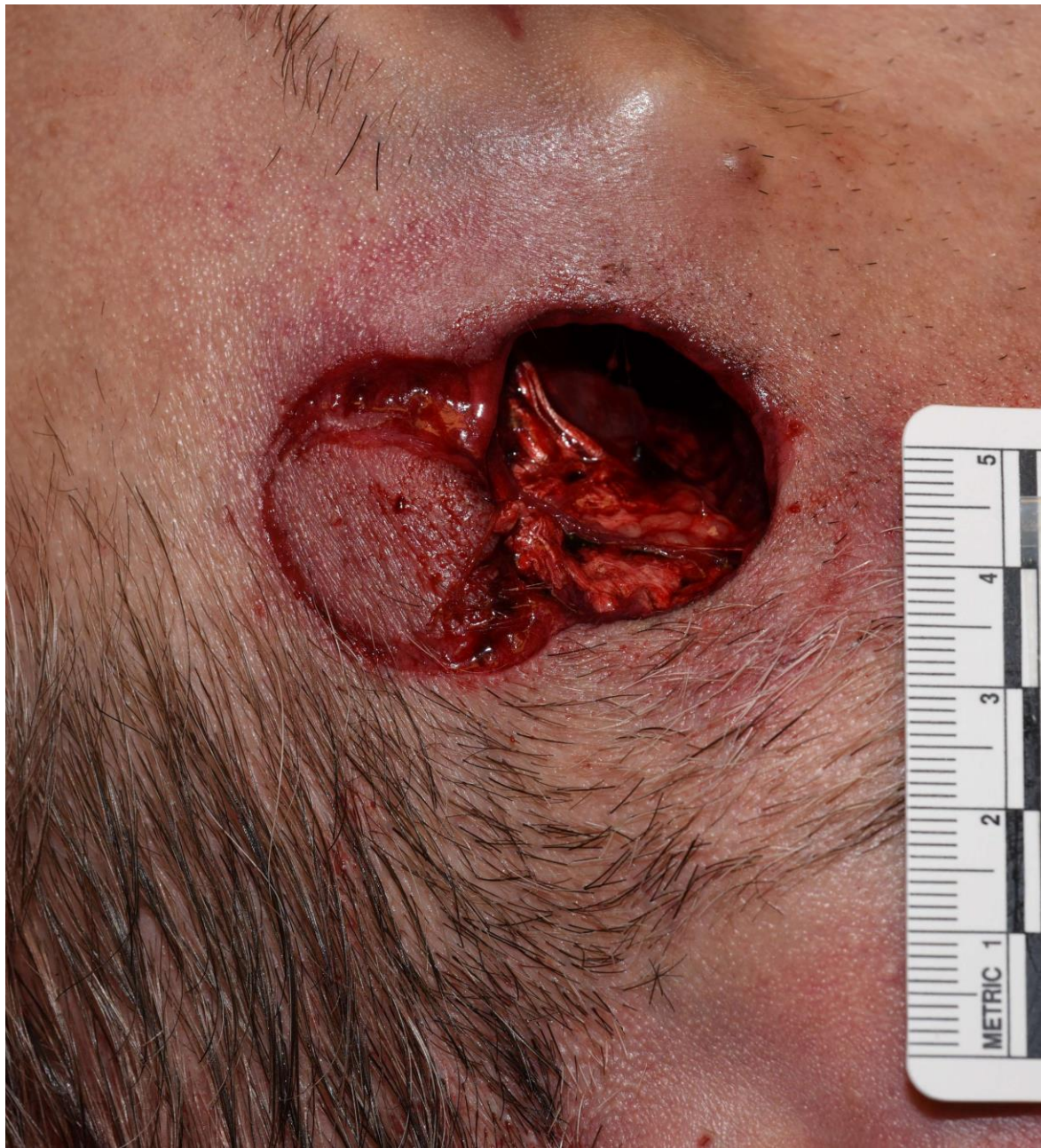

Case #40

NAME Educational Activities Committee

Case provided by:

Dr. Arpan Samaddar (PGY1) & Dr. Reade Quinton
Mayo Clinic, Rochester, MN

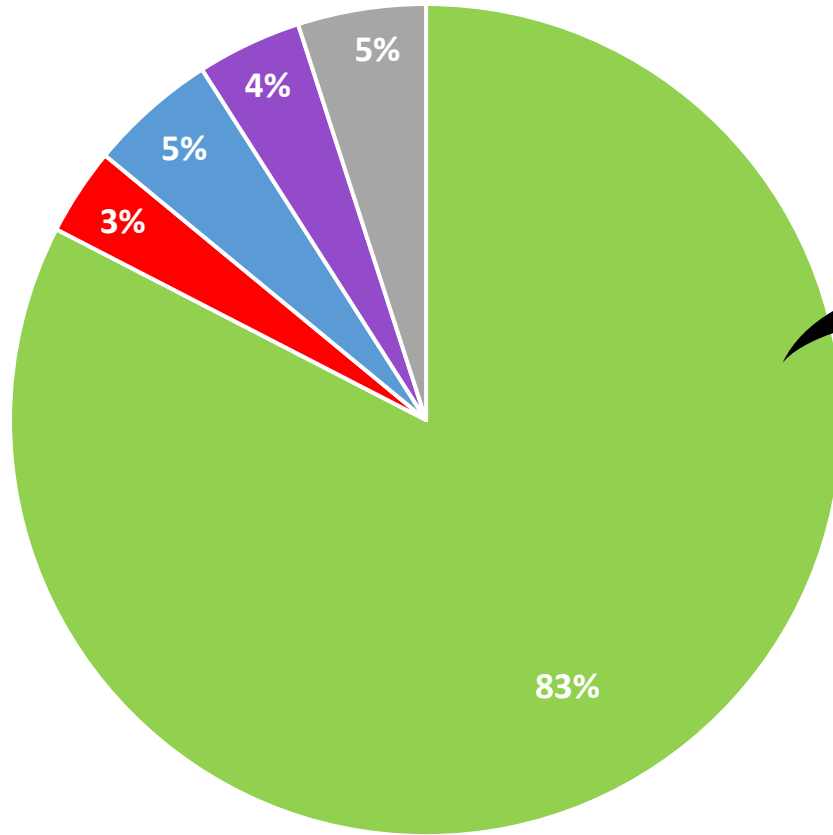


1. This adult male was found unresponsive in his unsecured residence. What is the most likely cause of this defect of the head? (FREE TEXT ANSWER)

Word Cloud

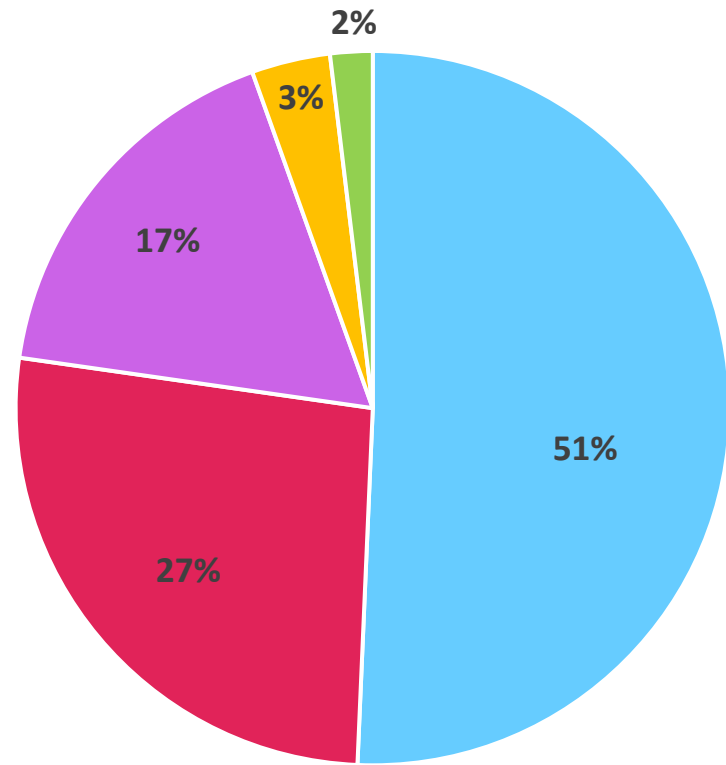
double-barreled^{right} one^{used} Blunt force trauma^{possibly}
entrance wound^{due} fired^{one barrel} shot gun^{side side}
Gun shot^{hole} entry^{Over-under} muzzle imprint
captive bolt gun head^{weapon} wound^{Captive bolt} Hammer
Close range Contact gunshot wound
shotgun wound head shotgun wound^{thought}
Double barrel^{muzzle} Contact^{derringer}
double barrel shotgun^{handgun}
Gunshot wound^{double} GSW^{one barrel fired}
shotgun^{hard contact} gun^{SGW} contact GSW^{shot}
firearm^{double-barrel shotgun} Gunshot^{defect} entrance
Self inflicted injury^{barrel fired} barrel shotgun wound^{temple}
bullet^{tube} gunshot wound head^{sharp} Contact range^{trauma}
Close contact^{Perhaps} Contact gunshot

Answers by Category



- Firearm
- Hammer
- Other
- Captive Bolt Gun
- Blunt force with hollow object

Firearm Subcategories




- Not Specified
- Shotgun Injury
- Keyhole Defect
- Double Barrel Shotgun
- Derringer Handgun

Answer...

Double Barrel Shotgun

Live Round



Barrel Selector

Fired Round

Derringer Handgun



Captive Bolt Gun

